

## Metalic foreign body in the liver of cow: a case report

H.Kh. Ismail and O.A. Abdullah

Department of Pathology and Poultry Disease, Collage of Veterinary Medicine, University of Mosul, Mosul, Iraq  
Email: hkhismail@yahoo.com

(Received April 7, 2014; Accepted April 24, 2014)

### Abstract

On necropsy of a two years old clinically healthy cow admitted to Mosul abattoir at postmortem inspection slaughtering establishment a metalic foreign body (as a piece of wire) was identified in the region of the liver. Gross examination revealed multiple abscess involving the liver, as well a large area of necrosis around foreign body penetration. Microscopically Suppurative inflammation in addition to foreign body granulomatous reaction.

**Keywords:** Foreign Body; liver; Cow

Available online at <http://www.vetmedmosul.org/ijvs>

### جسم معدني غريب في كبد بقرة: تقرير حالة

هناء خليل اسماعيل و عمر انمار عبدالله

فرع علم الأمراض وأمراض الدواجن، كلية الطب البيطري، جامعة الموصل، الموصل، العراق

### الخلاصة

تم الكشف على بقرة سليمة سريريًا بعمر سنتين بعد جزرها في مجزرة الموصل، تبين أثناء معاينة الذبيحة وجود جسم معدني غريب (قطعة صغيرة من سلك معدني) كانت قد اخترقت الكبد واستقرت فيه، وسببت حدوث تغيرات عيانية تمثلت بوجود عدة خراجات على الكبد بالإضافة إلى وجود مناطق نخريه حول منطقة اختراق الجسم الغريب، وظهرت نتائج الفحص المجهرى التهاب قيحي للكبد بالإضافة إلى التفاعلات الورمية الحبيبية الناتجة عن الجسم الغريب.

### Introduction

Cattle are more likely to ingest foreign bodies than small ruminants since they do not use their lips for prehension and more likely to eat a chopped feed. Atypical foreign body is metalic object such as apiece of wire or nail (1). The prevalence of traumatic reticulitis in adult dairy cattle, has been attributed to management practices and lack of discriminatory dietary habits of cattle (2).

Occasionally the foreign body may pierce and infect the liver and spleen (3,4).

This case report present rare case in which metalic foreign body was embedded in the liver asymptotically and found incidentally during necropsy of meat inspection.

### Pathological finding

#### Macroscopically

On necropsy of clinically healthy cow a metalic wire was found penetrating in and out the reticulum. Most perforation occur medially in the direction towards the liver (Fig. 1 and Fig. 2). A morphological changes of the liver revealed to hardening and Palness of hepatic tissue surrounding the penetrating area of foreign body. As well presence of small multiple abscess were seen in the liver. A creamy offensive pus seen in the center of these abscess (Fig. 3).

#### Microscopically

Foreign body granuloma was recognized by identifying the necrotic center, infiltrated by macrophages plasma cells, lymphocytes, epitheloid cells, and foreign body giant cell

(Fig. 4), additionally there were hepatic abscess which characterized by liquifactive necrosis infiltrated by inflammatory cells (neutrophils, macrophages, and lymphocytes surrounded by fibrous capsule (Fig. 5), (Fig. 6).

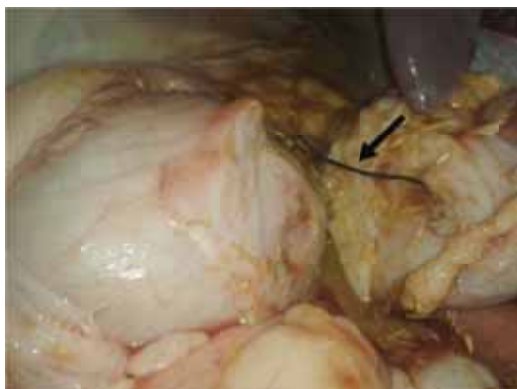

Fig. 1: Ingested wire perforated the wall of reticulum (↗) and most perforation medially towards the Liver.

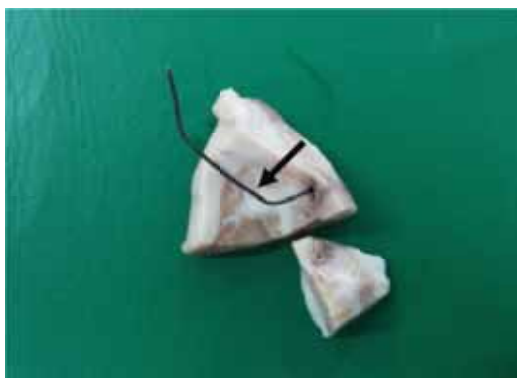

Fig. 2: The ingested wire perforated the Liver.

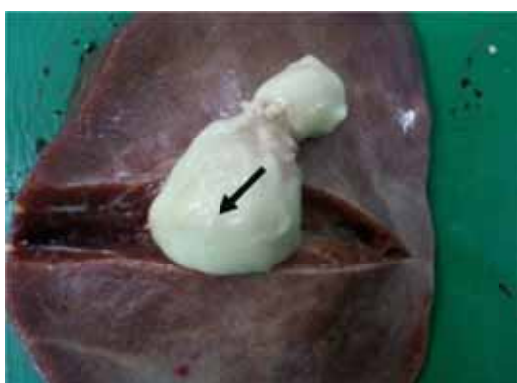


Fig. 3: Hepatic abscess, note the thick white caseous exudates (Creamy pus).

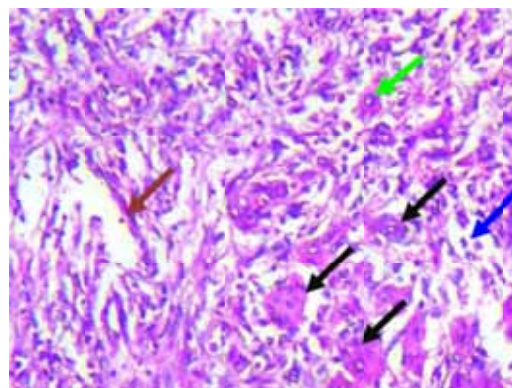


Fig. 4: Foreign body granuloma, note the granulomatus inflammatory exudates contains multinucleated giant cells (↖) and mononuclear inflammatory cells (Macrophages ↗, Lymphocytes ↘, Plasma cells ↙ and epithelioid cells), (H&E 450 X).

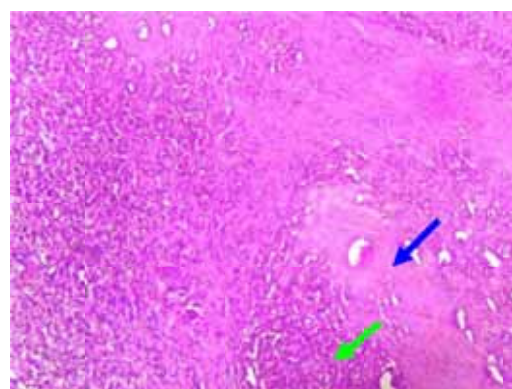


Fig. 5: Hepatic abscess note the liquifactive necrosis infiltrated with inflammatory cells (↖) surrounding by fibrous capsule (↗), (H&E 165X).

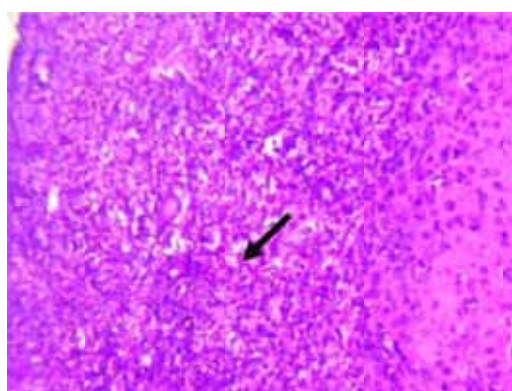


Fig. 6: At higher magnification of the upper Fig Hepatic abscess consist of an infiltrate of neutrophils and necrotic tissue debris (H&E 370X).

## **Discussion**

This case report describe an unusual position and penetration of metallic wire embedded in the liver which found incidentally during post mortem inspection at slaughtering establishment. This report showed granulomatous reaction this is the most common complication of traumatic injury caused by foreign body (3). Penetration of foreign body soft tissue followed by acute inflammation and formation of granuloma. Granuloma is a non specific type of inflammatory responses which may be triggered by diverse antigenic triggering agent cause activation of the cellular immune system (T lymphocytes and macrophages) so granulaomas formed as a result of the complex interaction of cytokines produced by these cells. (5). This result agreed with the result stated by (6-10). While liver abscesses may caused by traumatic reticulo peritonitis due to direct trauma by foreign body or as consequence of extension of lesions of peritonitis (11). Also liver abscess seen as a result of invasion of pus producing bacteria which usually accompany foreign body injuries, This result also reported by (12,13).

## **References**

1. Rebhun WC. Disease of Dairy cattle. 1<sup>st</sup> Edu. Philadelphia: Williams and Wilkins; 1995. 113-116 p.
2. Hajhramain Sh, Ghane M. Traumatic reticuloperitonitis in cattle of Khorramabad.(Center of Lorestan Provence, west of Iran). *Global Veterinaria*. 2010;5(2):135-139.
3. Orpin P, Harwood D. Clinical management of traumatic reticuloperitonitis in cattle in *Practice*. 2008; 30:544-551.
4. Radostits OM, Gay CC, Hinchcliff KW. and Constable. *Veterinary Medicine. A Textbook of the Diseases of Cattle, Horses, Sheep, Pigs and Goats*. 10th ed. Philadelphia: Saunders Elsevier. 2007;pp: 337–344
5. Barker Jk, Van Dreumel AA. The alimentary system; foreign bodies in the fore stomachs. In: Jubb KFV, Kennedy PC, Plamer N, editors. *Pathology of domestic animals*. 3<sup>rd</sup> ed. Vol 2. New York: Academic Press, 1985;p:32-33.
6. Roth L, King JM. Traumatic reticulitis in cattle a review of fatal cases. *J Vet Diag Invest*. 199;3:52-54.
7. Sojka JE, White MR, Widmer WR, VanAlstine WG. An unusual case of traumatic pericarditis in a cow. *J Vet Diagn Invest*. 1990;2(2):139-142.
8. Ghanem MM. Comparative study on traumatic reticulo peritonitis and traumatic pericarditis in Egyptian cattle. *Turk J Vet*. 2010;34(2):143-153.
9. Monies B. Alimentary tract perforation in cattle caused by tier wire. *Vet Rec*; 2004: 154-735.
10. Hayley G. Traumatic reticuloperitonitis in cows. *Vet Rec*. 2007: 166-882.
11. Karadamir B, Atalan G. The prevalence of traumatic reticuloperitonitis in cattle of Kars province. *J Turk Vet Surg*. 2003;9:26-28.
12. Dore E, Fecteau G, Hlie P, Francoz D. Liver abscesses in Holstein dairy cattle 18 cases (1992-2003). *J Vet Intern Med*. 2007;21:853-856.
13. Santos SA, Alberto SC, Cruz E, Pires E, Figueira T, Coimbra E, Estevez J, Oliveira M, Novais L, Deus JR. Hepatic abscess induced by foreign body: case report and literature review. *World J Gastro*.2007;13(9):1466–1470.