

A survey of some ovarian abnormalities responsible for sterility in Damascus goats

M. Roukbi

General Authority for Scientific Agricultural Research, Damascus, Syria
roukbi2008@yahoo.com

(Received December 12, 2013; Accepted May 7, 2013)

Abstract

A survey of some ovarian abnormalities in 13 Damascus goats with normal to masculinized genitalia, aged 1.5 to 6 years is made up in the purpose to determine some types of disorders affecting the ovaries in light of their morphological findings referenced in obstetrics and gynecology literatures. The results showed persistent follicles and cystic ovarian disease in phenotypically females, epidermal neoplasms, gonads dysgenesis and dysgenetic gonad tumors in Shami goats polled intersex goats, similar to ovarian tumors in women.

Keywords: Shami goats, infertility, ovary, abnormalities.

Available online at <http://www.vetmedmosul.org/ijvs>

مسح لبعض اصابات المبيض المسببة للعقم في المعز الشامى

محمد ركبى

الهيئة العامة للبحوث العلمية الزراعية، دمشق، سوريا

الخلاصة

أجرى مسح لبعض اصابات المبيض في 13 من اناث المعز الشامى التي تراوحت اعمارها بين 1,5 - 6 سنوات لتحديد نوع المشاكل التي تصيب المبايض وتسليط الضوء على الصفات الشكلية المشار اليها في مراجع التوليد والامراض التناسلية. بينت النتائج ان بقاء الجريبات وتكيس المبايض في الحيوانات التي لها مظهر اناث، والاورام الظهارية، والخلل في تنسج القند، واورام القند في المعز الشامى التي لها مظهر خنثى تشابه اورام المبيض في النساء.

Introduction

Genital tract diseases significantly reduce flock productivity and may mean that rearing these animals is uneconomical.

The study of ovarian lesions in goats, especially in Shami goats breed has not been studied previously. Some systematic studies on genital diseases in slaughtered goats have been carried out (1,2). Very few have been taken implying a description of some gonads tumors in polled intersex goats and / or Freemartin (3-7).

This research aims to observe ovarian abnormalities in Shami goats breed in the purpose to establish proper diagnosis of ovarian abnormalities and this in light of their similar morphological findings.

Materials and methods

To perform this research macroscopically examination of 13 genital tracts of non-conceptive phenotypically female goats of 1.5 to 6 years of age were collected after slaughter has been performed in 2007 in Humeimeh research station for improvement of Shami goats /General Commission for Agricultural Scientific Research to observe ovarian abnormalities the purpose to establish proper diagnosis in light of their morphological findings referenced in obstetrics and gynecology literatures, among them (8,9), as well as ovarian tumors associated with the disorder of sex development or differentiation in the human (10-13), and to a number of research on gonad tumors in goats associated with Freemartin (cotwin born to male) or

XX / XY Chimerism (14) as well as the intersexuality linked with Hornless or polled character with XX karyotype (7), and other scientific reports (3,6,7,15). The goats with female phenotypically external genital organs were unresponsive to hormone therapy with FSH-LH releasing and prostaglandin derivatives hormones. Since no information were available about the phenotype for polled character, all intersex cases except tow cotwins cases born to male were considered as intersex or hermaphrodite polled related cases.

Results and Discussion

Clinical examination of 13 Damascus goats showed four have only small vulva in the normal position. The remainders eight have been showed intersex features including slight projection of the vulva and penile clitoris, but no masses could be palpated in the inguinal region.

Failure of follicular growth beyond emergence or persistent follicles and cystic ovarian disease in female phenotypically goats

Ovarian anovulatory condition or failure of follicular growth beyond emergence (Persistent follicles). In this (Figure 1) multiple follicles on the surface of the ovaries were noted and this could be related to hypothalamic insensitivity (16) causes a deficiency of follicle stimulating hormone (FSH) and an abnormal decrease or absence of the hormonal cascade that is necessary for the preovulatory luteinising hormone (LH). Or, low levels of Inhibin A, which is produced by granulosa- cell of healthy growing follicles, will be not able to suppress the secretion of FSH (17).

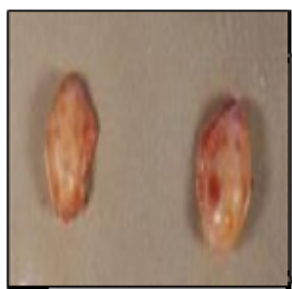

Figure 1: normal aspect of goat ovaries normal left ovary smaller than right one, follicular wave-like pattern.

As consequence a cystic ovary (Figure 2) at least or more measuring 2- 10 mm persisting 10 or more may develop (17) with nonexistent or frequent Heat cycles (6-14 days). The excessive or prolonged estrogenic stimulation

and eventually pituitary adenoma (18), cystic glandular or follicular endometrial hyperplasia (19) appears to be responsible for impermanent infertility by preventing implantation or fertilization (20). Also, since prostaglandin F2 α synthesis and release are inhibited in uterine infection (21), lead to retention and persistence of the corpora lutea and increased progesterone levels.




Figure 2: failure of follicular growth beyond emergence or Persistent follicles semi-natural ovaries with a large number of follicles on the surface of the left ovary.

The inadequate exposure of the progesterone may be also an associated factor for this total hormonal misbalance (22). Some animals have few primordial follicles in ovarian hypoplasia (underdevelopment or incomplete development) which may be associated with freemartinism (23).

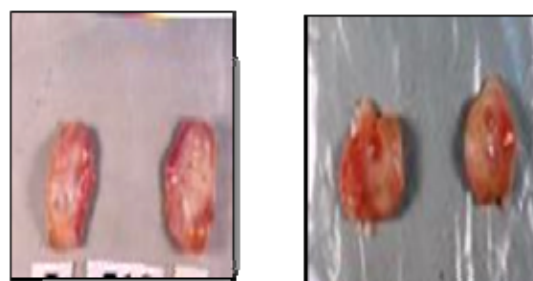
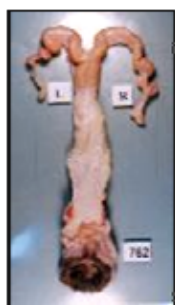

Figure 3: cystic ovary Absence of normal follicular growth pattern, few cysts \varnothing 1-2 mm on the surface of ovaries, follicular cysts \varnothing >3 mm on the right ovary.

In women, polycystic ovarian syndrome PCOS (24,25) due to fast GnRH pulses favorable for LH secretion, contribute to high level of Androgens, and this along with low levels of FSH unfavorable to poor egg development an ability to ovulation. Also, unnatural release of male hormones from theca cells layer which become atrophic leads to an increase in ovarian androgen (chronic hyperandrogenic anovulation) leads to male secondary sexual characters.

Gonadal dysgenesis

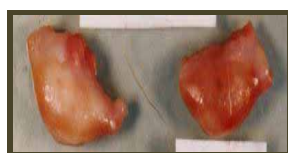
Figure 3 Gonadal dysgenesis with small ovaries or streak gonads with the absence of natural structures like germ-cells in single, or in cotwin to a male with defects of the tubular reproductive system due (26) to XX / XY Chimerism, or because of the impact hormonal factors excretion by the twin male, such as testicular determining factor, testosterone and the Müllerian inhibition factor, which prevent the formation of natural ovaries and Mueller duct from which various parts of the female internal genitalia are derived (27,28) or polled character. Gonadal dysgenesis in humans due to a complete X chromosome loss (X0 = syndrome Turner,) or partial deletion (29) of any missing piece of chromosome X, or because of mosaicism X0/XX (30) or Chromosome pattern X0/XY (11,31).



ovarian agenesis



ovarian hypoplasia



rudimentary gonadal streak

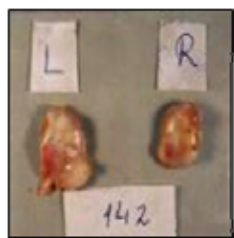

Figure 4: gonadal dysgenesis.

Ovarian Neoplasms in normal and in intersex goats

Tumors of the ovary have been described in all domestic species, although they are relatively uncommon. Based on the classification of primary ovarian tumors in women (9) and in domestic animals (32).

Simple serous adenoma or cystadenoma (Figure 5) is one of the most common epithelial neoplasia (32), It's cystic containing serous or sanguineous fluid. In the case of goat №366 the adenoma is associated with tumor resembling granular cell tumor, which is one of sex-cord stromal

tumor, having smooth surface and hard cystic section which having the capacity to produce both estrogen and androgen (33) and thus this will lead to Nymphomania and irregular heat cycles and the development of the mammary glands.

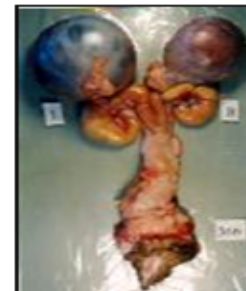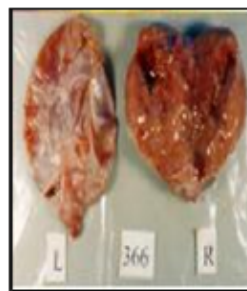


Figure 5: unilateral serous adenoma associated with a granular cell tumor in pyometric goat.

Epidermal epithelial mucinous tumors or pseudomucinous cystadenoma. This is bi-lateral (17) multi-housing common tumor, characterized (Figure 6) by white smooth surface, and consisting of small houses loculi which become fewer as the tumor grows in size by fusion of neighbor houses which remain distinguishable the pole of the tumor by forming an active proliferative zone The diameter could reach 15.2 cm (8). The thickness of the walls of loci and stromal invasion type indicate the beginning of borderline mucinos tumor malignancy (malignant Mucinous carcinoma).

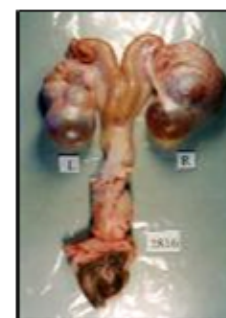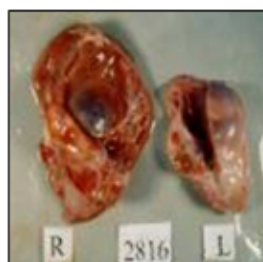


Figure 6: epidermal Epithelial Mucinous tumors; bilateral 6-8 cm multi-housing Mucinous tumor- generation of small daughters cysts groups small in the periphery of the tumor.

Malignant Dermoid cyst or variant of cystic teratoma (Figure 7). This tumor and Dysgerminomas are belonging to the Germ cells group. They are uncommon in domestic animals. The bi-lateral teratomas, having smooth surface, are similar in shape to Epithelial Mucinous tumors. It may

contain different cell elements (fatty substances, sebaceous, Keratin, hair) so called then miraculous cyst (8). Although, invaded wall and stroma indicate the lack of maturity and malignancy. Mucinous adenocarcinoma can cause abdomen distention as result of ascites, and false pregnancy (34).

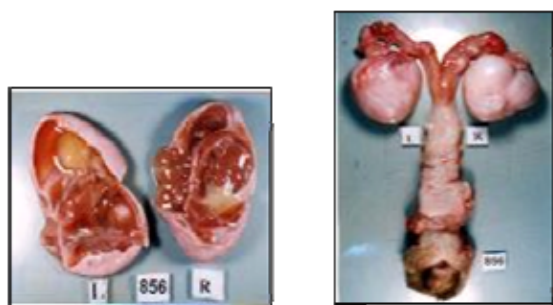


Figure 7: bilateral cystic teratoma or Dermoid cyst containing different tissues (yolk lutein, mucinous - and cartilage), Leiomyomas along the wall of the horns of the uterus in intersex.

Sex cord-Stromal Tumors or Dysgenetic gonad tumors linked to Hornless or polled character. They are histologically resembled to the normal cellular constituents of the ovary other than epithelium or germ cell (8,32). They also are capable of producing a diverse mixture of male and female sex hormones in addition to steroid hormones. The endocrine output from such tumors is often reflected in the behavior of afflicted animal and in induction of changes especially in the tubular genital tract. The tumors in this group are designed as granulose cell tumors, luteomas, thecomas, Sertoli cell tumors of the ovary, Leydig cell tumors, androblastoma, arrhenoblastoms or lipid cell tumors. In the cow, they are usually granulose-cell or Sertoli-cell type (32).

Germ -cells tumor formation from dysgenetic or ambiglandular form of gonads. Figures 8 mixed gonadal dysgenesis (MGD) due obviously to polled character leads to the formation one-sided *Dysgerminoma* which is one of sex cord stromal tumors (35) composed of germinal cells and their derivatives (13). It's a tumor similar to testicular tumor seminoma (11,31) as well as Sertoli-Leydig cell tumor which is also called male tumor Androblastoma. The opposite side is small mesenchymal hemangima proposed to arise in the corpora lutea (36).

The Gonadoblastoma also known as dysgenetic gonadomas, which is an unusual mixed Germ-cell-sex-cord stromal tumor affect in Human a subset of patients with intersex disorder with XY Karyotype, out of them 30% may progress to either dysgermioma/ seminoma (10).

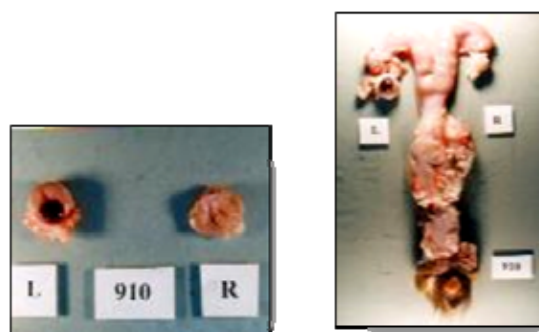


Figure 8: right Germ -cells tumor *dysgerminoma*, & left *hemangima* in intersex.

True Hermaphrodite: mixed gonadal dysgenesis. Figure 9 is showing mixed gonadal dysgenesis characterized by the presence of ovo-testes or ovary plus testis (true hermaphroditism) due to polled effect.

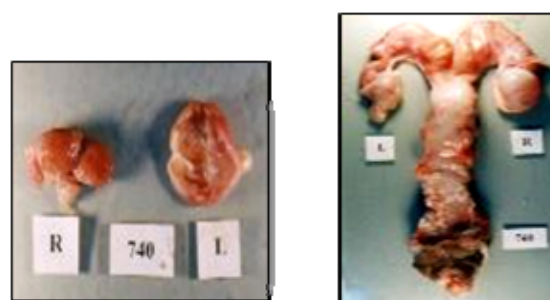


Figure 9: True Hermaphrodite mixed gonadal dysgenesis (left ovotestis, right small epithelial tumor).

As shown, various kinds of ovarian pathologies were found interestingly in the right ovary (37), which would be classified into: anovulation with failure of follicular growth beyond emergence, Cystic Ovarian Disease in female phenotypically goats, and with somewhat deformed genitalia, Neoplasms in normal and/or intersex goats, Gonadal dysgenesis and Ovarian tumors of Dysgenetic gonad linked to Hornless or polled character. The contralateral left ovary remaining remains sometimes unaffected but atrophic and this as result of increased circulating LH and FSH levels and disruption of the FSH in follitropin receptor knockout signaling mechanisms predisposing the aging ovary with concordance with (38), probably because the original mean size, weight and activity of right goat ovaries were more than of left ovaries (37). The paraovarian cyst as ovarian dysfunction was the only condition found, and likely more common that (3.95%) indicated by (37) in both normal and in intersex

goats with obviously goats with malformations of the reproductive system in intersex.

There are many arguments in favor the similitude between the disorder of sex development or differentiation in humans and hermaphroditism in goats. The first one include: Androgen Insensitivity Syndrome and testicular feminization syndrome with Congenital absence of the uterus (10) leading to the formation of testicles or streak gonads respectively, dysgenetic testicles that have both ovarian and testicular undifferentiated tissues in true Hermaphroditism (11), atrophic gonads on both sides in cases of pure gonadal dysgenesis (39), or one side testis and unilateral atrophic gonad in mixed gonadal dysgenesis (40) as result of abnormal chromosome patterns (10). Whereas the second is restricted to Freemartin or intersexuality linked with hornless or polled character (16,26,41) in XX, or True hermaphroditism in a horned goat with 60XX/60XY chimerism (3) leading towards the formation of testis-like gonads or seminal glands in male type (3,42), or hypoplastic testis and ovotestes in female type (5,43), in the inguinal region or in the abdomen, containing somniferous tubules with some primary follicles (12), or Ledig-cell tumor (30) in intersex goat affected by Polled Intersex Syndrome homozygous for a DNA deletion on chromosome 1 responsible for the Polled Intersex Syndrome (PIS) and an absence of SRY with normal XX karyotype (2,15,44,45). Some goat had some Y chromosome specific sequences such as SRY and BRY.I but lacked others, such as BOV97M (46).

The results permit us to conclude that Shami goats could be affected with ovarian dysfunctions and neoplastic lesions such as follicular cysts, epidermal tumors, Sex Cord-Stromal and Germ-cell tumors associated or no with malformation of the reproductive system similar to ovarian tumors in women.

The follicular cysts are the most frequent functional ovarian disease in a goat due to hormonal reasons. Epithelial ovarian tumors in goats like in women are characterized by their immense size. The ovarian dysgenesis (streak gonads) and the formation of tumors in dysgenetic gonads are the most important gonads affection in goat intersex.

Genital tract masculinization or ambiguous genitals of intersexes include: transformation of the gutter -shaped of the bottom of genitalia into papillary or pineal form, slight projection of the vulva to form bulbous vulva, or hypertrophic glands penis clitoris with the growth of hair in the docking of the abdominal genital opening, and eventually masculinization signs in the head shape and male behavior. Also, both Intersexuality linked with hornless or polled genotype in goats and disorder of sex development and differentiation cases in humans lead to gonadal dygenesis and ovarian neoplasm similar in formal and histopathological descriptions (as shown in the

references).The malformations of the reproductive system in Freemartin intersex specimen may be associated with sex chromosome aberrations(Mosaicism and Chimerism), except those linked to hornless trait which have normal female Karyotype (XX). So, it is of essential importance to evaluate minutely the reproductive system of the female after birth and before matting to exclude the homozygous genotype intersexes for polled trait (PP) with malformation of the reproductive system.

Acknowledgments

The researcher thanks Dr Fatimah I. AL-ASKAFF, specialist in gynecology and obstetrics, for here helpful devotement, and opinion exercise for the diagnosis of some ovarian pathological pattern in goats.

References

1. Gouraninezhad S, Esmailzadeh S, Sohrabi M. The study of the prevalence of intersex in slaughtered female goats in abattoir of Ahwaz, In *Animal and Fisheries Sciences*.2005;18(3)68: 99-103.
2. Pailoux E, Crihiu, EP, Chaffaux, S, Darre R. FELLOUS, M. et al., Molecular analysis of 60, XX pseudohermaphrodite polled goats for the presence of SRY and ZFY genes, *J Reprod Fertil*. 1994;100:491-496.
3. Bastista M, Gonzales F, Cabera F, Palomino E., Castellano E. True hermaphroditism in a horned goat with 60,XX/60,XY chimerism, *Canad Vet J*. 2000;41:562-564.
4. Crihiu EP, Schibler L, Vaiman D. Cartographie fine de la région du gène PIS de la chèvre, *INRA Production Animale, numéro hors série "Génétique moléculaire: principes et application aux populations animales"*; 2000 ;141-144.
5. Fernandez-garcia JL, Rabasco A, Martinez-tracon M, Padilla YJA. Caracterizacion anatomohistologica y Citogenetica de Hermafroditas caprinos.,*Arch. Zootec*, ;1990;135-143.
6. Monteagudo LV, Arruga MVI. Bonafontej O. Bilateral Leydig Cell Tumor in a six-year-old Intersex Goat Affected by Polled Intersex. *Vet Pathol Amer Coll Vet Patholo*. 2008;45:42-45.
7. Vallenzasca C, Galli A..Cytogenetical and histopathologic study of two cases of Polled goats. *Andrologia*. 1990;22 (3);289-90.
8. Howkins J, Bourne G. Show's Textbook of Gynecology. Churchill livingstone. 9th ed. 1971; p:712-749.
9. Scully RE. Classification of human ovarian tumors. *Environ Health Perspect*. 1987; 73: 15-24
10. Kini U, Bantwal G, Ayyar V, Idiculla J. Bilateral Gonadoblastomas with a left sided Dysgerminoma in a true Hermaphrodite (Disorder of Sexual Differentiation) with 46, XY Karyotype. *JAPI*.Vol 56; 2008;pp: 549-551.
11. Kriplani A, Agarwal N, Parul S, Manchanda R. Bilateral seminomas in a 45X/46XY mosaic with Turner's phenotype: An unusual case of mixed gonadal dygenesis. *J Obste & Gynaeco Res*. 2003;29(2) : 63-66.
12. Kyu-rae k, Youngmee K, Jae Young J, Kun Suk K, Alberto GA, True JY. Hermaphroditism and Mixed Gonadal Dysgenesis in Young Children: A Clinicopathologic Study of 10 Cases *Mod Pathol*. 2002;15(10):1013-1019
13. Scully RE. Gonadoblastoma. A review of case seventy-four *Cancer Cytopathology*. *Cancer J Clinic*. 1970; 25 (6)1340-1356.
14. Takebayashi SSG, Wilham J. Testicular hypoplasia in a horned goat with 60, XY; 61, XXY karyotype. *Japanes Gene*. 1986; 61:177-181.

15. Vaiman D, Koutita O, Oustray A, Elsen JM. Genetic mapping of the autosomal region involved in XX sex-reversal and horn development in goats. *Mammalian Genome*. 1996;7: 133-137.
16. Walter HJ. Managing Anovulation and Cystic Ovaries In Dairy Cows. *Adva Dairy Techno*. 2008;20:311-326.
17. Medan MS, Watanabe G, Sasaki K, Groome NP, Sharawy S, Taya K. Follicular and hormonal dynamics during the estrous cycle in goats. *Reprod Dev*. 2005; 51(4):455-63.
18. Miller CC, Williamson LH, Miller-liebi DM, Thompson FN. Lactation associated with acidophilic pituitary adenoma, pheochromocytoma, and cystic endometrial hyperplasia in tow goats. *J Am Med Assoc*. 1997;210:378-381.
19. Chand S, Chauhan HVS., Distribution of elastic, reticular and collagen fibers in uteri of sheep and goats under normal and some pathological conditions. *Haryana Agric. Univ. J Res J*. 1975; 66-70.
20. Jubb K, Kennedy PC, Palmer N. *Pathology of Domestic Animals*, Vol. 3, 3ed. Academic Press, New York, USA. 1985;305-323
21. Kennedy PC, Miller RB.. The female genital system. In: *Pathology of demostic animals*, Ed. Jubb KVF, Kennedy P.C., Palmer N., 4th ed., Academic Press, San Diego, CA; 1993; p.374-385.
22. Wiltbank MC, Gumen A, Sartori R. Physiological classification of anovulatory conditions in cattle. *Theriogen*. 2002; 57:21-52.
23. 37-Roberts S.L. *Veterinary obstetrics and genital disease*. Published by the author, Woodstock, Vermont; 1986; 521-522.
24. Allahbadia G, Agrawal RR and Merchant R. Polycystic Ovary Syndrome. *Medical*;497:2007; 222.
25. Talmon GA, Persidskii I, Agulizia J. A cystic mass in a young woman with presumed polycystic ovarian syndrome. *Arch Path Labor Med*. 2005;130 (2): 225-226.
26. Szatkowski I, Zychi S, Udala a J, Dybus P, Blaszczyk P. Freemartinism: three cases in Goats. *Acta Veter. Breed*. 2004; (73) 3: 75-378.
27. Hafez E. Intersexuality. *Reproduction in Farm Animals*. Chapter 21. Blackwell Pub Co. 1983; p:353-365.
28. Vigier B, Magres, Charpentier G, Bezard J, Josso N. Anti-mullerian hormone and natural and experimental freemartin effect. *Bulletin d'Association des Anatomistes (Nancy)* 75; 1991; 29-32.
29. Sybert VP, Mc Cauley E. Turner's Syndrome., *New England J Med*. 2003;51(4):1227-38.
30. Morgan T, Turner syndrome: diagnosis and management. *Am Fam Physician*. 2007;76, 405-410.
31. Zorlu F, Cengiz M, Gurkaynak M, Yildiz F. and L. ATAHAN Seminoma arising in Androgen insensitivity syndrome (testicular feminization syndrome): A case report, *Turkish J Cance*. 2001;31(4):168-171.
32. Mclachlan J. *Ovarian Disorders in Domestic Animals*. *Environ Health Perspes*. 1987;73: 27-33.
33. Janovitz E. Granulosa-Theca Cell Tumors in the Mare; *Animal disease Diagnostic Laboratory winter Newsletter*.2003.
34. Memon MA, Schelling SH, Sherman DM. Mucinous adenocarcinoma of the ovary as a cause of ascites in a goat, *J Am Vet Med Assoc*. 1995;206(3):362-364.
35. Young R, HOMER J. A brief history of the pathology of the gonads; *Modern Pathology*. 2005;18:3-15.
36. Hsu F. Ovarian hemangioma in swine. *Vet Pathol*. 1983; 20: 401-409.
37. Al-baggal har, Al-dahash SY, AlwanAF. Macroscopic study of the female genital system in Iraqi goats,. *Small Ruminant Res*. 1993; 9: 341-346.
38. Danilovich N, Roy I, Sairam MR.. Ovarian Pathology and High Incidence of Sex Cord Tumors in Follitropin Receptor Knockout (FORKO) *The Endocrine Society Vol*. 142; 2001; No. 8.
39. Cheifitz R, Katz M. Pure Gonadal (46, XY) Dysgenesis-An XY Female, S. *Afre.Med. J*. 1975; 49: 53-55.
40. Al-Awadi SA., Farag TI, Murthy DS, El-Badramany MH, Al-Azemi MK, Qurton M. Mixte Gonadal dysgenesis with structural Anomalies of Y-chromosome. *Kuwait Medical Genetics center, Maternity hospital; Ann Saudi Med*; 1994;14(3);267-.
41. Rahman MH, Chowdhury EH, Saha SS, ALAM GS. Abattoir study of reproductive diseases in goats. *Bangladesh Veterrin*. 2008;25(2);88-91.
42. Bongso TA, Thayalingam T, Mukherjee TK. Intersexuality associated with XX / XY mosaicism in a horned goat *Cytogenet Cell Genet*. 34;1982 ;315-319.
43. Kondo K. Studies on intersexuality in milk goats. *Japan J genet*. 1952;27(5-6):131-135.
44. Pailhoux E, Vigier BD, Vaiman N. Servel, S. Chaffaux. Ontogenesis of Female-to-Male Sex-Reversal in XX Polled Goats *INRA de Jouy en Josas in Developmental Dynamics*. 2002;224:39-50.
45. Pailhoux E, Vigier B, Chaffaux, Servel N, Taourit S, Furet JP, Fellous M, Grosclaude F, Cribiu EP, Cotinot C, VaimanD. A 11.7-kb deletion triggers Polledness and Intersexuality in goats. *Nat Genet*. 2001;29 (4);453-458.
46. Hafez SA, Huckle WR, Caceci T. . Anatomical, histological and genetic investigations of a sexually anomalous goat, *Vet Record*. 2005;157: 513-516.