

## Treatment of hyper-granulated limb wounds in horses

O. A. Bader<sup>1</sup> and M. J. Eesa<sup>2</sup>

<sup>1</sup> Department of Surgery and Theriogeniology, College of Veterinary Medicine, University of Mosul, Mosul,

<sup>2</sup> Department of Surgery and Obstetrics, College of Veterinary Medicine, University of Baghdad, Baghdad, Iraq

(Received February 26, 2008; Accepted May 19, 2010)

### Abstract

This study was performed to investigate the different methods of treating hyper granulation tissue on experimentally induced wounds in equine limbs. Wounds were induced by removal of a skin patch and subcutaneous tissue for about 5-7 cm width and 6-8 cm in length from the dorsal and lateral aspect of the fore and hind limbs below the carpal and tarsal joints. The wounds were left open without treatment and the animals were trained 2-2.5 hours every day for about 3-5 weeks until hyper granulation tissue was developed. The schedule for the treatment of hyper granulation was divided into five groups each contained eight wounds of hyper granulation tissue; each main group was divided into two subgroups. The subgroups of first, second, third, fourth and fifth groups were treated by the following schedules: bandage alone; copper sulphate ointment 10%; silver nitrate ointment 2%; red mercury ointment 11%; and laser therapy (at a total dose of 9.72 Joule / cm<sup>2</sup>) respectively. While the second subgroups were treated by surgical resection of the hyper granulation tissue, followed by the same treatments applied on the first subgroup. The bandage for all experimental groups was changed every 48 hours until healing was occurred. The clinical and histological observation of the first group revealed that the healing take long period comparing with other groups. The mean of wound healing were 65 days in non surgical removal of hyper granulation tissue subgroup, while 57 days in surgically removed of hyper granulation tissue subgroup. The results of the second, third, fourth groups revealed that the caustic material especially red mercury has a role in healing processes through depressing the hyper granulation tissue. The mean of wound healing of the second group was 42.25 days in non surgical removal of hyper granulation tissue subgroup while 37.25 days in surgically removed hyper granulation tissue subgroup. In the third group the mean of wound healing was 45.75 days in non surgical removal of hyper granulation tissue subgroup while 44.75 days in surgically removed hyper granulation tissue subgroup. While in the fourth group the mean of wound healing was 39 days in non surgical removal of hyper granulation tissue subgroup while 36 days in surgically removed hyper granulation tissue subgroup. In the fifth group the clinical and histological observation revealed that the using of laser lead to reduce the period for wound healing significantly comparing with other groups. The mean of wound healing was 25 days in non surgical removal of hyper granulation tissue subgroup while 20 days in surgically removed hyper granulation tissue subgroup, so that the laser was the best in this study and the using of surgical removal is better than of non surgical removal.

**Keywords:** Hyper granulation; Limb wounds; Equine.

Available online at <http://www.vetmedmosul.org/ijvs>

### علاج الفرط الحبيبي لجروح القوائم في الخيول

عمر عادل بدر<sup>1</sup> و محمد جواد عيسى<sup>2</sup>

<sup>1</sup> فرع الجراحة وعلم تناسل الحيوان، كلية الطب البيطري، جامعة الموصل، الموصل،  
<sup>2</sup> فرع الجراحة والتوليد، كلية الطب البيطري، جامعة بغداد، بغداد، العراق

### الخلاصة

أجريت هذه الدراسة لبيان تأثير طرائق علاجية مختلفة لعلاج حالة فرط النسيج الحبيبي في الجروح المحدثة تجريبيا في قوائم الخيل. تم إحداث الجروح بإزالة جزء من الجلد والنسيج تحت الجلد بمساحة تراوحت بين 6-8 سم طولاً و 5-7 سم عرضاً وتم إحداث الجروح

في الجهة الظهرية والوحشية لكلا القائمتين الأمامية والخلفية أسفل مفصل الرسغ بعد ذلك تركت الجروح مفتوحة ومن دون علاج وتم ترويض حيوانات التجربة يوميا لمدة ساعتين - ساعتين ونصف ولمدة 3-5 أسابيع لحين ظهور فرط النسيج الحبيبي بشكل واضح. تم تقسيم حيوانات التجربة إلى خمس مجاميع رئيسية ضمت كل مجموعة 8 جروح وكل مجموعة رئيسية قسمت إلى مجموعتين ثانويتين. عولجت المجاميع الثانوية الأولى للمجاميع الرئيسية الأولى والثانية والثالثة والرابعة والخامسة باستخدام العصابة لوحدها، مرهم كبريتات النحاس 10%، مرهم نترات الفضة 2%، مرهم الزئبق الأحمر 11% والليزر (بجرعة كلية 9,72 جول / سم<sup>2</sup>) على التوالي. أما في المجاميع الثانوية الثانية فقد عولجت باستخدام الإزالة الجراحية للنسيج الحبيبي الزائد ومن ثم تم وضع نفس المواد السابقة التي تم وضعها في المجاميع الثانوية الأولى. أوضحت النتائج السريرية والنسجية أن المجموعة الأولى استغرقت وقتا طويلا مقارنة مع باقي المجاميع الأخرى حيث بلغ معدل التئام الجروح في المجموعة الثانوية التي لم يتم إجراء الإزالة الجراحية فيها 65 يوما أما في المجموعة الثانوية التي تم إجراء الإزالة الجراحية فيها 57 يوما. بينت المجاميع الثانية والثالثة والرابعة التي استخدمت فيها المواد الكاوية وخاصة الزئبق الأحمر أن هذه المواد لعبت دورا مهما في التئام الجروح من خلال تثبيط نمو النسيج الحبيبي المفرط حيث كان معدل التئام الجروح في المجموعة الثانوية التي لم يتم إجراء الإزالة الجراحية فيها 42,25 يوما أما في المجموعة الثانوية الأخرى كان 37,25 يوما للمجموعة الرئيسية الثانية. أما في المجموعة الثالثة كان معدل التئام الجروح في المجموعة الثانوية التي لم يتم إجراء الإزالة الجراحية فيها 45,75 يوما أما في المجموعة الثانوية الأخرى كان 44,75 يوما. بينما في المجموعة الرابعة كان معدل التئام الجروح في المجموعة الثانوية التي لم يتم إجراء الإزالة الجراحية فيها 39 يوما أما في المجموعة الثانوية الأخرى كان 36 يوما. أشارت النتائج السريرية والنسجية للمجموعة الخامسة أن استخدام الليزر أدى إلى تقليل فترة التئام الجروح وبشكل ملحوظ مقارنة مع المجاميع الأخرى حيث بلغ معدل التئام الجروح في المجموعة الثانوية التي لم يتم إجراء الإزالة الجراحية فيها 25 يوما أما في المجموعة الثانوية الأخرى كان 20 يوما. لذلك عد الليزر الأفضل في هذه التجربة أيضا فان إجراء الإزالة الجراحية لفرط النسيج الحبيبي يعد أفضل من عدم إجرائها.

## Introduction

Equine limbs suffer traumatic wounds more than other animals and these wounds mostly heal by second intention healing which may be associated with some complications such as wound infections, tumor or hyper granulation tissue (1-3). The natural response of the body to form granulation tissue was resists infection and helps to full cavity of wounds, beside that creates a good surface for migration of epithelial cells to complete healing (4,5). Many factors may help the formation of hyper granulation tissue in equine limbs such as body size, age of animal, wound location, early wound care such as topical medical application, bandage and casting help to minimize hyper granulation tissue formation (1,6-10). Treatments of hyper granulation tissue depend on the amount of excessive tissue formation and duration of time, many methods were used in this field such as caustic material (11-13), cryogenic surgery (14,15), surgical resection which is regarded as a good method because it dose not affect on epithelization when compared with chemical material (3,7,11), topical steroids (16), skin grafting was used after resection of hyper granulation tissue from a large area (7,17) and low-power laser therapy in high doses (18). The aim of this study was to find a good method for treating hyper granulation tissue through comparing several methods of treatment.

## Materials and methods

Twenty horses of local breed 3-8 years in age, 250-400 Kg in weight and from both sexes were used in this study.

The animals were healthy and did not suffer from any affection.

## Inducing hyper granulation tissue

Animals were anaesthetized by using acepromazine (0.02 mg/kg B.W) intravenously as a premedication. Ten minutes later using thiopental sodium (1g/90 kg B.W) intravenously and repeated at a half doses if needed. Clipping and shaving the area of lateral and dorsal aspect of metacarpal and metatarsal bones. Wound was induced by removal of a skin patch with subcutaneous tissue for about 5-7 cm width and 6-8 cm length from the dorsal and lateral aspect of fore and hind limbs of metacarpal and metatarsal bones (Figure 1 a). The wounds were left open and the animals were trained daily for 2-2.5 hours/ day for about 3-5 weeks, until hyper granulation tissue was developed (Figure 1B).

## Treatment

The experimental animals were divided into five groups, each contained four animals and each group was divided into two equal subgroups, each subgroups consisted of four wounds; First group (Control): The first four wounds were treated by application of pressure bandage over the hyper granulation tissue while the other four wounds were treated by surgical resection of hyper granulation tissue to the level of skin, then application of pressure bandage. Second group: The first four wounds were treated by using copper sulphate ointment 10% locally with pressure bandage, while the other four wounds were treated by surgical removal of hyper granulation tissue and using copper sulphate ointment 10% with pressure bandage. Third group: The first four

wounds were treated by application of silver nitrate ointment 2% locally with pressure bandage and the other four wounds were treated by surgical resection of hyper granulation tissue, then using silver nitrate ointment 2% with bandage. Fourth group: The first four wounds were treated by application of red mercury ointment 11% locally with pressure bandage, other four wounds were treated by surgical resection of hyper granulation tissue and using red mercury ointment 11% with bandage. Fifth group: The first four wounds were treated by laser radiation using Helium-neiun (He-Ne), Infrared (IR) with bandage, (He- Ne  $6 \times 10^{-3}$  and IR  $3 \times 10^{-3}$ ). Twelve sessions, one day rest between 3 sessions, the duration of radiation was 18 minute for each day. The amount of energy of He- Ne ( $0.54 \text{ J/cm}^2$ ) and ( $0.27 \text{ J/cm}^2$ ) for IR in each session. The total amount of energy of He- Ne, IR for twelve sessions was  $6.48 \text{ J/cm}^2$ , and  $3.24 \text{ J/cm}^2$ , respectively, so that the total amount was  $9.72 \text{ J/cm}^2$ , other four wounds were treated by surgical resection of hyper granulation tissue, then using laser radiation as same in above with pressure bandage.

In all first subgroups, bandage was changed every 48 hours until hyper granulation tissue became at the level of skin and epithelial cells migrate to the area, while in the second subgroups on which hyper granulation resection were performed (Figure 1C), the bandage was remained until wound became stable and epitheliazation started to invade the area. Clinical follow up of the animals during experimental period was practiced i.e. animal's appetite, wounds condition and degree of healing, lameness, and measurement of the thickness of hyper granulation tissue before and after treatment by using a caliper.

Biopsies were taken from the hyper granulation tissue before and after treatments at the period of clinical healing from all groups to identify the nature of healing and to compare the degree of healing between these five groups. Hematoxylin and Eosin, MasonTrichrom and Blue Alishin staining (19 - 21) were used to investigate the nature of tissue.

Statistical analyse were done by using analysis of variance. The difference was determined by LSD at the level of ( $P < 0.05$ ), and using statistical program SPSS (SPSS Inc).

## **Results**

The clinical findings revealed that the average thickness of hyper granulation tissue were 2 - 2.25 cm after 3-5 weeks from wounds inducing (Figure 1B).

First group: in non surgical resection subgroup, pus formation was observed during dressing but there was no sensation, lameness or bleeding. While in surgical excision of hyper granulation tissue subgroup, the signs were the same as above but less pus formation was observed.

Second group: the clinical signs were similar to that seen in the first group, but less in degree.

Third group: in non surgical resection subgroup, excessive amount of pus and bleeding observed during bandage change but the discharge decreased gradually, tissue sloughing especially at the central lesion, pain and lameness, were observed. The signs of surgical resection subgroup were similar to the non surgical resection once.

Fourth group: both the surgical and non surgical resection subgroups, show similar clinical signs in the form of little amount of pus exhibited during bandage change, no bleeding, pain or lameness during treatment were observed.

Fifth group: in non surgical resection of hyper granulation tissue subgroup the signs revealed that the superficial layers of the hyper granulation tissue dissolved after 10 minutes of laser radiate, and at the end of each radiation session, the tissues appeared as it was cooked. There was no pain or lameness, with little pus but without bleeding at the time of bandage changing.

Clinically the partial or complete wound healing after treatment as in 1<sup>st</sup>, 2<sup>nd</sup>, 3<sup>rd</sup>, 4<sup>th</sup> and 5<sup>th</sup> groups were appeared in (Figures 1D), (Figures 2A, 2B, 2C and 2D) and (Figures 3A, 3B, 3C and 3D).

In all experimental animals wound healing of hind limbs was faster than of fore limbs, and of lateral aspect was faster than wounds located on dorsal aspect of both fore and hind limbs.

Different degrees of tissue depression were recorded by using caliper in non surgical resection of hyper granulation tissue of experimental subgroups, after using pressure bandage in first group and different caustic material in 2<sup>nd</sup>, 3<sup>rd</sup> and fourth group or laser therapy as in fifth group. This variation of depression was summarized in Table 1. The mean degrees of wound healing for the experimental groups were recorded and summarized in Table 2.

The histopathological findings of the hyper granulation tissue before treatment revealed severe proliferation of fibroblast with minimal amount of collagen fibers. There was severe infiltration of mononuclear and multinuclear inflammatory cells around newly blood vessels (Figure 4 A). While the microscopic findings for the biopsies taken at the period of clinical healing revealed that the formation of epithelial cells from the edge of skin and invade the area to cover it (Table 3).

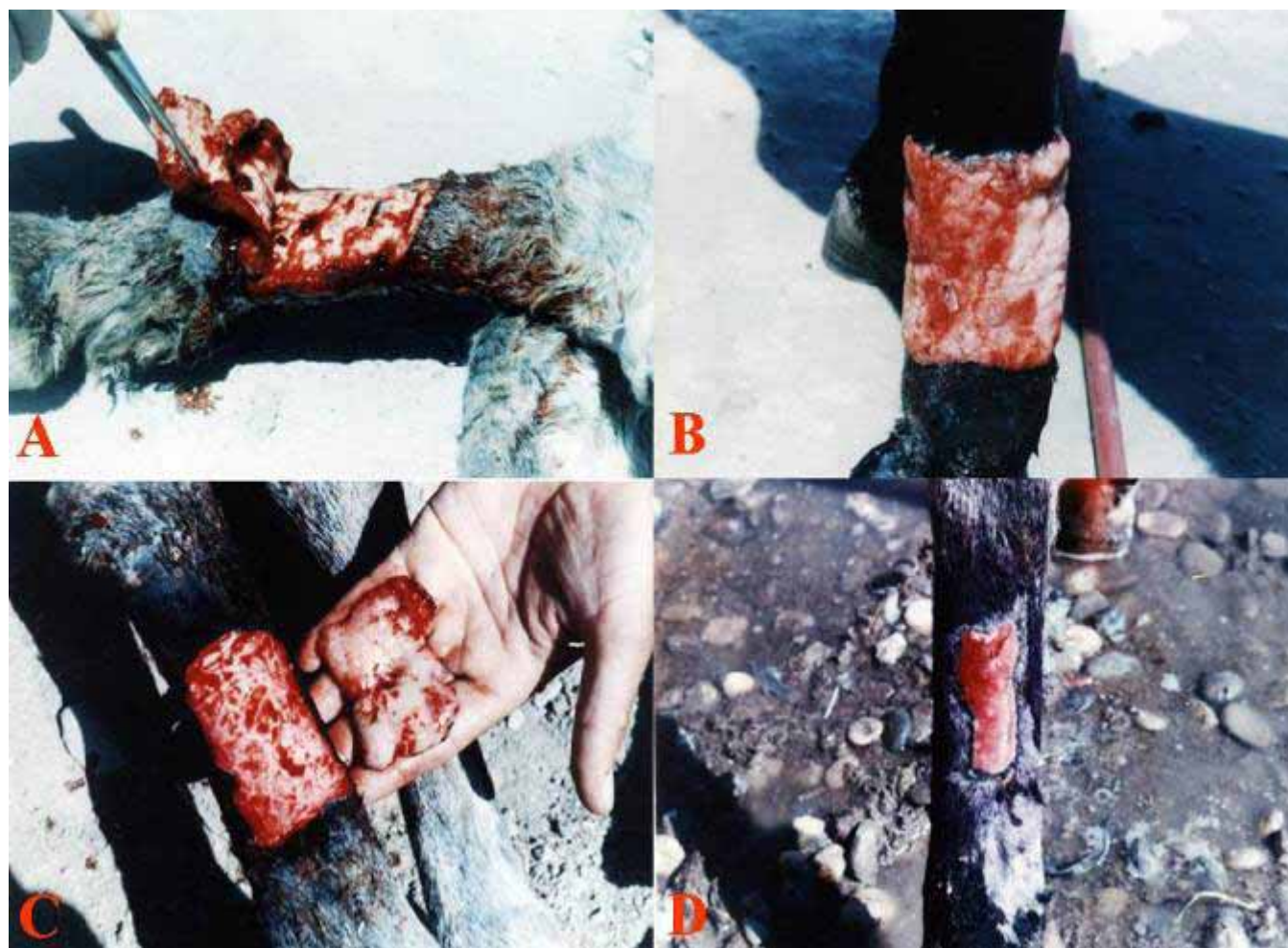

Figure 1: (A) Surgical resection of skin flap from lateral surface of fore limb. (B) Hyper granulation tissue formation after 35 days of inducing wound. (C) Complete resection of hyper granulation tissue after 5 weeks of inducing wound. (D) Partial wound healing after 40 days of treatment in non surgical resection of hyper granulation tissue in control group.

Table 1: Mean and standard error of depression of non surgical resection of hyper granulation tissue. The different letters means significances difference at the level of  $P < 0.05$ .

Days	Control	Copper sulphate	Silver nitrate	Red mercury	Laser
2	19.4±0.2646 a	17.2±0.4262 b	17.1±0.2780 b	17.19±0.4546 b	15.3±0.263 c
6	17.1±0.6884 a	13.5±0.4491 b	14.55±0.2483 b	14.0±0.5105 b	1.7±0.2944 c
10	15.1±0.5598 a	8.1±0.4328 b	9.2±0.2750 c	6.1±0.3198 d	----
14	12.9±0.3851 a	3.4±0.3425 b	5.7±0.1871 c	1.5±0.2217 d	----
18	10.6±0.3816 a	----	2.4±0.1291 c	----	----
22	8.3±0.5023 a	----	0.4±0.1291 b	----	----
26	5.3±0.4516 a	----	----	----	----
30	2.6±0.2415 a	----	----	----	----
34	0.8±0.2926 a	----	----	----	----
Mean	10.9±0.7402 a	5.4±0.8269 b	6.2±0.2850 b	5.0±0.8503 b	2.5±0.7025 c

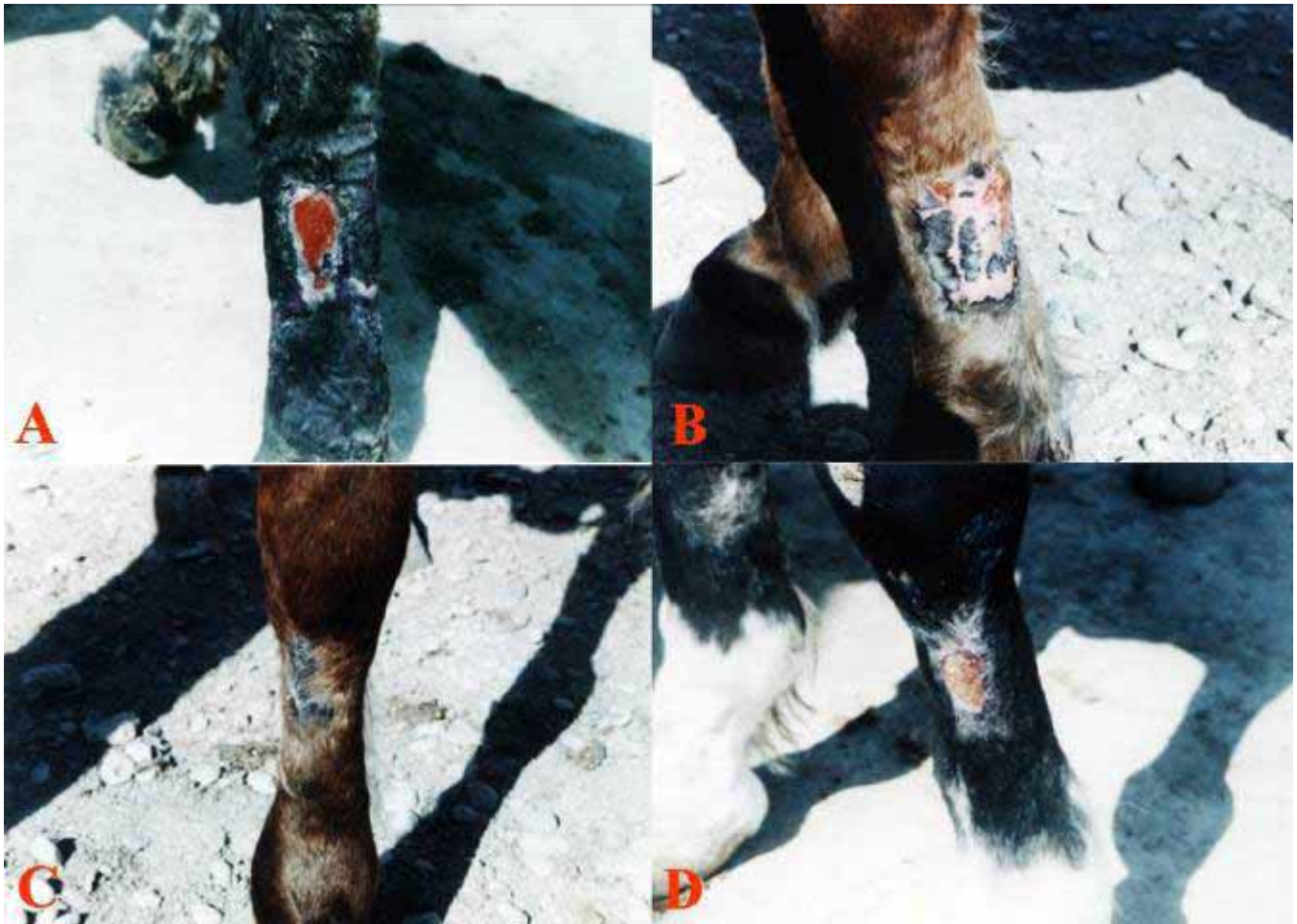

Figure 2: (A) Partial wound healing after 35 days of treatment in surgical resection of hyper granulation tissue in control group. (B) Partial wound healing after 35 days of treatment in non surgical resection of hyper granulation tissue in second group. (C) Complete wound healing after 35 days of treatment in surgical resection of hyper granulation tissue in second group. (D) Partial wound healing after 40 days of treatment in surgical resection of hyper granulation tissue in third group.

Table 2: Show the mean of wound healing in experimental groups. The different letters means significances difference at the level of  $P < 0.05$ .

Groups	Surgical resection	Degree of healing /days
Control	With out surgical resection	$65 \pm 0.9129$ a
	With surgical resection	$57.25 \pm 1.25$ b
Copper sulphate	With out surgical resection	$42.25 \pm 2.2867$ ce
	With surgical resection	$37.25 \pm 2.0156$ cf
Silver nitrate	With out surgical resection	$45.75 \pm 2.1747$ b
	With surgical resection	$44.75 \pm 1.75$ e
Red mercury	With out surgical resection	$39 \pm 1.9579$ cg
	With surgical resection	$36 \pm 2.2730$ dfg
Laser	With out surgical resection	$25 \pm 1.0801$ h
	With surgical resection	$20 \pm 0.8165$ h

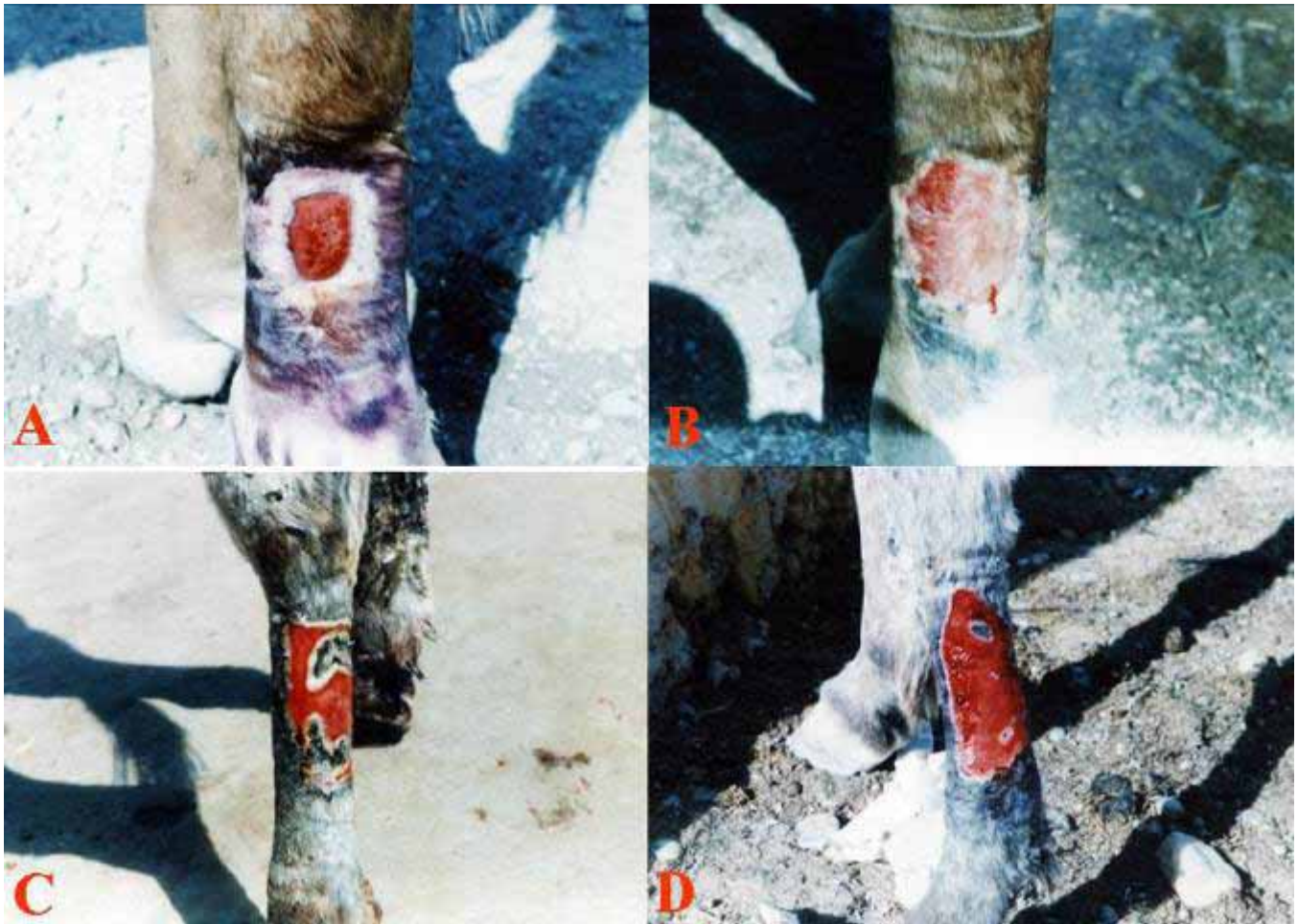


Figure 3: (A) Partial wound healing after 20 days of treatment in non surgical resection of hyper granulation tissue in fourth group. (B) Partial wound healing after 18 days of treatment in surgical resection of hyper granulation in fourth group. (C) Partial wound healing after 15 days of laser treatment in non surgical of hyper granulation tissue in fifth group. (D) Partial wound healing after 11 days of laser therapy in surgical resection of hyper granulation tissue in fifth group.

## Discussion

Healing of equine limb's wounds are usually associated with complications such as hyper granulation tissue, infection by bacteria, virus or fungus and may affect by tumor (22,23). The proliferation stage of wound healing in equine is important due to the formation of granulation tissue to repair the wound not stay at the level of skin edge, but continue to grow over the level of skin especially at the lower limbs (24).

In this study open wound induced in lower limbs after 3-5 weeks of training produced hyper granulation tissue. Its formation might be due to high skin tension and excessive movement of the area, in addition the decrease of blood supply at this region. This opinion is in agreement with authors (1), while (23) said that the formation of hyper

granulation tissue in equine limbs caused by epidermal growth factors and fibroblast growth factor.

The results indicated that wound healing of distal fore limbs were slower than distal hind limbs at the same location, this may be due to skin tension or anatomical variation and this coincide with (6). In addition to that my opinion of this result may be due to over 60-70 % of body weight loaded by fore limbs so that it gets more tension and movement than hind limbs.

The wound healing of lateral aspect of fore and hind limbs was faster than dorsal aspect of fore and hind limbs. This phenomenon may be due to the tension which is more in dorsal surface than in lateral aspect beside that the blood supply was less in dorsal aspect than in lateral aspect, this fact coincides with (6).

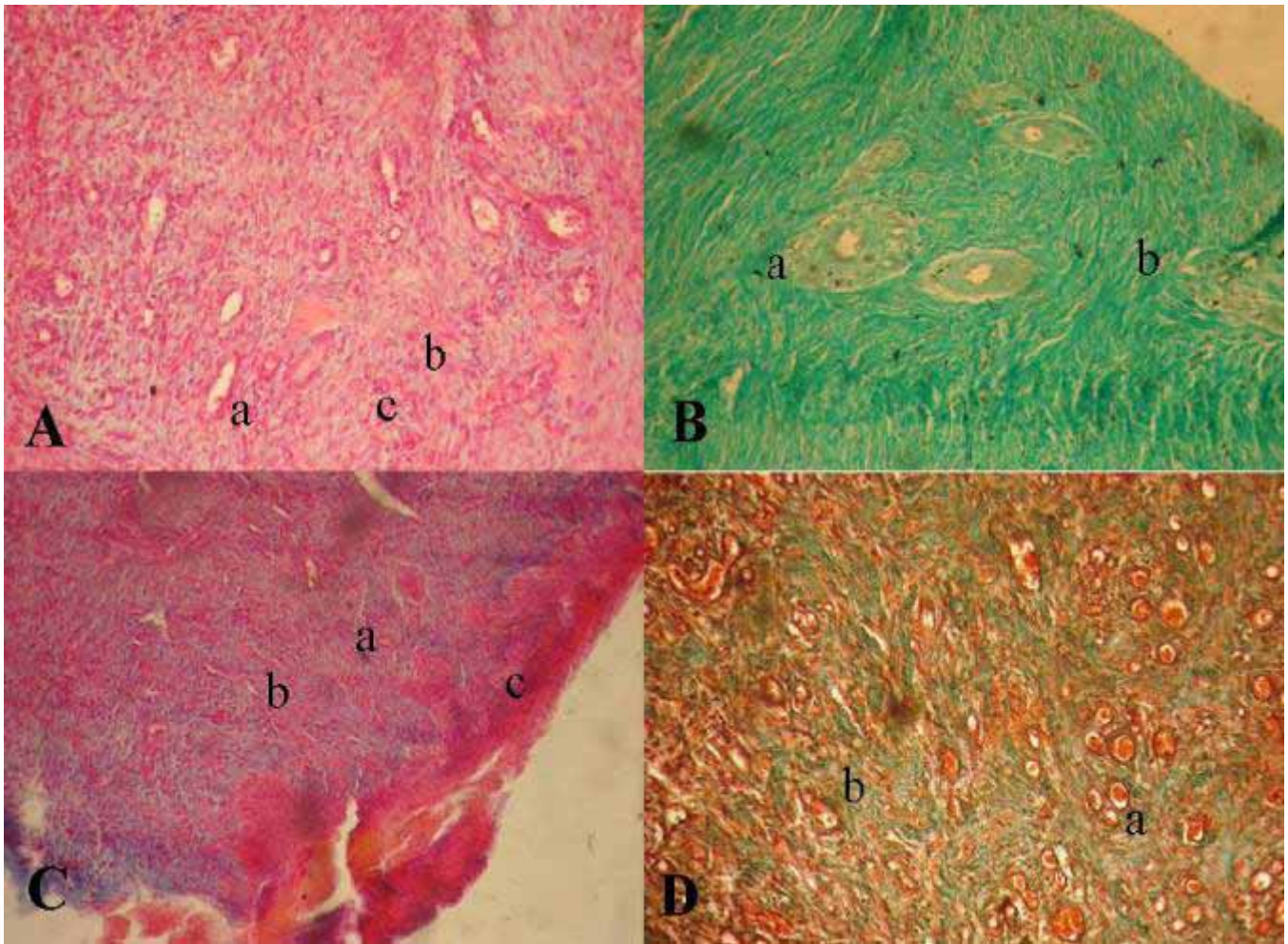


Figure 4: (A) Granulation tissue, which characterize by proliferation of fibroblast (a) and infiltration of inflammatory cells (b) and collagen fibers(c). H&E, 100 X. (B) Dense collagen fibers formation (a) with newly blood vessels (b). Non surgical resection of hyper granulation tissue of control group. Mason Trichrom, 100 X. (C) Congestion of blood vessels (a), proliferation of collagen fibers (b), epithelization appeared (c). Non surgical resection of hyper granulation tissue of second group. H&E, 75 X. (D) Congestion of blood vessels (a), proliferation of collagen fibers (b). Surgical resection of hyper granulation tissue of second group. Mason Trichrom, 100 X.

Surgical removal of hyper granulation tissue promote healing, this may be due to the immediate resection of hyper granulation tissue made the area at the level of skin so it gives more chance for proliferation of epithelial cells to migrate into the excision site. This appears in results of surgical resection of hyper granulation tissue in first group as compare with non surgical resection of hyper granulation tissue of the same group (Table 2), this agreement with other workers (11).

The role of copper sulphate ointment on depression of hyper granulation tissue appeared from results in (Table 2). The mean degree of wound healing were  $42.25 \pm 2.2867$

and  $37.25 \pm 2.0156$  days of non surgical and surgical resection of hyper granulation tissue respectively. This means that copper sulphate can be able to depress hyper granulation tissue and lead to enhance healing. The histopathological findings was documented these results and there was significant difference between this group and first group (Table 3), this fact coincides with (13).

The mean degree of wound healing was  $45.75 \pm 2.1747$  days with non surgical and  $44.75 \pm 1.75$  days for surgical resection of hyper granulation tissue in third group (Table 2). This indicated that silver nitrate ointment has the ability to depress hyper granulation tissue and enhance healing

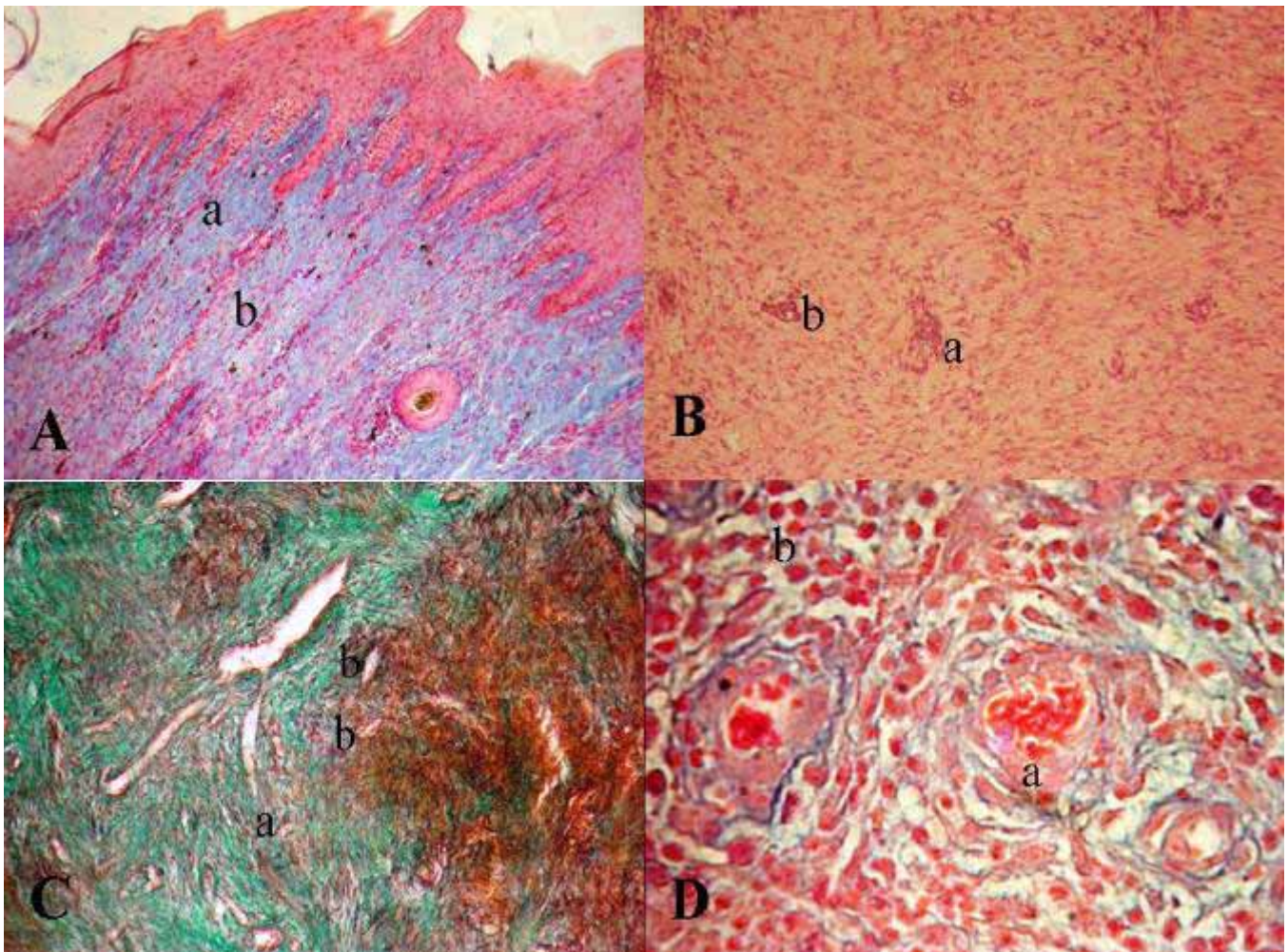


Figure 5: (A) proliferation of newly blood vessels (a) collection of collagen fibers which appear vertical in position with epidermis (b). Non surgical resection of hyper granulation tissue of third group. Alishin blue, 100 X. (B) Sever proliferation of fibroblast with collection of collagen fiber (a) and newly blood vessels formation (b). Surgical resection of hyper granulation tissue of third group. H&E, 100 X. (D) Proliferation of fibroblast (a), infiltration of mono inflammatory cells (b). Surgical resection of hyper granulation tissue of fourth group. Alishin blue, 400 X. (C) Granulation tissue formation (a), newly blood vessels formation (b). Non surgical resection of hyper granulation tissue fourth group. Mason Trichrome, 100 X.

when compare with first group, this agree with author (11). On the other hand lameness associated with this group may be due to pain. The pain may result from sever irritation by silver nitrate ointment which affect on tissue and produce sever inflammation or may result from absorption of silver nitrate and affect on nerve ending. This coincide with other worker (25).

Bleeding, severe irritation, pus formation and lameness were considered as a disadvantages of silver nitrate ointment which recorded in this study. The histopathological findings revealed that hyperkeratosis and necrosis which may be due to severe irritation of silver nitrate ointment on tissue. The stimulation of keratinocytes

cells need more study to investigate the effect of silver nitrate ointment in different percentage on hyperkeratosis.

The mean degree of wound healing of red mercury ointment in fourth group were  $39 \pm 1.9579$  and  $36 \pm 2.2730$  days of non surgical and surgical resection of hyper granulation tissue respectively. The results indicated that this ointment produced good depression on hyper granulation tissue as compared with copper sulphate and silver nitrate ointments and create good chance for epithelization to complete healing. This may be due to stimulation of phagocytes to produce growth factor, which derived from fibroblast (23).



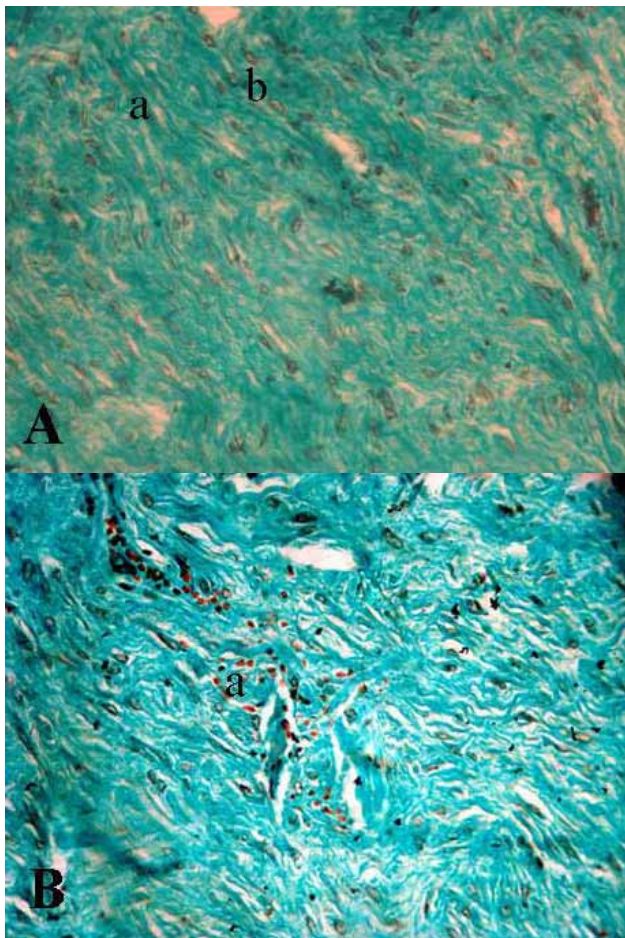


Figure 6: (A) Collection of collagen fiber (a), newly blood vessels formation (b). Non surgical resection of hyper granulation tissue of laser therapy. Mason Trichrom, 200 X. (B) Infiltration of mononuclear inflammatory cells (a) through collagen fibers. Surgical resection of hyper granulation tissue of laser therapy. Mason Trichrom, 400 X.

The results of laser therapy were exhibited that there was significant difference in between this group and other groups of this study. The mean degree of wound healing were  $25 \pm 1.6801$  and  $20 \pm 0.8165$  days in non surgical and surgical resection respectively. The ability of laser to depress hyper granulation tissue may be due to depression of growth factor which associated with granulation tissue formation, beside that the laser may affect on proliferation of macrophage which contribute to stimulate fibroblast to produce collagen fiber, this agreed with (26,27).

Laser therapy caused increasing temperature which change the nature of protein or lead to vaporization of liquid in the tissue. Laser leads to increase temperature of water in the intracellular cells which causes burst of cells (28).

There was no pain in laser therapy, this may be due to the increasing endorphin, metenkephalin and beta-endorphin which decrease pain, this agree with (26,27).

Table 3: Show histopathological study of all groups and subgroups.

Groups	Non surgical resection of hyper granulation tissue	Surgical resection of hyper granulation tissue
Control	Excessive collagen fibers formation mixed with sever mononuclear inflammatory cells. Minimal proliferation of newly blood vessels (Figure 4A).	Fibroplasias with dense collagen fibers. Mild infiltration of mononuclear inflammatory cells. Sever proliferation of newly blood vessels like cluster (Figure 4B).
Copper sulphate	Fibroplasias with infiltration of inflammatory cells. Newly blood vessels formation and epithelization was appeared (Figure 4C). Sever fibroblastic, nidus of inflammation with infiltration of inflammatory cells.	Sever fibroplasias and newly blood vessels formation with infiltration of mononuclear inflammatory cells (Figure 4D). Fibroplasias and there was nidus of newly blood vessels which surrounded by inflammatory cells.
Silver nitrate	Sever collection of collagen fibers and blood vessels to form a rod like taken the vertical position with epidermal layer (Figure 5A). Proliferation of fibroblast and collection of collagen fiber. Sever infiltration of mononuclear and multinuclear inflammatory cells (Figure 5C).	Precipitate of hemosidrin. Necrosis of epidermal layer (Figure 5B). Sever proliferation of fibroblast, decrease the amount of collagen fibers, infiltration of mononuclear cells around newly blood vessels (Figure 5D).
Red mercury	Mature granulation tissue which mixed with mononuclear inflammatory cells. Formation of newly blood vessels (Figure 6A).	Collagen fibers which infiltrated with mononuclear inflammatory cells. Proliferation of newly blood vessels (Figure 6B).

## Conclusions

This study indicated that wounds healing of surgical resection of hyper granulation tissue was faster than non surgical resection, and the wound healing of distal fore limbs were slower than distal hind limbs and the dorsal aspect of distal limbs were slower than lateral aspect of limbs.

Different caustic materials were used in this study which lead to depress hyper granulation tissue at varying level and promote healing at different degrees. The disadvantage of silver nitrate ointment causes necrosis, slough, pain and lameness, while red mercury ointment gave best results when compared with other caustic materials. In addition to that the literature exhibit that red mercury ointment not used by other authors in treatment of hyper granulation tissue in equine.

The laser therapy gets the best results when compare with other methods used in this study. The literature appeared that the laser therapy not widely studied in this field, in addition to that the histopathological study not used by other worker to document the results specially in laser therapy of hyper granulation tissue.

## References

1. Jacobs KA, Leach DH, Fretz PB, Townend HGG. Comparative aspects of the healing of excisional wounds on the leg and body of horses. *Vet Surg.*1984;13:83-90.
2. Monahan CM, Champman MR, Taylor HW, French DD, Klei TR, Knottenbelt DC. Equine wound management: Are there significant differences in healing at different sites on the body. *Vet Dermatol.*1997;8(4):273-290.
3. Lindsay WA. Wound treatment in horses: what to know about second intention healing. *Equine pract.*1988;10:396-403.
4. Lee AG, Swaim SF. Granulation tissue: how to take advantage of it in management of open wounds. *Como contin Educ pract Vet.*1988;10:163.
5. Stashak TS. *Equine wound management.* 1st ed, Philadelphia, Lea and Febiger. 1991; pp:40-44.
6. Bertone AL, Sullins KE, Stashak TS, Norrdin RW. Effect of wound location and the use of topical collagen gel on exuberant granulation tissue formation and wound healing in the horse and pony. *AMJ Vet Res.* 1985;45(7):1438-1444.
7. Bertone A.L. Management of exuberant granulation tissue. *Vet Clin North Amer.. Equine Pract* 1989; 5 (3) :551-562.
8. Wilmink JM, Stolk PWT, van Weeren PR, Barneveld A. Differences in second intention wound healing between horses and ponies: Macroscopic aspects. *Equine Vet J.*1999;31:53-60.
9. Wilmink JM, Nederbraagt H, van Weeren PR, Stolk PWT, Barneveld A. Differences in wound contraction between horses and ponies :the in vitro contraction capacity of fibroblast. *Equine Vet J.*2001;33:499-505.
10. Harris B, Eaglstein WH, Falanga V. Basal cell carcinoma arising in venous ulcers and mimicking granulation tissue. *J Dermatol Surg Oncol.* 1993;19(2):150-152.
11. Ovington LG. What to do with too much of a good thing. *Cover wound care.*1999;4(4):680-681.
12. Cultar RS. Copper sulphate treatment of proud flesh. *Vet Rec.*1973;92(26):711-712.
13. Frank ER. Wounds and infection. In *Veterinary surgery* 7<sup>th</sup> ed. Jain SK. CBS Publishers and distributors. India. 1981;pp:47-48.
14. Fretz PB, Martin GS, Jacobs KA. Treatment of exuberant granulation tissue in the horse: Evaluation of four methods. *Vet Surg.*1983;12:137-140.
15. Seim HB. Mechanisms of cold induced cellular death. *Vet clinic North Amer Small Anim Pract.*1980;10:755.
16. Barber SM, Caron J. The effect of bandaging on second intention wound healing in the horse. *Vet Surg.*1987;16:82.
17. Stashak TS. Free skin grafting in the horses. *Vet Clin North Amer Large Anim Pract.*1984;12:315.
18. Worth M. Low level laser therapy provides new treatment possibilities. *Wound Equine Vet* 1998;3(3):7-18.
19. Luna LG. *Manual of histologic staining methods of the armed forces institute of pathology,* 3<sup>rd</sup> ed. McGraw Hill Book Co., Inc, New York, USA. 1968;pp:94-95.
20. Drury RAB, Wallington EA. *Carleton's histological techniques* 5<sup>th</sup> ed. Oxford university press, London. 1980;pp:57-68, 140-142.
21. Pearse AGE. *Histochemistry theoretical and applied* 4<sup>th</sup> ed. Analytical technology, Churchill Livingstone, Edinburgh. 1985;pp:1,849.
22. Miller RM. Sound and healthy :proud flesh. *Western Horseman.* 1993;58(4):33-34.
23. Cochran CA, Freeman KL, Knottenbelt DC. Effect of growth factors on the characteristics of cells associated with equine wound healing and sarcoid formation. *Wound Rep Reg.*1996;4(1):65-85.
24. Bertone AL. Principles of wound healing. *Vet Clin North Am :Equine Pract.* 1989 b;5(3):449-463.
25. Sibbald RG, Williamson D, Orsted HL, Campbell K, Keast D, Krasner D, Sibbald D. Preparing the wound bed-debridement, bacterial balance and moisture balance. *Ostomy wound management.* 2000;46(11):14-35.
26. Ebert DW, Bertone AL, Robert C. Effect of irradiation with a low-intensity diode laser on the metabolism of equine articular cartilage in vitro. *Am J Vet Res.*1998;59(12):1613-1618.
27. Ramey DW, Basford JR. Laser therapy in horse. *Compendium* 2000;22(3):263-271.
28. Klause SE, Roberts SM. Lasers and Veterinary surgery. *Compendium small Anim.*1990;12(11):1565-1576.