



Evaluation of antidiabetic activity of zinc oxide and chromium oxide nanoparticles alone or in combination on the pancreas of alloxan-induced diabetes mellitus in male albino mice (*Mus musculus*)

M.M. Al-Murshidi¹ , I.A. Khadhim¹ , H.S. Al-Mafragy²  and H.M. Al-Saily³ 

¹Department of Biology, College of Science for Women, University of Babylon, Babylon, ²Department of Biology, College of Education for Pure Science, University of Karbala, Karbala, ³Department of Biology, College of Science, University of Babylon, Babylon, Iraq

Article information

Article history:

Received 16 February, 2023
Accepted 20 November, 2023
Available online 01 January, 2024

Keywords:

ZnONPs
Cr₂O₃NPs
Diabetes
Alloxan
Histology

Correspondence:

M.M. Al-Murshidi
manarbio2@gmail.com

Abstract

Zinc is an essential element for the body; it is involved in many enzymes and has a role in many physiological processes; glucose metabolism stands ahead of them. Also, chromium has been used recently as a food supplement in regime systems, So it's essential to evaluate the effects of these two elements in a diabetic state and evaluate their antidiabetic ability. Seventy male adult mice were used and grouped into seven groups. Group 1: received no treatment. Group 2 received 10mg/kg body weight daily orally of ZnONPs for a month. Group 3 received 1mg/kg body weight for a month daily oral of CrO₃NPs. Group 4: received a single dose of 150mg/kg body weight of alloxan. Group 5 received a single alloxan dose of 150 mg/kg and daily oral 10 mg/kg body weight of ZnONPs for a month. Group 6: received a single alloxan dose of 150 mg/kg and 1mg/kg body weight for a month daily oral Cr₂O₃NPs. Group: received single alloxan dose 150mg/kg and 1mg/kg body weight for month daily oral of Cr₂O₃NPs and 10 mg/kg body weight of ZnONPs for month. Explained that there is a significant decrease in fasting blood glucose and HbA_{1c} and a substantial increase in insulin and C-peptide levels compared with diabetic group in diabetic groups treated with one or both nanoparticle types. Histological results exhibited better diabetic degeneration effects enhancement in all diabetic groups treated with one or both nanoparticle types. In conclusion, ZnONPs and CrO₃NPs exhibit a synergistic effect on diabetes improvement, and they restore the degenerated insulin-producing cells of Langerhans Islets, giving improvement parameters better than they used alone.

DOI: [10.33899/ijvs.2023.138380.2797](https://doi.org/10.33899/ijvs.2023.138380.2797), ©Authors, 2023, College of Veterinary Medicine, University of Mosul.
This is an open access article under the CC BY 4.0 license (<http://creativecommons.org/licenses/by/4.0/>).

Introduction

Diabetes is a clinical metabolic syndrome characterized by high blood insulin levels because of a complete or partial decrease in insulin levels (1). This disease is caused when the pancreas can't perform its function or body cells are insensitive to insulin, making glucose unable to enter body cells (2). There are many complications of diabetes in all body systems, such as neurological, cardiovascular, reproductive, gastrointestinal, urological, ophthalmic,

hematological, and biochemical complications (3). Nanoparticles are tiny particles with sole properties; their preparation could change the matter properties to make them interconnect with cell membranes and organelles (4). Nanoparticles are used in many fields of life: cosmetics, accessories, inks, drugs, etc. They were laden with therapeutic agents to supply the target cell (5). Zinc Oxide nanoparticles were from those bio-nanoparticles, an inorganic chemically active matter ranging from 1 to 100 nm (6). It is known that zinc is an essential element for some

enzymatic reactions, with its structure permitting the proteins to change themselves for their functional form (7). So, zinc is achievable for insulin molecule structure, biosynthesis, secretion, and storage through zinc transporters (8). Studies established that ZnO nanoparticles might lead to cancer through protein and DNA damage as they generate free radicles in skin tissue (9). Other ones stated that some metals participate in the body's glycemic state and disease complication progression; one is zinc (10). Ad of chromium nanoparticles were very important in recovering body antioxidant activity in type II diabetic patients, resulting from increased oxidative stress (11).

Materials and methods

Zinc oxide nanoparticles

Zinc oxide nanoparticles were prepared using stoichiometric quantities of zinc compound $\text{Zn}(\text{NO}_3)_2 \cdot 6\text{H}_2\text{O}$ were weighted and mixed well with ethylen glycol and distilled water. The resulting mixture was shaken by a magnetic stirrer on a hot plate until it reached dry; after autoignition, a fluffy white-yellowish powder was ground, heated, and then collected in clean test tubes. Using a transmission electron microscope characterized nanoparticles, the particles appeared as aggregated hexagonal platelets attached as a chain with 47nm size (12).

Chromium oxide nanoparticles

Chromium dioxide nanoparticles were synthesized by adding 10ml of potassium dichromate 0.2 M solution to 5ml cetyl-trimethyl ammonium chloride 0.96g/ml with 50ml of trisodium citrate at a concentration of 10mM. The vessel reaction was floodlit to lamp halogen under stirring for 3 hours (13). The solution color was changed from brownish-yellow to green, which showed Cr_2O_3 nanoparticles being formed (14). Seventy adult, healthy, male albino mice were used there, weighing 20 to 25gm, aged between 12 to 15 weeks, brought from Babylon University animal house. Mice were habituated for one month before the experiment, ratified by the Institutional- Animal- Ethical- Committee, and kept under controlled conditions of light/ dark period and

room temperature. Randomly, animals were divided into seven groups: Group 1 was given distilled water. Group 2 received 10mg/kg body weight daily orally of ZnONPs for a month. Group 3 received 1mg/kg body weight for a daily oral of Cr_2O_3 NPs for a month. Group 4 received a 150mg/kg body weight of alloxan (15). Group 5 received a single alloxan dose of 150 mg/kg and daily oral 10 mg/kg body weight of ZnONPs for a month. Group 6: received a single alloxan dose of 150 mg/kg and 1mg/kg body weight for a month daily oral Cr_2O_3 NPs. Group 7: received single alloxan dose 150mg/kg and 1mg/kg body weight for month daily oral of Cr_2O_3 NPs and 10 mg/kg body weight of ZnONPs for month. Animals treated with alloxan are respected as diabetic when their fasting blood glucose is more than 200 Mg/dl after seven days of alloxan injection. After one month, animals were sacrificed, and blood was withdrawn for estimation of serum for biochemical tests. Pancreases was removed from animals and fixed in buffered saline formaldehyde 10%, and processed histologically as stained with hematoxylin-eosin stain and studying pancreatic morphology (16). Glucose and HbA1c levels were estimated by spectrophotometer (17). At the same time, the ELIZA kit is used to assess insulin (18), and C-peptide levels (19).

Statistical analysis

SPSS used and data expressed as mean \pm standard error and ANOVA compared differences at $P < 0.05$ (20).

Results

Results explained a significant increase in glucose and HbA1c levels and a significant decrease in blood insulin and C-peptide levels in the group of diabetic mice when compared with the control group. Also, there was a significant decrease in levels of glucose and HbA1c and a significant increase in insulin and C-peptide levels in the zinc oxide nanoparticles group and chromium oxide nanoparticles group compared with controls. Compared with the control group, the best result was the cooperation between the two nanoparticles types for decreasing blood glucose and HbA1c with increasing insulin levels (Table 1).

Table 1: levels of glucose, Hemoglobin A1 insulin, and C- peptide protein in the control and experimental mice groups

Groups	Mean \pm SE			
	Glucose (Mg/dl)	HbA1c (%)	Insulin ($\mu\text{IU}/\text{ML}$)	C-peptide (ng/ml)
Control	75.21 \pm 1.2 ^a	5.76 \pm 0.3 ^a	48.79 \pm 0.44 ^a	0.72 \pm 0.18 ^a
ZnONPs	74.57 \pm 0.9 ^c	5.41 \pm 0.6 ^c	47.33 \pm 0.8 ^c	0.74 \pm 0.07 ^c
CrO_3 NPs	75.69 \pm 1.6 ^c	5.30 \pm 0.4 ^c	48.49 \pm 0.1 ^c	0.73 \pm 0.01 ^c
Diabetic	277.69 \pm 1.5 ^b	9.65 \pm 0.1 ^b	24.3 \pm 0.52 ^b	0.24 \pm 0.03 ^b
Diabetic+ ZnONPs	98.66 \pm 0.7 ^d	8.12 \pm 0.2 ^d	40.79 \pm 0.36 ^d	0.58 \pm 0.09 ^d
Diabetic+ CrO_3 NPs	112.45 \pm 1.05 ^a	8.43 \pm 0.12 ^a	41.11 \pm 0.7 ^a	0.57 \pm 0.09 ^a
Diabetic+ ZnONPs+ CrO_3 NPs	91.87 \pm 0.9 ^a	6.31 \pm 0.3 ^a	43.08 \pm 1.02 ^a	0.69 \pm 0.02 ^a
LSD	4.64	0.72	1.34	0.031

Different vertical letters refer to the significance at $P < 0.05$.

Histopathological results

Cross section of the pancreas from control group mice exhibiting normal pancreatic architecture (Figure 1). Cross section of the pancreas from alloxan-receiving mice Exhibiting necrosis and degeneration of islets with telangiectasis (Figure 2). Cross section of the pancreas from ZnONPs receiving mice exhibiting normal histological organization (Figure 3). Cross section of the pancreas from CrONPs receiving mice Exhibiting normal histological organization (Figure 4). Cross section of the pancreas from

diabetic mice treated with ZnONPs Exhibiting normal pancreatic islets with cellular vacuolation and slight necrosis with mild leukocyte infiltration and little congestion (Figure 5). Cross section of the pancreas from diabetic mice treated with CrONPs Exhibiting normal pancreatic islets with cell vacuolation and slight necrosis (Figure 6). Cross section of the pancreas from diabetic mice treated with ZnONPs and CrONPs, Exhibiting normal pancreatic islets with cellular vacuolation and slight necrosis with mild leukocyte infiltration and little congestion (Figure 7).

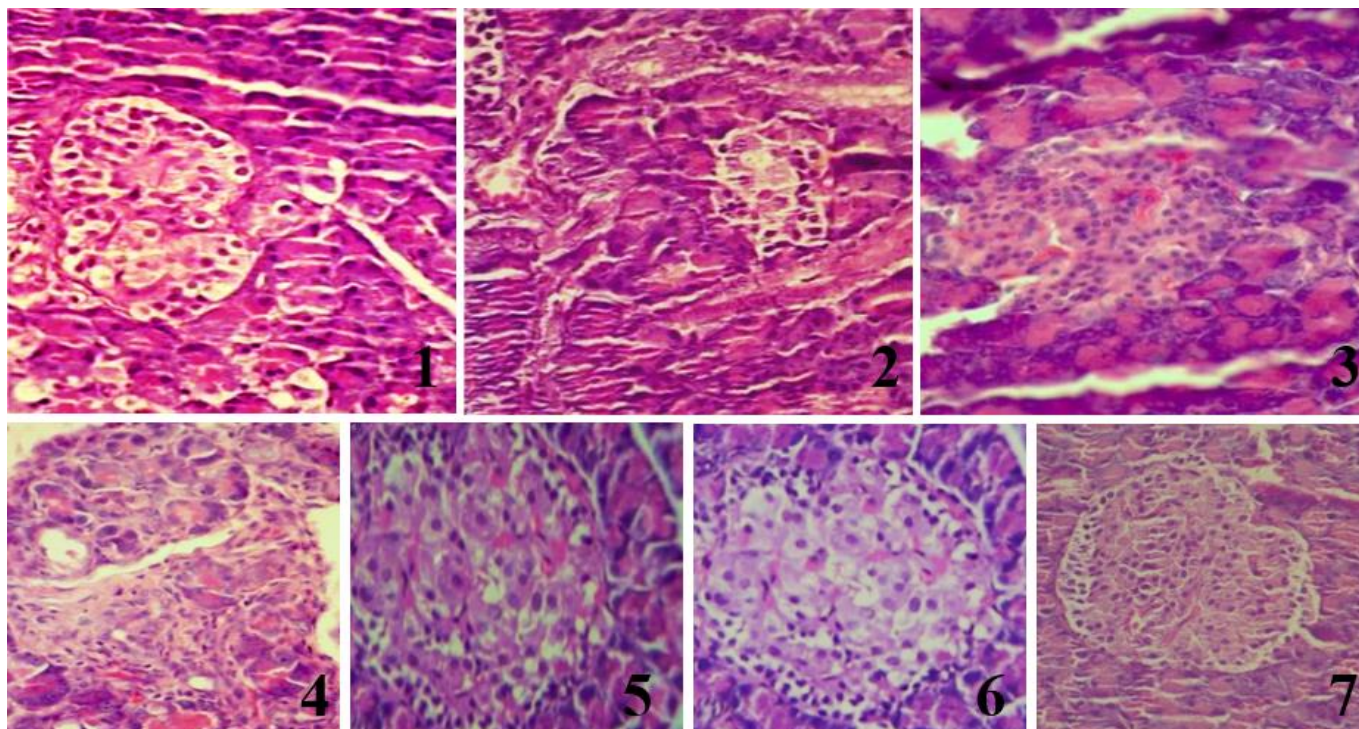


Figure 1: Cross section of the pancreas from control group mice exhibiting normal pancreatic architecture. Figure 2: Cross section of the pancreas from alloxan-receiving mice Exhibiting necrosis and degeneration of islets with telangiectasis. Figure 3: Cross section of the pancreas from ZnONPs receiving mice Exhibiting normal histological organization. Figure 4: Cross section of the pancreas from CrONPs receiving mice Exhibiting normal histological organization. Figure 5: Cross section of the pancreas from diabetic mice treated with ZnONPs Exhibiting normal pancreatic islets with cellular vacuolation and slight necrosis with mild leukocyte infiltration and little congestion. Figure 6: Cross section of the pancreas from diabetic mice treated with CrONPs Exhibiting normal pancreatic islets with cell vacuolation and slight necrosis. Figure 7: Cross section of the pancreas from diabetic mice treated with ZnONPs and CrONPs, Exhibiting normal pancreatic islets with cellular vacuolation and slight necrosis with mild leukocyte infiltration and little congestion. H&E, 400X.

Discussion

It is essential to find alternative methods for improving and managing diabetes and its complications for reducing or avoiding drug side effects (21). One of those methods is the use of nanoparticles as they were very tiny sized, and their biological features made them suitable for use in medical applications (22). Based on the present results, alloxan-

induced diabetes is caused by an increase in glucose and HbA1c levels and a decrease in insulin hormone (23). It is known that alloxan destroys pancreatic B cells (24).

Blood glucose levels with glycated hemoglobin and insulin were respected as markers for diabetes and its progression (25). Their disturbances reflect the pancreatic dysfunction and the C-peptide that refers to the B cell function (26). To have different mechanisms in regulating

gene expression of the factors involved in glucose homeostasis (27). Combining the two nanoparticles' types, zinc oxide and chromium oxide, and alone administration exhibits a decrease in glucose and HbA1c levels and an increase in insulin hormone, proposing the antidiabetic activity of these nanoparticles' types (28). Zinc manages glucose metabolism by augmentation glycogenesis in the liver via insulin signaling (29). Also, chromium oxide nanoparticles can increase the antioxidant capacity of cells resulting from diabetes by increasing the oxidative stress resulting from diabetes (30).

Moreover, zinc oxide nanoparticles' antidiabetic ability might have resulted from its regeneration effect on insulin-secreting cells of the pancreas, causing an increase in insulin levels supported by our histological results and the lowering in C-peptide levels that refer to the restoration of pancreatic B cells (31), as Zinc oxide nanoparticles regenerate Langerhans's Islets and B cell function (32). In the same way, Chromium oxide nanoparticles could conjugate with insulin receptors and increase insulin levels through its induction of substrate receptor phosphorylation, which plays an essential task in signal transmission such as PI3K, which is critical in insulin function (33). This refers to the improved animal's glycemic state by the two nanoparticle combinations (34). Zinc oxide nanoparticles improved the destructed mass of B cells in diabetic mice, proposing their ameliorative effect on pancreatic tissue, especially Langerhans's Islets, and increased the degenerated B cells' restoration. These parameters were shown to be more improved in the group of nanoparticles combination (35).

Conclusion

ZnONPs and CrO₃NPs exhibit synergistic cooperation on diabetes improvement, restoring the degenerated insulin-producing cells of Langerhans Islets.

References

- Piero MN, Nzaro GM, Njagi JM. Diabetes mellitus-a devastating metabolic disorder. *Asian J Biomed Pharm Sci*. 2015;4(40):1. DOI: [10.15272/ajbps.v4i40.645](https://doi.org/10.15272/ajbps.v4i40.645)
- Satyanarayana T, Sarita T, Balaji M, Ramesh A, Boini MK. Antihyperglycemic and hypoglycemic effect of *Thespesia populnea* fruit in normal and alloxan-induced diabetes in rabbits. *Saudi Pharma J*. 2005;12(2/3):107-11.
- Wahba NS, Shaban SF, Kattaia AA, Kandeel SA. Efficacy of zinc oxide nanoparticles in attenuating pancreatic damage in a rat model of streptozotocin-induced diabetes. *Ultrastruct Pathol*. 2016;40(6):358-73. DOI: [10.1080/01913123.2016.1246499](https://doi.org/10.1080/01913123.2016.1246499)
- Buzea C, Pacheco II, Robbie K. Nanomaterials and nanoparticles: Sources and toxicity. *Biointerphases*. 2007;2(4):MR17-71. DOI: [10.1116/1.2815690](https://doi.org/10.1116/1.2815690)
- Mishra PK, Mishra H, Ekielski A, Talegaonkar S, Vaidya B. Zinc oxide nanoparticles: A promising nanomaterial for biomedical applications. *Drug Discov Today*. 2017;22(12):1825-34. DOI: [10.1016/j.drudis.2017.08.006](https://doi.org/10.1016/j.drudis.2017.08.006)
- Gurr JR, Wang AS, Chen CH, Jan KY. Ultrafine titanium dioxide particles in the absence of photoactivation can induce oxidative damage to human bronchial epithelial cells. *Toxicol*. 2005;213(1-2):66-73. DOI: [10.1016/j.tox.2005.05.007](https://doi.org/10.1016/j.tox.2005.05.007)
- Berenjian A, Sharifi SD, Mohammadi-Sangcheshmeh A, Ghazanfari S. Effect of chromium nanoparticles on physiological stress induced by exogenous dexamethasone in Japanese quails. *Biol Trace Elem Res*. 2018;184:474-81. DOI: [10.1007/s12011-017-1192-y](https://doi.org/10.1007/s12011-017-1192-y)
- Bancroft JD, Gamble M. Theory and practice of histological techniques. UK: Elsevier Health Sciences; 2008.
- AL-Murshidi MH. Histological study of testis tissue of male golden hamster (*Mesocricetus auratus*) in different time points of Diabetes. *Afr Health Res Org*. 2019;22(4):49-54. DOI: [10.36295/asro.2019.22046](https://doi.org/10.36295/asro.2019.22046)
- Abed-Alhussain Alyassery AM, Hasan Al-Murshidi MM. Effects of silver nanoparticles on the histology of testis and some accessory sex glands of male albino mice. *Biochem Cell Arch*. 2021;21. (available at)
- Nathan DM, Singer DE, Hurxthal K, Goodson JD. The clinical information value of the glycosylated hemoglobin assay. *N Engl J Med*. 1984;310(6):341-6. DOI: [10.1056/nejm198402093100602](https://doi.org/10.1056/nejm198402093100602)
- Vikram A, Jena G, Ramarao P. Insulin-resistance reduces botulinum neurotoxin-type A induced prostatic atrophy and apoptosis in rats. *Eur J Pharmacol*. 2011;650(1):356-63. DOI: [10.1016/j.ejphar.2010.09.066](https://doi.org/10.1016/j.ejphar.2010.09.066)
- O'Rahilly S, Moller DE. Mutant insulin receptors in syndromes of insulin resistance. *Clin Endocrinol*. 1992;36(2):121-32. DOI: [10.1111/j.1365-2265.1992.tb00945.x](https://doi.org/10.1111/j.1365-2265.1992.tb00945.x)
- Thompson KH, Lichter J, LeBel C, Scaife MC, McNeill JH, Orvig C. Vanadium treatment of type 2 diabetes: a view to the future. *J Inorg Biochem*. 2009;103(4):554-8. DOI: [10.1016/j.jinorgbio.2008.12.003](https://doi.org/10.1016/j.jinorgbio.2008.12.003)
- Latner A. Clinical Biochemistry. USA: Saunders; 1957.
- Umrani RD, Paknikar KM. Zinc oxide nanoparticles show antidiabetic activity in streptozotocin-induced Type 1 and 2 diabetic rats. *Nanomed*. 2014;9(1):89-104. DOI: [10.2217/nmm.12.205](https://doi.org/10.2217/nmm.12.205)
- Alkaladi A, Abdelazim AM, Afifi M. Antidiabetic activity of zinc oxide and silver nanoparticles on streptozotocin-induced diabetic rats. *Int J Mol Sci*. 2014;15(2):2015-23. DOI: [10.3390/ijms15022015](https://doi.org/10.3390/ijms15022015)
- Jansen J, Karges W, Rink L. Zinc and diabetes—clinical links and molecular mechanisms. *J Nutr Biochem*. 2009;20(6):399-417. DOI: [10.1016/j.jnutbio.2009.01.009](https://doi.org/10.1016/j.jnutbio.2009.01.009)
- de Lima Ávila D, de Araújo GR, Silva M, de Amorim Miranda PH, Diniz MF, Pedrosa ML, Silva ME, de Lima WG, Costa DC. Vildagliptin ameliorates oxidative stress and pancreatic beta cell destruction in type 1 diabetic rats. *Arch Med Res*. 2013;44(3):194-202. DOI: [10.1016/j.arcmed.2013.03.004](https://doi.org/10.1016/j.arcmed.2013.03.004)
- El-Megharbel SM. Synthesis, characterization and antidiabetic activity of chromium (III) metformin complex. *J Microb Biochem Technol*. 2015;7:65-75. DOI: [10.4172/1948-5948.1000184](https://doi.org/10.4172/1948-5948.1000184)
- Yih TC, Al-Fandi M. Engineered nanoparticles as precise drug delivery systems. *J Cell Biochem*. 2006;97(6):1184-90. DOI: [10.1002/jcb.20796](https://doi.org/10.1002/jcb.20796)
- Hirst SM, Karakoti AS, Tyler RD, Sriranganathan N, Seal S, Reilly CM. Anti-inflammatory properties of cerium oxide nanoparticles. *Small*. 2009;5(24):2848-56. DOI: [10.1002/smll.200901048](https://doi.org/10.1002/smll.200901048)
- Rautio J, Perämäki P, Honkamo J, Jantunen H. Effect of synthesis method variables on particle size in the preparation of homogeneous doped nano ZnO material. *Microchem J*. 2009;91(2):272-6. DOI: [10.1016/j.microc.2008.12.007](https://doi.org/10.1016/j.microc.2008.12.007)
- Attia YA, Attia SY, Essa R, Mohamed S. Photosynthesis of chromium oxide/reduced graphene oxide nanocomposites and its application in water desalination and purification. *Nanosci Nanotechnol-Asia*. 2020;10(5):719-25. DOI: [10.2174/2210681209666190627155956](https://doi.org/10.2174/2210681209666190627155956)
- Wahba NS, Shaban SF, Kattaia AA, Kandeel SA. Efficacy of zinc oxide nanoparticles in attenuating pancreatic damage in a rat model of streptozotocin-induced diabetes. *Ultrastruct Pathol*. 2016;40(6):358-73. DOI: [10.1080/01913123.2016.1246499](https://doi.org/10.1080/01913123.2016.1246499)
- Shanker K, Mohan GK, Mayasa V, Pravallika L. Antihyperglycemic and anti-hyperlipidemic effect of biologically synthesized silver nanoparticles and G. sylvestre extract on streptozotocin induced diabetic rats-an in vivo approach. *Mater Lett*. 2017;195:240-4. DOI: [10.1016/j.matlet.2017.02.137](https://doi.org/10.1016/j.matlet.2017.02.137)
- Shanker K, Naradala J, Mohan GK, Kumar GS, Pravallika PL. A sub-acute oral toxicity analysis and comparative in vivo anti-diabetic

- activity of zinc oxide, cerium oxide, silver nanoparticles, and *Momordica charantia* in streptozotocin-induced diabetic Wistar rats. RSC Adv. 2017;7(59):37158-67. DOI: [10.1039/c7ra05693a](https://doi.org/10.1039/c7ra05693a)
28. Alkazazz FF, Taher ZA. A Review on nanoparticles as a promising approach to improving diabetes mellitus. J Phs Conf Ser. 2021;1853(1):012056. DOI: [10.1088/1742-6596/1853/1/012056](https://doi.org/10.1088/1742-6596/1853/1/012056)
 29. Ashrafizadeh H, Abtahi SR, Oroojan AA. Trace element nanoparticles improved diabetes mellitus; A brief report. Diabetes Metab Syndr: Clin Res Rev. 2020;14(4):443-5. DOI: [10.1016/j.dsx.2020.04.026](https://doi.org/10.1016/j.dsx.2020.04.026)
 30. Siddiqui SA, Or Rashid MM, Uddin MG, Robel FN, Hossain MS, Haque MA, Jakaria M. Biological efficacy of zinc oxide nanoparticles against diabetes: A preliminary study conducted in mice. Biosci Rep. 2020;40(4):BSR20193972. DOI: [10.1042/bsr20193972](https://doi.org/10.1042/bsr20193972)
 31. AL-Shemmari IM, Kassim Altaee RA mahdi, Hassan AH. Evaluation of antidiabetic and antihyperlipidemic activity of Kefir in alloxan induced diabetes mellitus rat. Sci J Med Res. 2018;02(6):83-6. DOI: [10.37623/sjmr.2018.2606](https://doi.org/10.37623/sjmr.2018.2606)
 32. Ebelt H, Peschke D, Brömme HJ, Mörke W, Blume R, Peschke E. Influence of melatonin on free radical-induced changes in rat pancreatic beta-cells in vitro. J Pineal Res. 2000;28(2):65-72. DOI: [10.1034/j.1600-079x.2001.280201.x](https://doi.org/10.1034/j.1600-079x.2001.280201.x)
 33. Akhtar MJ, Ahamed M, Kumar S, Khan MM, Ahmad J, Alrokayan SA. Zinc oxide nanoparticles selectively induce apoptosis in human cancer cells through reactive oxygen species. Int J Nanomed. 2012;845-57. DOI: [10.2147/ijn.s29129](https://doi.org/10.2147/ijn.s29129)
 34. Dehkordi RA, Moradi H. Stereological estimation and morphological assessment of the endocrine pancreatic components in relation to sex in hen. Vet Res Forum. 2015;6(1):49. ([available at](#))
 35. Amiri A, Dehkordi RA, Heidarnajad MS, Dehkordi MJ. Effect of the zinc oxide nanoparticles and thiamine for the management of diabetes in alloxan-induced mice: a stereological and biochemical study. Biol Trace Elem Res. 2018;181:258-64. DOI: [10.1007/s12011-017-1035-x](https://doi.org/10.1007/s12011-017-1035-x)

تقييم النشاط المضاد لمرض السكر لجسيمات أوكسيد الزنك وأوكسيد الكروم النانوية بمفردها أو مجتمعة على البنكرياس في داء السكري الناجم عن الألوكسان في ذكور الفئران البيض

منار محمد المرشدي^١، إسرائ عدنان كاظم^٢، حسين سعيد المفرجي^١ و هالة محي السيلي^٣

^١ فرع الأحياء، كلية العلوم للبنات، جامعة بابل، بابل، ^٢ فرع الأحياء، كلية التربية للعلوم الصرفة، جامعة كربلاء، كربلاء، ^٣ قسم علوم الحياة، كلية العلوم، جامعة بابل، بابل، العراق

الخلاصة

يعتبر الزنك عنصراً مهماً للجسم فهو يدخل في تركيب العديد من الأنزيمات وله دوراً في العديد من العمليات الفسيولوجية التي يعد أيضاً الكالسيوم في مقدمتها. كما وإن عنصر الكروم أصبح يستعمل حديثاً كمكمل غذائي في أنظمة الريجيم. لذا فمن المهم تقدير تأثيرات هذين العنصرين معاً في حالة مرض السكري وتقدير فعاليتيهما الخافضة للسكر. تم استعمال ٧٠ حيوان من ذكور الفئران تم تقسيمها إلى سبع مجموعات، المجموعة الأولى لم تجرّع بشيء. المجموعة الثانية جرعت ١٠ ملغم/كغم من وزن الجسم يومياً من جسيمات أوكسيد الزنك النانوية لمدة شهر. المجموعة الثالثة جرعت ١ ملغم/كغم من وزن الجسم بجسيمات الكروميوم النانوية لمدة شهر، المجموعة الرابعة جرعت بجرعة مفردة من الألوكسان ١٥٠ ملغم/كغم من وزن الجسم. المجموعة الخامسة جرعت بجرعة مفردة من الألوكسان و ١٠ ملغم/كغم من وزن الجسم من جسيمات الزنك النانوية يومياً ولمدة شهر. المجموعة السادسة جرعت بجرعة مفردة من الألوكسان و ١ ملغم/كغم من وزن الجسم من جسيمات الكروميوم النانوية يومياً ولمدة شهر. المجموعة السابعة جرعت بجرعة مفردة من الألوكسان و ١٠ ملغم/كغم من وزن الجسم من جسيمات الزنك النانوية و ١ ملغم/كغم من وزن الجسم من جسيمات الكروميوم النانوية ولمدة شهر. أوضحت النتائج وجود انخفاض معنوي في مستوى السكر الصيامي والهيموغلوبين السكري وزيادة معنوية في مستوى هرمون الأنسولين والبيبتيد-سي مقارنة بمجموعة السكري في مجموعة السكري المجرعة بأحد أو كلا الجسيمات النانوية. أوضحت نتائج الدراسة النسيجية تأثيرات تعزيزية جيدة في كل مجاميع السكري المجرعة بأحد وكلا النوعين من الجسيمات النانوية. نستنتج من الدراسة الحالية أن جسيمات الزنك والكروميوم النانوية أصبح لها تأثيراً تآزرياً تعزيزياً في تحسين التأثيرات السلبية لمرض السكري واستعادة خلايا جزيرات لانكرهانز المضمحلة مقارنة باستعمال كل منهما على حده.