

## Studying an outbreak of inclusion body hepatitis in broilers in Nineveh governorate, Iraq

M.T. Jarjees<sup>1</sup>, Dh. M. Jwher<sup>1</sup> and A.M. Shareef<sup>1</sup>

Department of Veterinary Public Health, College of Veterinary Medicine, University of Mosul, Mosul, Iraq

### Article information

#### Article history:

Received October 19, 2021  
Accepted February 7, 2022  
Available online June 10, 2022

#### Keywords:

Inclusion body hepatitis  
Broiler  
PCR  
Nineveh

#### Correspondence:

Dh. M. Jwher  
[diaataher@uomosul.edu.iq](mailto:diaataher@uomosul.edu.iq)

### Abstract

The aim of this study was to provide field outbreaks data with FAdVs in Nineveh governorate to emphasize the importance of the disease due to high mortality and production losses. A total of 729,500 broilers collected from 64 flocks at 14 different locations in Nineveh governorate during the second half of 2020. were included in this study. Histopathological changes of the liver in infected birds have been studied. Molecular identification of FAdV was accomplished by DNA extraction from liver samples using DNeasy Tissue Kit. Results revealed that there were 51892 mortalities representing 7.11%. It was noted that the broiler flocks were infected during their 2nd-6th weeks of age, being the highest in the 5th week of age. Decreased mortality was detected from July to December. being 11.3, 7.91, 7.08, 6.38, 5.94 and 4.95%, respectively. Microscopical examination of the liver manifested the pathognomonic presence of eosinophilic intranuclear inclusion bodies related to the disease. PCR findings revealed positive results of FAdVs. It could be concluded that the environmental stress and immunosuppressive agents could contribute to the percentage and duration of mortalities in broiler flocks.

DOI: [10.33899/ijvs.2022.131932.2024](https://doi.org/10.33899/ijvs.2022.131932.2024), ©Authors, 2022, College of Veterinary Medicine, University of Mosul.  
This is an open access article under the CC BY 4.0 license (<http://creativecommons.org/licenses/by/4.0/>).

### Introduction

Inclusion Body Hepatitis (IBH) disease was reported for the first time in chickens in 1963 and the causative adenovirus was isolated and verified ten years later (1). The disease was world-wide recorded in many countries as emerging fowl adenovirus (FAdV)-associated diseases and as sporadic episodes causing economic losses affecting broiler industry (2). FAdV-associated diseases are manifested as hepatitis-hydropericardium syndrome, inclusion body hepatitis and gizzard erosion prevailing in several parts of the seven continents (3). However, IBH is related to FAdV2,-8A,-8B AND 11. Adenoviruses were identified from intact and diseased fowls, in addition to un-inoculated or inoculated eggs (3). IBH can be transmitted vertically and horizontally (4). Horizontal transmission due to contamination may occur mechanically or by oral-fecal route (5). IBH normally occurs in broilers at 3-7 weeks of

age or even from day 7 up to week 28 of age (6). Serologically, the virus can be detected in healthy and diseased broilers with short clinical course 4-5 days of 1-20% or 40% (7) and may reach up to 80% (8) of 2-7 weeks in the presence of other immunosuppressive factors (9). The pathogenesis of IBH is influenced by environment factors, toxins, pathogenicity of the virus and immune status of the affected birds (2,10). IBH was reported in Iraq during 1979 in broiler chicks of 4- 6-weeks old with mortality rate of 1% (11). In non-experimental cases, the disease is distinguished by abrupt occurrence of death ranging from two to 40 percent in chickens. High death rate occurs when the affected birds are less than three weeks' old which is associated with the virulence of the virus, immunity of the chicks and concomitant other different diseases (6). However, peak of mortality occurs within 3-4 days and declines within 9-14 days (3,12).

In view of the recent increase in the incidence of the disease in the poultry farms, so the study aimed to provide a clear picture of field outbreaks with FAdVs in Nineveh governorate to emphasize the importance of the disease due to high mortality and production losses.

## Materials and methods

Data was collected from 729,500 broilers constituted 64 flocks from 14 different locations in Nineveh governorate (Kuba, Rashidia, Abasia, Bazwaya, Kokjaly, Hamdania, Rabea, Talafar, bartella, Shalalat, Karamles, Kabery, Basakhra, Bashbata) (Figure 1). Broilers at 2-6-weeks-old with a history of sudden rise in mortalities, lethargy, ruffled feathers, inappetence, huddling, smothering, drowsiness, stoop, pale or icteric, were reported. The birds were kept in half-opened houses, raised on wood shavings or carton used as litter, equipped with central heaters or gas heaters, with different types of cooling systems and ventilators to prepare the favorable surroundings. Birds were fed a conventional corn-soybean meal starter feed. Feed and water were supplied *ad libitum*. All chickens were vaccinated by spray method at the time of arrival to the farm against Newcastle (ND), infectious bronchitis (IBV) vaccines and injected with Inactivated oil adjuvant mixed Avian Influenza (AI) and (ND) vaccines. In the subsequent weeks, birds vaccinated against ND using lasota vaccine. Infectious bursal disease (IBDV) vaccine was given at 7 or 14 days of age. No birds were vaccinated against IBH or chicken anemia virus (CAV).

Necropsy Examination affected birds necropsied for examination of the pathological changes in liver, briefly the samples were fixed in 10% buffered formalin for 72 hours, dehydrated in ascending concentrations of ethyl alcohol, cleared in xylene and embedded in paraffin wax, and sectioned at 4-6  $\mu$ m thickness, later slides were stained using hematoxylin and eosin (H&E) (13).

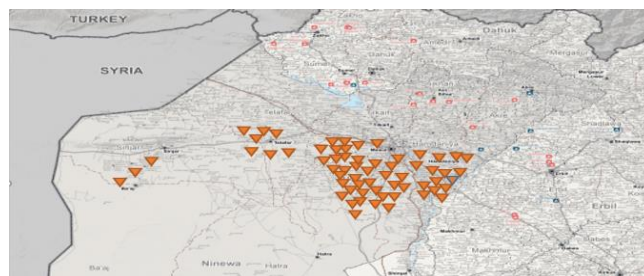


Figure 1: Distribution of broiler flocks in Nineveh governorate subjected to investigation.

## DNA extraction

Viral DNA was extracted from infected liver samples using DNeasy Tissue Kit (GENEAID Corporation, Taiwan) as per the manufacturer's protocol. For PCR protocol, 4 $\mu$ l of DNA was amplified using 10 pmol of each primer with master mix 2X and the final volume of reaction is 20  $\mu$ l. Table 1 showed the PCR Primers used for identification of Hexon gene of fowl adenovirus isolated from infected liver sample.

Table 1: PCR Primers used for identification of Hexon gene of fowl adenovirus isolated from infected liver sample

Gene	Primers	Sequence (5'-3')	Nucleotide positions	Band size	Reference
Hexon A,B	Forward	CAA RTT CAG RCA GAC GGT	144-161	890 bp	(12)
	Reverse	TAG TGA TGM CGS GAC ATC AT	1041-1021		

## Amplification of DNA of liver sample

The gene encoding the Hexon protein of fowl adenovirus group-I was chosen for the selection of primers (12). The amplification was carried out in thermocycler according to a specific program (Table 2). The PCR product was separated in agarose gel electrophoresis 2%.

Table 2: PCR reaction program for identification of Hexon gene of fowl adenovirus isolated from infected liver samples

Stage	°C	Time	Cycle
Initial denaturation	95°C	5 min.	1
denaturation	95°C	45 second	
Annealing	54°C	1 min.	35
Extension	72°C	1 min.	
Final extension	72°C	7 min.	1

## Results

### Clinical findings

The morbidity reached 30% and the mortalities ranged from four to 11%, reflecting the wide spread of IBH outbreaks in Nineveh governorate (Table 3). The age of IBH infection revealed that the disease affects broilers from the second to 6 weeks of age, (principally 3-5 weeks), with a total mean percentage of mortalities of 7.11% (Table 3, Figures 2 and 3). The severity of mortality during IBH outbreaks peaks within 3-5 days of infection duration (Figure 4). Through the period of IBH investigation (July to December 2020), There was a monthly decreasing in both the duration of IBH infection from 7.75 to 4.15 days (Figure 5) and the percentage of mortalities from 11.3 to 4.95% (Figure 6).

Table 3: Monthly distribution of IBH infected broiler flocks, their number, location, age, and percentages of mortalities in Nineveh governorate

Months	Parameters investigated					
	Number of broiler flocks	Locations of broiler flocks	Age (weeks/No. flocks infected)	Total No of broilers in farms	Total No of mortalities	% mortalities
July	8	Ras. Aba. Ham. Rab.* Kub. Shal. Kok. Kab.	(3w/1),(4w/4), (5w/3)(6w/1)	111000	12544	11.30%
August	12	Basa. Bash. Ham. Kar. Tala. Aba. Kok.	(3w/2),(4w/3), (5w/6)	136400	10789	7.91%
September	11	Ras.,Kub.,Ham.,Kok., Aba.,Sha., Baz.	(3w/2),(4w/5), (5w/5)	127200	9005	7.08%
October	11	Baz.,Tal.,Ras.,Ham., Kub.,Baz., Kok.	(3w/3),(4w/5), (5w/6)	113350	7231	6.38%
November	9	Tal.,Ham.,Ras.,Kok., Aba.,Baz., Kub.	(3w/2),(4w/5), (5w/3)	105850	6289	5.94%
December	13	Rab, Ham, Kok. Tal. Aba.	(2w/2),(3w/2), (4w/1),(5w/3)	138100	6836	4.95%

\*= Aba= Abasia, bar= bartella, Basa= Basakhra, Bash= Bashbata, Baz= Bazwaya, Ham= Hamdania, Kab= Kabery, Kar= Karamles, Kok= Kokjaly, Kub= Kuba, Rab= Rabea, Ras= Rashidia, Sha= Shalalat, Tal= Talafar.

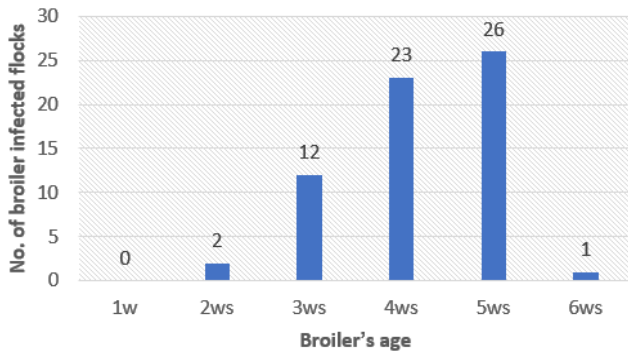


Figure 2: Percentage of broiler infected with IBN according to their age.

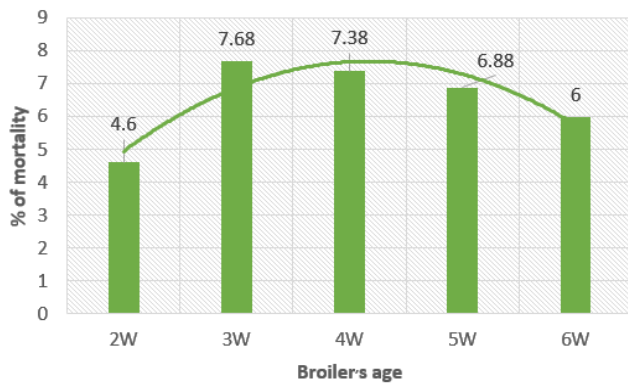


Figure 3: Percentage of mortality during IBH outbreaks according to broilers age.

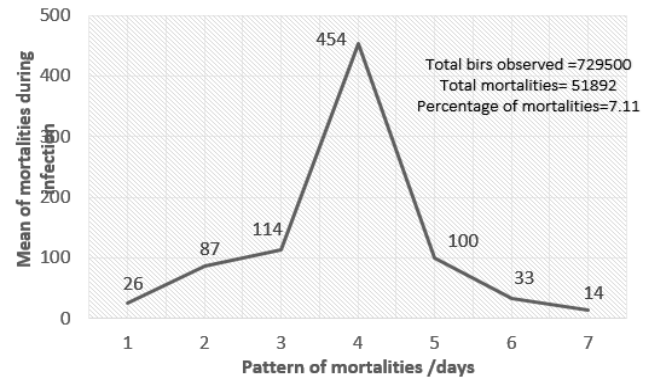


Figure 4: peak of mortality during IBH outbreaks within week of infection.

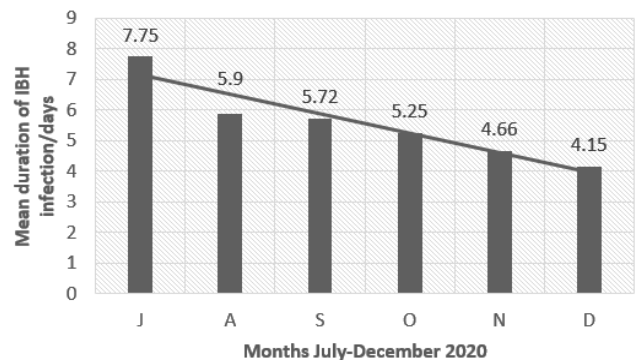


Figure 5: Monthly decreasing in IBH days of infection from July-December 2020.



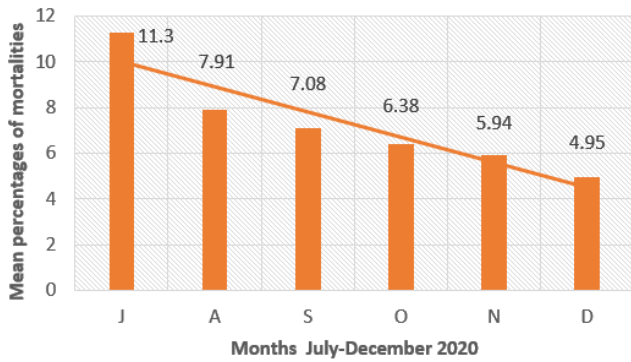


Figure 6: Monthly decreasing in IBH mortality percentage of from July-December 2020.

**Clinical findings**

The investigated birds showed lethargy, ruffled feathers, inappetence, huddling, smothering drowsiness, pale or icteric, with yellowish diarrhea, were the major observed clinical signs of two to 6 weeks’ broiler chicks.

**Necropsy findings**

The main lesions during post-mortem examination in cases of IBH seen in the liver as severe hepatitis, enlarged, friable, with a marble-like pattern and necrotic foci Multifocal, pale, pinpoint lesions, in addition to hepatomegaly and pinpoint hemorrhages and yellowish discoloration of the skin, carcass and fatty tissues (Figure 7). In the histologic point of view, broad areas of cellular degeneration and diffuse, generalized hepatic necrosis, lymphoid infiltration and inclusion bodies were noticed. The necropsied field cases revealed the presence of eosinophilic inclusion bodies of variable appearance in livers infected with IBH (Figure 8).

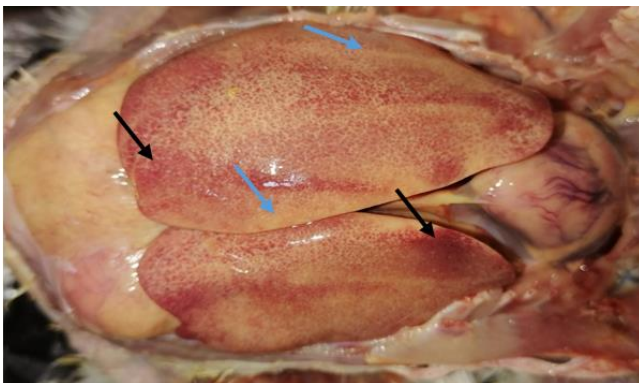


Figure 7: Liver of a broiler infected with IBH showing severe pinpoint hemorrhage (black arrow) with necrotic foci (blue arrow).

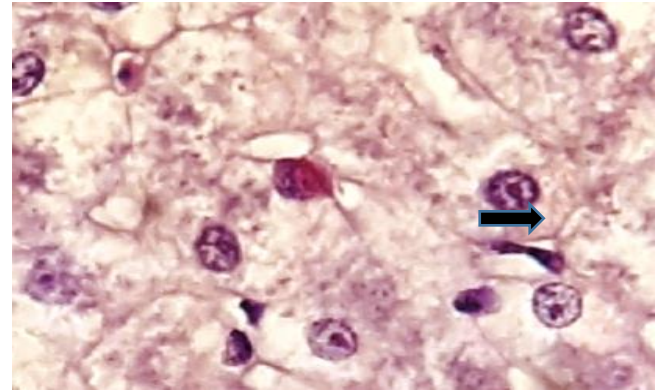


Figure 8: photomicrograph of liver of IBH infection shows basophilic intranuclear inclusion bodies in hepatocyte (arrow). Stain, Magnification power.

**Molecular finding**

PCR product 890 bp band was recovered in livers of broilers infected with IBH (Figure 9).

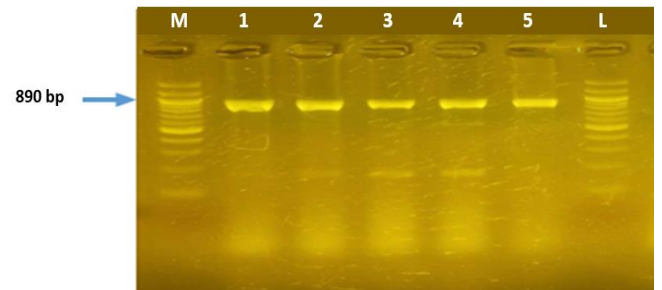


Figure 9: PCR product band 890 bp of Hexon gene for virus samples.

**Discussion**

In the previous twenty years, a pandemic of IBH was confirmed in various worldwide referring to the of the disease (14). In Nineveh governorate, farmers are not well applying rigorous biosecurity in their farms, which may participate in expanding existence of FAdV-allied diseases in different areas of the governorate, worsening the condition because fowl adenoviruses are resistant to different antiseptic, high temperature and pH alterations (3). The growing knowledge of FAdVs as fundamental causative factor in IBH infection, indicating the significance of FAdVs diseases in various locations of the world (15). The sporadic occurrence of IBH in different localities in Nineveh governorate indicate the possible presence of immunosuppressive viruses (15,16) and mycotoxins (17).

Subsequently, works from Oceania (Australia, New Zealand), north America (Canada) and east Asia (Japan) verified IBH occurrence without being apt to other

debilitating factors, promoting the role of FAdVs as original cause of the disease (18). On the other hand, a Canadian study established no significant connection between broilers being artificially subjected to FAdVs and co-infected with CAV or IBDV (19). The low immunity of young broiler chicks expedites the infection with avian adenovirus, confirming the experimental infection designed by Lim *et al.* (20) who gave FAdV-8b strain given *per os* to one-day old chicks (20). Comparatively, SPF layers exposed under similar conditions manifested 20% mortality, confirming the circumstance noticed from the field and referring the evidence that broilers were more sensitive and easily prone to infection (4). Broiler chickens affected by IBH means that meat type poultry are crucial element influencing the outcome of the disease (21),

In the current work, high mortalities in broilers occurs within the 3<sup>rd</sup> and the 4<sup>th</sup> days of infection and began mainly at the age of 3 weeks up to 6<sup>th</sup> weeks of age. Resembling to some extent those reported by (22). The tendency of increasing mortalities between 3 to five days can be explained by the virus colonizes the intestinal epithelium at 12 hours post infection and detected in the blood as early as 24 hours post infection (23), and so the virus exists in its definitive organs *i.e.* liver and pancreas. The developmental stages of the disease parallel the incubation period which is characterized by virus multiplication manifested by viremia, production of lesions in the target organs in concurrence with exhibition of obvious clinical symptoms of the diseases (22-24).

The wide spread of adenoviruses among broiler flocks found in our survey could be explained by the latent remaining of the virus in the caecal tonsils of the infected birds and the virus shedding in faeces for long periods after birds' infection (25). The differences of mortality rates between flocks under survey could be attributed to the virulence, heterogeneity of avian adenoviruses and the administered viral load (21,26,27). The main necropsy findings seen in field inclusion body hepatitis (IBH) is severe hepatitis. Livers were enlarged, swollen and friable, with a pale yellowish-brown in colour or marble-like pattern with necrotic foci and hemorrhages present on the liver surface frequently, hemorrhages seen in leg and breast muscle similar to those described by Gowda and Satyanarayana, (28). Histological examination of IBH field cases indicate a diffuse, generalized hepatic necrosis, lymphoid infiltration with eosinophilic intranuclear inclusions in the hepatocytes were present resembling those changes mentioned (4,29). Serological methods as for example serum neutralization to distinguish FAdV isolates were not attempted because they are of little concern and cannot clearly differentiate between FAdV isolates (30). Molecular identification of FAdV in the examined liver samples in our investigation went in parallel with the findings of (12,27).

## Conclusion

From the present work, it could be concluded that IBH disease in broilers occurred in young broiler (2 weeks) and onward up to 6<sup>th</sup> weeks, resulting in considerable mortalities and economic consequences. Environmental stress and immunosuppressive agents could contribute to the percentage and duration of mortalities in broiler flocks.

## Acknowledgment

The Authors would like to thank the all staff of the Department of Veterinary Public Health, Department of Veterinary Pathology, as well as the Deanship of the College of Veterinary Medicine at the University of Mosul their help and support.

## Conflict of interest

The Authors profess that no conflict interest

## References

1. Helmboldt CF, Frazier MN. Avian hepatic inclusion bodies of unknown significance. *Avian Dis.* 1963;7(4):446-448. DOI: [10.2307/1587881](https://doi.org/10.2307/1587881)
2. Smyth JA, McNulty MS. Adenoviridae. *Poult Dis.* 2008;367-381. DOI: [10.1016/b978-0-7020-2862-5.50036-2](https://doi.org/10.1016/b978-0-7020-2862-5.50036-2)
3. Hafez HM. Avian adenoviruses infections with special attention to inclusion body hepatitis/hydropericardium syndrome and egg drop syndrome. *Pak Vet J.* 2011;31(2):85-92. [\[available at\]](#)
4. McFerran JB, Adair BM. Avian adenoviruses: A review. *Avian Pathol.* 1977;6(3):189-217. DOI: [10.1080/03079457708418228](https://doi.org/10.1080/03079457708418228)
5. Jones RC, Georgiou K. Experimental infection of chickens with adenoviruses isolated from tenosynovitis. *Avian Pathol.* 1984;13(1):13-23. DOI: [10.1080/03079458408418504](https://doi.org/10.1080/03079458408418504)
6. Macpherson I, McDougall J, Laursen-Jones A. Inclusion body hepatitis in a broiler integration. *Vet Rec.* 1974;95(13):286-289. DOI: [10.1136/vr.95.13.286](https://doi.org/10.1136/vr.95.13.286)
7. Grimes TM, King DJ, Kleven SH, Fletcher OJ. Involvement of a type-8 avian adenovirus in the etiology of inclusion body hepatitis. *Avian Dis.* 1977;21(1):26-30. DOI: [10.2307/1589361](https://doi.org/10.2307/1589361)
8. Afzal M, Muneer R, Stein G. Studies on the etiology of hydropericardium syndrome (Angara disease) in broilers. *Vet Rec.* 1991;128(25):591-593. DOI: [10.1136/vr.128.25.591](https://doi.org/10.1136/vr.128.25.591)
9. Akhtar S. Hydropericardium syndrome in broiler chickens in Pakistan. *World's Poult Sci J.* 1994;50(2):177-182. DOI: [10.1079/wps19940015](https://doi.org/10.1079/wps19940015)
10. Clemmer DI. Age-associated changes in fecal excretion patterns of strain 93 chick embryo lethal orphan virus in chicks. Infection and immunity. *Am Soci Microbiol.* 1972;5(1):60-64. DOI: [10.1128/iai.5.1.60-64.1972](https://doi.org/10.1128/iai.5.1.60-64.1972)
11. Cook JKA. Pathogenicity of avian adenoviruses for day-old chicks. *J Comp Pathol.* 1974;84(4):505-515. DOI: [10.1016/0021-9975\(74\)90043-7](https://doi.org/10.1016/0021-9975(74)90043-7)
12. Meulemans G, Boschmans M, van den Berg TP, Decaesstecker M. Polymerase chain reaction combined with restriction enzyme analysis for detection and differentiation of fowl adenoviruses. *Avian Pathol.* 2001;30(6):655-660. DOI: [10.1080/03079450120092143](https://doi.org/10.1080/03079450120092143)
13. Suvarna SK, Layton C, Bancroft JD. Bancroft's theory and practice of histological techniques. 7<sup>th</sup> ed. New York: Churchill Livingstone Press; 2013. 70-214 p. DOI: [10.1016/b978-0-7020-4226-3.00019-6](https://doi.org/10.1016/b978-0-7020-4226-3.00019-6)

14. Schachner A, Matos M, Grafl B, Hess M. Fowl adenovirus-induced diseases and strategies for their control: A review on the current global situation. *Avian Pathol.* 2017;47(2):111-126. DOI: [10.1080/03079457.2017.1385724](https://doi.org/10.1080/03079457.2017.1385724)
15. Hess M. Commensal or pathogen: A challenge to fulfil Koch's Postulates. *Br Poult Sci.* 2017;58(1):1-12. DOI: [10.1080/00071668.2016.1245849](https://doi.org/10.1080/00071668.2016.1245849)
16. Hoffmann R, Wessling E, Dorn P, Dangschat H. Lesions in chickens with spontaneous or experimental infectious hepato-myelopoietic disease (inclusion body hepatitis) in Germany. *Avian Dis.* 1975;19(2):224-225. DOI: [10.2307/1588976](https://doi.org/10.2307/1588976)
17. Singh A, Oberoi MS, Jand SK, Singh B. Epidemiology of inclusion body hepatitis in poultry in northern India from 1990 to 1994. *Revue Scientifique et Technique de l'OIE. OIE (World Organisation for Animal Health);* 1996;15(3):1053-1060. DOI: [10.20506/rst.15.3.976](https://doi.org/10.20506/rst.15.3.976)
18. Steer P, O'Rourke D, Ghorashi S, Noormohammadi A. Application of high-resolution melting curve analysis for typing of fowl adenoviruses in field cases of inclusion body hepatitis. *Aust Vet J.* 2011;89(5):184-192. DOI: [10.1111/j.1751-0813.2011.00695.x](https://doi.org/10.1111/j.1751-0813.2011.00695.x)
19. Eregae ME, Dewey CE, McEwen SA, Ouckama R, Ojkić D, Guerin MT. Flock prevalence of exposure to avian adeno-associated virus, chicken anemia virus, fowl adenovirus, and infectious bursal disease virus among ontario broiler chicken flocks. *Avian Dis.* 2014;58(1):71-77. DOI: [10.1637/10612-071113-reg.1](https://doi.org/10.1637/10612-071113-reg.1)
20. Lim T-H, Lee H-J, Lee D-H, Lee Y-N, Park J-K, Youn H-N. Identification and virulence characterization of fowl adenoviruses in Korea. *Avian Dis.* 2011;55(4):554-560. DOI: [10.1637/9730-032011-reg.1](https://doi.org/10.1637/9730-032011-reg.1)
21. Matos M, Grafl B, Liebhart D, Hess M. The outcome of experimentally induced inclusion body hepatitis (IBH) by fowl aviadenoviruses (FAdVs) is crucially influenced by the genetic background of the host. *Vet Res.* 2016;47(1). DOI: [10.1186/s13567-016-0350-0](https://doi.org/10.1186/s13567-016-0350-0)
22. Swayne DE, Boulianne M, Logue CM, McDougald LR, Nair V, Suarez DL. *Dis Poul.* 2019; 22; DOI: [10.1002/9781119371199](https://doi.org/10.1002/9781119371199)
23. Jain P. Acute pancreatitis in acute viral hepatitis. *World J Gastroenterol.* 2007;13(43):5741-5742. DOI: [10.3748/wjg.v13.i43.5741](https://doi.org/10.3748/wjg.v13.i43.5741)
24. Steer-Cope P, Sandy J, O'Rourke D, Scott P, Browning G, Noormohammadi A. Chronologic analysis of gross and histologic lesions induced by field strains of FAdV-1, FAdV-8b, and FAdV-11 in six-week-old chickens. *Avian Dis.* 2017;61(4):512-513. DOI: [10.1637/11718-072317-reg.1](https://doi.org/10.1637/11718-072317-reg.1)
25. Jones RC, Georgiou K. Experimental infection of chickens with adenoviruses isolated from tenosynovitis. *Avian Pathol.* 1984; (13) 13-23. DOI: [10.1080/03079458408418504](https://doi.org/10.1080/03079458408418504)
26. Oliver-Ferrando S, Dolz R, Calderón C, Valle R, Rivas R, Pérez M. Epidemiological and pathological investigation of fowl aviadenovirus serotypes 8b and 11 isolated from chickens with inclusion body hepatitis in Spain (2011-2013). *Avian Pathol.* 2016;46(2):157-165. DOI: [10.1080/03079457.2016.1232477](https://doi.org/10.1080/03079457.2016.1232477)
27. El-Attrache J, Villegas P. Genomic identification and characterization of avian adenoviruses associated with inclusion body hepatitis. *Avian Dis.* 2001;45(4):780-781. DOI: [10.2307/1592857](https://doi.org/10.2307/1592857)
28. Ganesh K, Raghavan R. Hydropericardium hepatitis syndrome of broiler poultry: Current status of research. *Research in Veterinary Science.* 2000;68(3):201-206. DOI: [10.1053/rvsc.1999.0365](https://doi.org/10.1053/rvsc.1999.0365)
29. McCracken JB, Adair BM. *Avian adenoviruses.* Netherlands: Elsevier Science Publishers; 1993. 123-144 p.
30. Desselberger U. *Virus Taxonomy: Classification and Nomenclature of Viruses.* *Virus Res.* 2002;83(1-2):221-222. DOI: [10.1016/s0168-1702\(01\)00352-5](https://doi.org/10.1016/s0168-1702(01)00352-5)

## دراسة عن تفشي التهاب الكبد الفيروسي ذو الأجسام الاشتمالية في الدجاج اللحم في محافظة نينوى، العراق

معن ظاهر جرجيس، ضياء محمد ظاهر جوهر  
وعقيل محمد شريف

فرع الصحة العامة البيطري، كلية الطب البيطري، جامعة الموصل،  
الموصل، العراق

### الخلاصة

كان الهدف من الدراسة هو توفير بيانات ميدانية لحدوث حالات الإصابة بالتهاب الكبد الفيروسي في محافظة نينوى للتأكيد على أهمية المرض بسبب ارتفاع معدل الهلاكات وفقدان الإنتاج. حيث جمعت ٧٢٩,٥٠٠ من أفراخ فروج اللحم شملت ٦٤ حقلاً موزعة على ١٤ موقعاً مختلفاً في محافظة نينوى خلال النصف الثاني من عام ٢٠٢٠. حيث أجريت دراسة التغيرات النسيجية المرضية للكبد في الطيور المصابة. وتم إجراء الكشف والتحديد الجزيئي لفايروس الأدينو عن طريق استخلاص الحامض النووي من عينات الكبد باستخدام عدة استخلاص الحامض النووي من النسيج. أشارت النتائج إلى وجود ٥١٨٩٢ حالة هلاك أي بنسبة ٧,١١٪. كما لوحظ إصابة قطعان التسمين بالعدوى خلال الأسبوعين الثاني والسادس من العمر، وكانت أعلى الإصابات في الأسبوع الخامس من العمر. كما كشفت الدراسة عن انخفاض معدل الهلاكات من شهر تموز إلى كانون الأول يوليو بنسبة ١١,٣ و ٧,٩١ و ٧,٠٨ و ٦,٣٨ و ٥,٩٤ و ٤,٩٥ ٪ على التوالي. أظهر الفحص المرضي المجهرى لعينات الكبد وجود الأجسام الاشتمالية داخل النواة الحمضية والمرتبطة بالمرض. وكما نتج تفاعل البلمرة المتسلسل PCR موجبة لفايروس الأدينو. يمكن الاستنتاج أن الإجهاد البيئي والعوامل المثبطة للمناعة يمكن أن تسهم في نسبة ومدة النفوق في قطعان الدجاج اللحم.