



Renal ameliorating effect of resveratrol in hydrogen peroxide induced male rats

N.T. Khudair and B.N. Al-Okaily^{ID}

Department of Physiology, Biochemistry, and Pharmacology, College of Veterinary Medicine, University of Baghdad, Baghdad, Iraq

Article information

Article history:

Received July 26, 2021
Accepted February 7, 2022
Available online May 1, 2022

Keywords:

Resveratrol
Kidney
MDA
SOD
H₂O₂

Correspondence:

B.N. Al-Okaily
najimbaraa@gmail.com

Abstract

The study aimed to investigate the potential effect of resveratrol (RS) supplementation in attenuating kidney injury induced by hydrogen peroxide (H₂O₂) in male rats. Forty adult male rats were randomly assigned into four groups (10 each). The control group was orally supplemented with distilled water, and group G1 was orally supplemented with tap water containing 0.5% of H₂O₂, G2: was orally supplemented with tap water containing 0.5% of H₂O₂ and RS 87 mg/kg BW, and G3 was orally supplemented with RS 87 mg/kg BW. Blood samples were obtained before treatment and after 45 days of daily treatment. Serum concentrations of creatinine (Cr), urea nitrogen (UN), and total bilirubin were assessed. On day 45, male rats were euthanized, and kidney samples were taken to estimate malondialdehyde (MDA) and superoxide dismutase (SOD) concentrations, and other samples were obtained for histopathological examination. The results showed a significant increase in creatinine and BUN concentrations accompanied by a significant increase in MDA and a decrease in SOD in kidney tissue in G1 group male rats compared to other groups. Resveratrol partially restored the studied criteria related to renal functions by modulating the histopathological changes in the kidney induced by hydrogen peroxide. It could be concluded that supplementation of resveratrol to oxidatively stressed rats maintains the antioxidant defenses mechanism and could be helpful in the prevention of renal oxidative stress.

DOI: [10.33899/ijvs.2022.130939.1898](https://doi.org/10.33899/ijvs.2022.130939.1898), ©Authors, 2022, College of Veterinary Medicine, University of Mosul.
This is an open access article under the CC BY 4.0 license (<http://creativecommons.org/licenses/by/4.0/>).

Introduction

Many data have developed many productive benefits of free radicals (FRs) in many physiological functions. However, FRs interrupt the normal physiological processes at different stages with initiation series of harmful chain reactions that because biological damage called oxidative stress (1). Reactive oxygen species (ROS) are highly reactive molecules generated from oxygen metabolism. Mitochondria, NADPH oxidases, xanthine oxidase (XO), endothelial cells, and Lymphocytes are the primary cellular sources of ROS and have been considered a causative factor for various diseases (2). Oxidative stress, which promotes damage of

cell membrane, proteins, and DNA via oxidative phosphorylation, results in deleterious effects on cellular function

(https://www.ncbi.nlm.nih.gov/pubmed/?term=Ratlif%20BB%5BAuthor%5D&cauthor=true&cauthor_uid=269062673). H₂O₂ is a substrate in many physiological and abnormal chemical reactions, both intracellular and extracellular, it is the next key player in mitochondrial-derived ROS, and it is the product of the dismutation reaction of superoxide radicals by Mn-SOD (4). In addition, peroxisomes are integrated into the cellular H₂O₂ signaling network that plays a precise role in producing and decomposing hydrogen peroxide by catalase (5). In the

kidney, mitochondria have a higher consumption of O₂ than other organs, which leads to an increase in their capacity for oxidative stress. Thus, kidney disease associated with high ROS considered a severe worldwide health problem, such as tauopathies and focal segmental sclerosis (6). This elevation of ROS can be activated in mesangial cells, and glucocorticoids inhabit it via a receptor-mediated mechanism, also high glucose-induces mesangial cell proliferation and fibronectin expression through NADPH oxidase-mediated ROS production, which participate in the etiology of diabetic nephropathy (7). Resveratrol (3,5,4'-trans-trihydroxystilbene) is a poly-phenolic phytoalexin present mainly in grape skin and seeds. It has various beneficial health effects (8). The antioxidant effects of RS can be related to its role through the scavenger of ROS, which depends upon the arrangement of functional groups on nuclear structure, metal ion chelating abilities, or its ability to decrease oxidation via enzyme inhibition (9). Consequently, the interest of the researchers on the phytoalexin in RS has substantially increased in the last years, and its biological and pharmacological activities at the molecular and cellular level have been studied, resulting in its classification as a good antioxidant, anti-inflammatory, anti-hyperlipidemia, cardioprotective, immunomodulatory, anti-diabetic and anti-carcinogenic effects (10-12). Therefore, the present study investigates the protective effect of resveratrol in attenuating renal injury -induced by hydrogen peroxide in male rats.

Materials and methods

Mature albino Wistar rats aged 11-12 weeks and weighted 190±20g. were kept in a well-ventilated room with plastic cages at the College of Veterinary Medicine, University of Baghdad. The animal received a standard pellet diet and drinking water freely; room temperature was 23±2°C and twelve hrs light/dark cycle during the experiment. Forty adult male rats were randomly assigned into four groups (10/each). The control (C) was orally supplemented with distilled water, and group G1 was orally supplemented with tap water containing 0.5% of H₂O₂, G2: was orally supplemented with tap water containing 0.5% of H₂O₂ and RS 87 mg/kg BW, and G3 was orally supplemented with RS 87 mg/kg BW. Blood samples were obtained by cardiac puncture technique before treatment and after 45 days of daily treatment, from anesthetized rats by intramuscular injection of 90 mg/kg BW of Ketamine and 40 mg/kg BW of Xylazine. Blood samples were centrifuged at 3000 rpm for 15minutes, serum was isolated and stored at -18 °C until analysis. Using enzymatic kits (Agappe, India), serum creatinine, blood urea nitrogen, and total bilirubin was estimated. Then after rats were euthanized, specimens from kidneys were taken, washed in saline in an ice bath, and homogenized for determination of malondialdehyde concentration and superoxide dismutase activity using

enzymatic kits (Cohesion bioscience, China). Furthermore, samples from the kidney were taken, rinsed in saline, and fixed in 10% Neutral Buffered Formalin, then specimens of 1cm³ were handled for preparation of microscopic sections of 5-6 micrometer histopathological examination (13). Statistical data analysis was performed using version 9.1 of the SPSS program. Using one-way Variance Analysis (ANOVA) followed by the least significant difference (LSD) test to detect the differences among means. P<0.05 is considered statistically significant (14).

Results

The results revealed a significant (P<0.05) increment in the mean values of serum Cr level at the end of the experiment in group G1 as compared with other groups (Figure 1A). Rats gavaged RS in combination with H₂O₂ (group G2) caused a significant (P<0.05) decrease of serum Cr concentration compared to the G1 group. Except for G1 and G2, the results showed non-significant (P>0.05) differences in this parameter between rats treated with resveratrol and the control group when compared to each other. The exact figure showed a significant (P<0.05) increase in this criterion in G1 and G2 after 45 days of the treatment compared to the pretreated period. Figure 1B pointed that serum BUN concentration was close in all groups (P>0.05) at the pretreated period. Besides, a significant (P<0.05) increase in serum BUN after 45 days of the experiment was reported in the G1 group compared to other experimental groups. Furthermore, no statistical differences (P>0.05) were recorded between G2, G3 and control groups at the same period. After 45 days of the treatment, a remarkable (P<0.05) increase in serum bilirubin concentration in G1 and G2 treated groups as compared with control and group G3 (Figure 1C). A statistical decrease (P<0.05) was noticed in group G2 after 45 days of the study compared to the G1 group, whereas no significant (P>0.05) difference was recorded between G3 and control groups at the same period.

After 45 days of treatment, a significant (P<0.05) increase in MDA concentration in kidney tissue homogenate was observed in G1 and G2 treated groups compared to control and G3 groups (Figure 2A). In addition, a non-significant (P>0.05) difference in the concentration of MDA in kidney tissue between G3 and control groups was observed. In contrast, the statistical analysis clarified a significant decrease (P<0.05) in the kidney tissue of SOD activity in G1 and G2 treated rats compared to other groups (Figure 2B). Non-significant (P>0.05) difference was found in SOD enzyme activity in kidney tissues between the control and resveratrol treated groups.

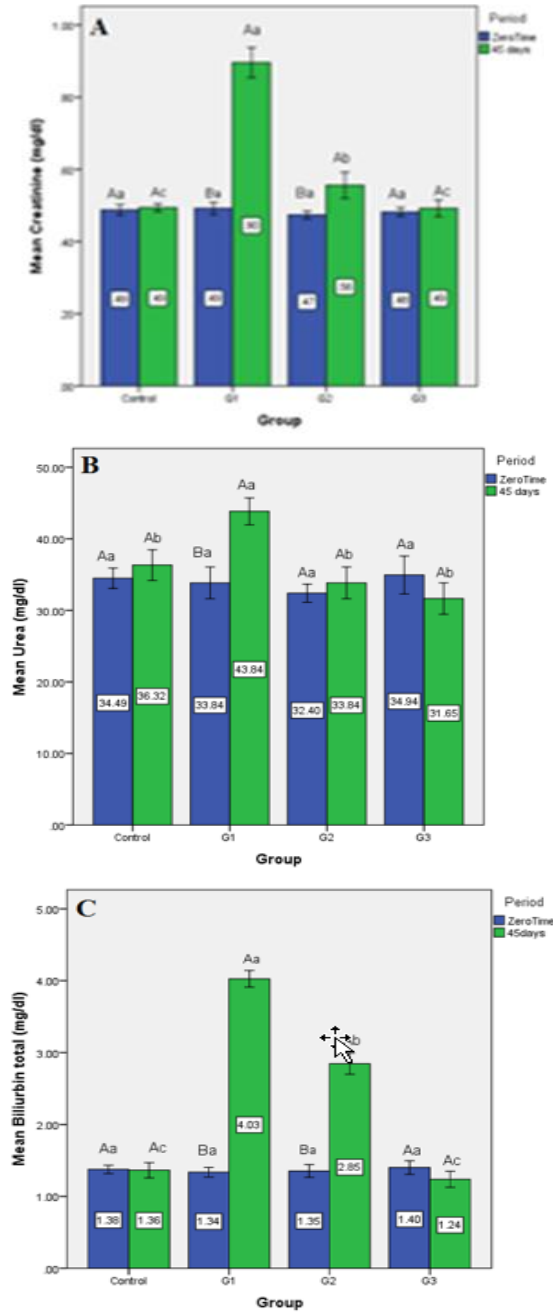


Figure 1: Effect of resveratrol on serum concentrations of (A) Creatinine, (B) urea nitrogen, and (C) total bilirubin in hydrogen peroxide-induced in adult male rats. Values are denoted as mean \pm SE. n= 10/each group, control was orally supplemented with distilled water, G1: was orally supplemented with tap water containing 0.5% of H₂O₂, G2: was orally supplemented with tap water containing 0.5% of H₂O₂ and RS (87 mg/Kg.bw), G3: was orally supplemented with RS (87 mg/Kg.bw), Different small letters are different significantly (P<0.05) between groups, Different capital letters are significantly different (P<0.05) within the group.

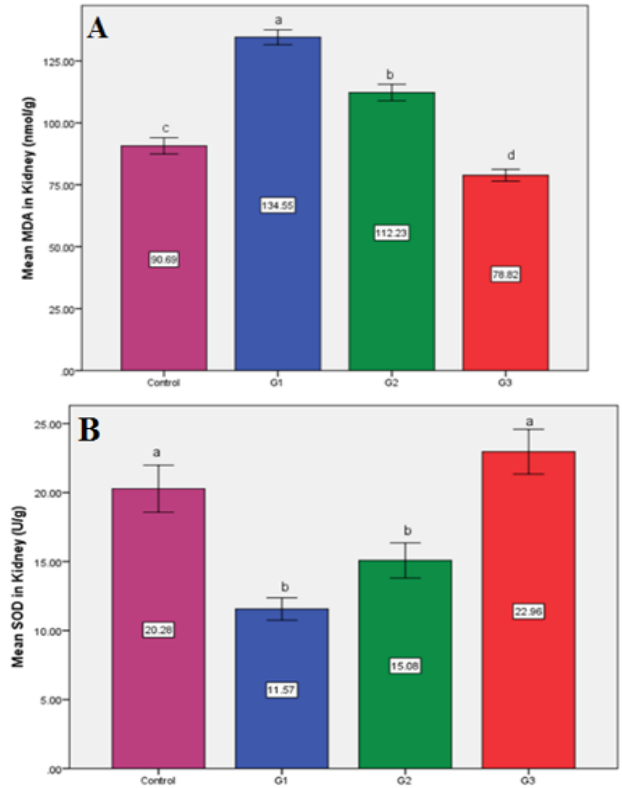


Figure 2: Effect of resveratrol on kidney tissue homogenates concentration of (A) malondialdehyde and (B) superoxide dismutase (SOD) activity in hydrogen peroxide-induced male rats. Values are denoted as mean \pm SE. n= 10/each group, control was orally supplemented with distilled water. G1: was orally supplemented with tap water containing 0.5% of H₂O₂, G2: was orally supplemented with tap water containing 0.5% of H₂O₂ and RS (87 mg/Kg.bw), G3: was orally supplemented with RS (87 mg/Kg.bw), Different small letters are different significantly (P<0.05) between groups.

Kidney sections of the G1 group showed hemorrhage, granular degeneration, vacuolation, and congested blood vessels between renal tubules. While sloughing of epithelial lining cells of renal tubules and disruption of deterioration of glomerular tuft renal cortex showed cloudy and vacuolar degeneration and necrosis of renal tubules this due to harmful effect of hydrogen peroxide (Figures 3-5) these pathological changes indicated renal injury compared to the control (Figures 6-8). On the other hand, rats that received hydrogen peroxide concurrently with resveratrol supplementation (G2) exhibited rescued renal damage without any signs of toxicity manifested by improvement of renal tubular epithelial cells and regular collecting tubules (Figures 9 and 10) was observed. Furthermore, resveratrol supplementation at 87 mg/kg BW showed the complete typical tissue (Figures 11 and 12).

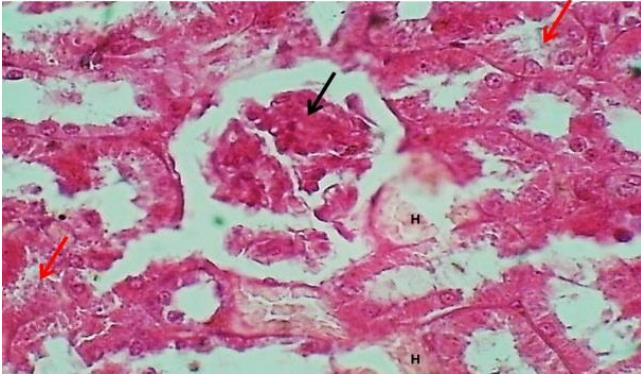


Figure 3: histological section in renal cortex of group G1 illustrate: hemorrhage (H) granular degeneration of renal tubules (Red arrows) and disruption of mesangial cells, and deterioration of glomerular tuft (Black arrow). H&E stain. 400x.

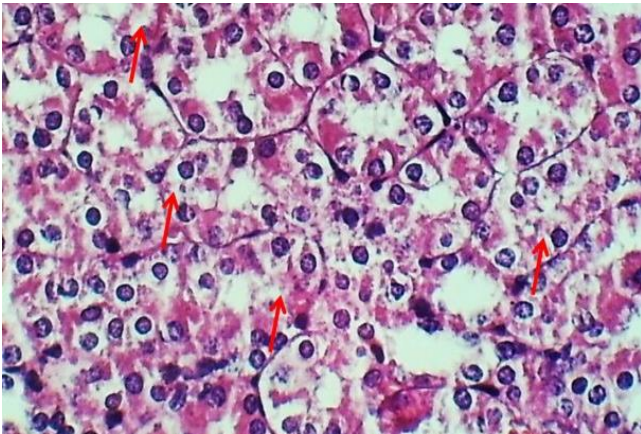


Figure 4: histological section in renal cortex of group G1 shows: cloudy degeneration and necrosis of renal tubules (Arrows). H&E stain. 400x.

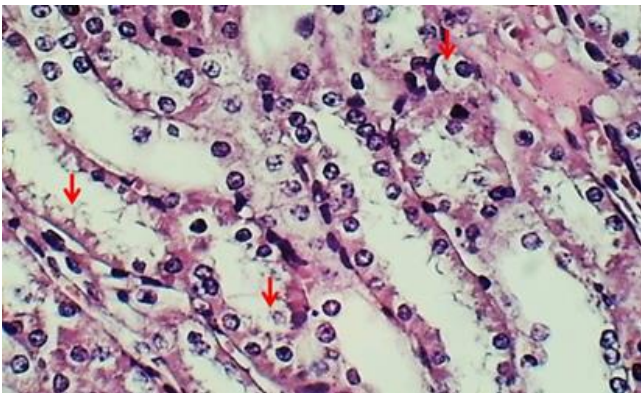


Figure 5: histological section in renal cortex of group G1 shows: vascular degeneration of renal tubules (Arrows). H&E stain. 400x.

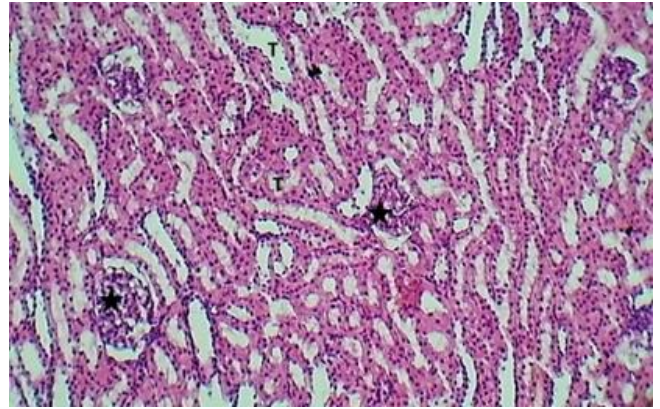


Figure 6: histological section in renal cortex of control group shows: glomeruli (Asterisk) and distal renal tubules (T). H&E stain.100x.

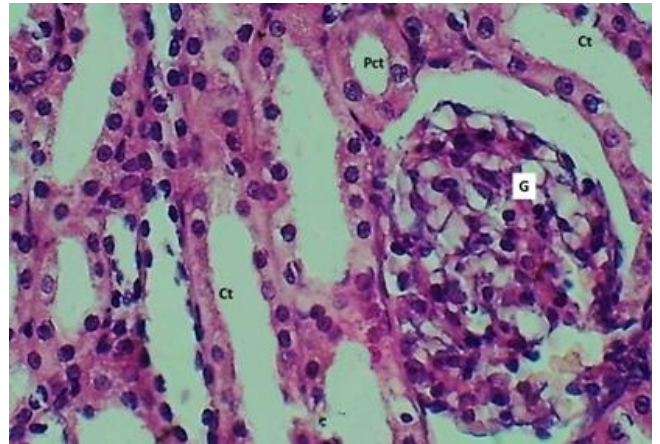


Figure 7: histological section in renal cortex of control group shows: glomeruli (G), collecting tubule (Ct) and proximal (Pct). H&E stain.400x.

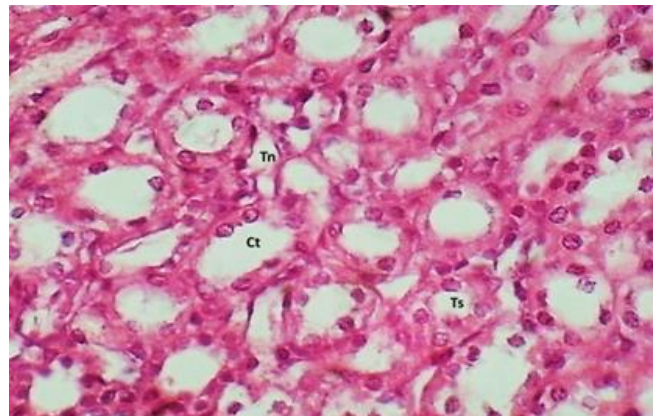


Figure 8: histological section in the renal medulla of control group shows: collecting tubules (Ct), thick segment (Ts) and thin segment (Tn) of the loop of henle.H&E stain.400x.

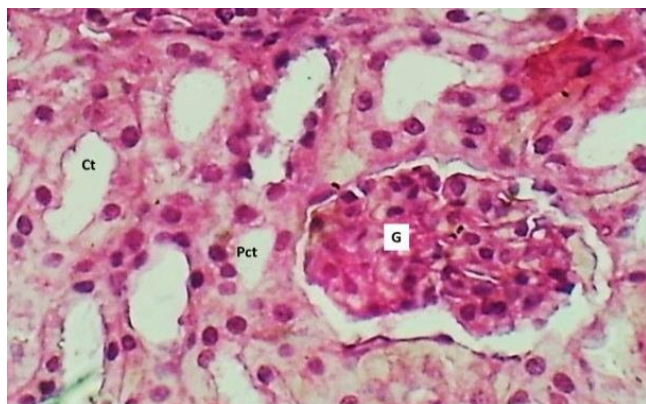


Figure 9: histological section in renal cortex of group G2 shows: normal glomerulus (G), proximal (Pct) and collecting tubules (Ct). H&E stain.400x.

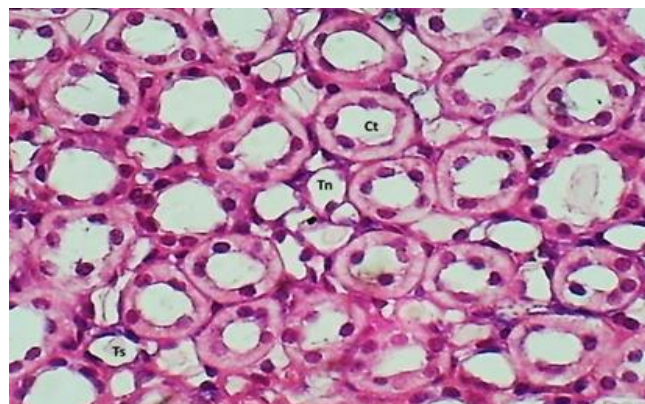


Figure 12: histological section in the renal medulla of group G3 shows: normal collecting tubules with thick and thin segments. H&E stain. 400x.

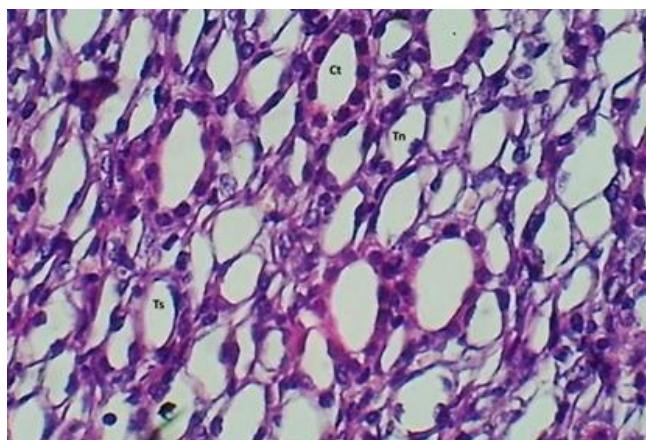


Figure 10: histological section in the renal medulla of group G2 shows: normal collecting tubules (Ct) with thick (Ts) and thin (Tn) segments. H&E stain. 400x.

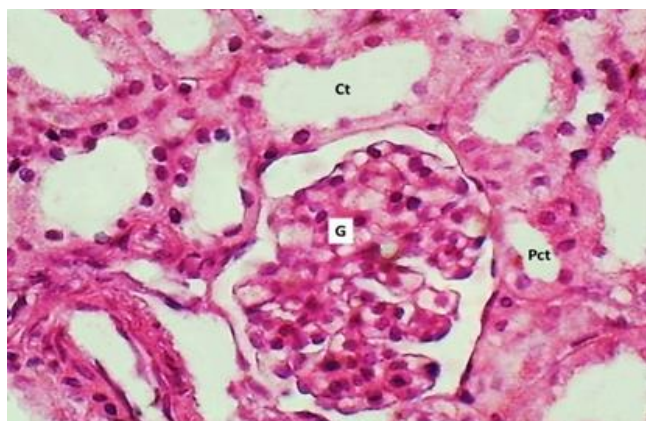


Figure 11: histological section in renal cortex of group G3 shows: normal glomerulus (G) and proximal tubule (Pct) and collecting tubule (Ct). H&E stain.400x.

Discussion

A remarkable elevation in serum creatinine, blood urea, and bilirubin concentrations in group G1 confirms kidney dysfunction/injury- induced by hydrogen peroxide characterized by the histopathological alterations of the kidney with the presence of oxidant status. This confirmed a case of oxidative stress leading to impaired kidney functions reflected by the kidney tubule's inability to maintain plasma urea and creatinine at normal levels. These results were in agreement with (6). Besides, excessive generation of ROS and many pro-and anti-inflammatory cytokines are implicated in the development of kidney injury that has a critical role in the pathophysiology of many kidney diseases with several complications related to inflammations (3,15). Rich mitochondria in the proximal renal tubular cells maybe make it vulnerable to damage and accelerate the progression of renal disease (16). Moreover, in chronic kidney disease, depletion of antioxidants was associated with diabetes, cardiomyopathy, hypertension, inflammation, and anemia (17-19).

Resveratrol alleviates kidney dysfunction in the G2 group characterized by a decrease in serum kidney function tests. These changes may be via anti-inflammatory and antioxidative effects of resveratrol (10). These modulatory effects of RS were agreed with Takemura *et al.* (20). Resveratrol can be protecting renal tubular epithelial cells through down-regulation of TLR4, NF- κ B pathway, and reduced cell apoptosis in renal ischemia-perfusion injury model (21). Furthermore, resveratrol effectively restored SIRT1/3 activity, reduced acetylated SOD2 levels, ameliorated mitochondrial dysfunction of renal tubular epithelial cells, and improved kidney function by its anti-inflammatory activity and anti-inflammatory activity, improving the metabolic memory of hyperglycemia (22). As the RS exhibited a powerful supplement in preventing renal

injury, it could be suggested that RS is a promising therapeutic strategy for ameliorating renal disease.

Hydrogen peroxide-induced oxidative status in animal models (rats) in group G1 is given a dose and period dependent leading to LPO, documented by histopathological changes. These results were in agreement Rathi *et al.* (23). Shielding effectiveness of resveratrol in G2 treated groups showed attenuating the oxidative stress in serum and kidney tissue homogenate through increased SOD activity and scavenger ROS (24). Resveratrol improvement cellular antioxidant enzymes, particularly enzymes of SOD and other redox molecules, serve to counterbalance ROS generated in the cell (9). In addition, resveratrol inhibits TNF and H₂O₂-induced NF- κ B activation in a dose- and time-dependent manner (25), and protection against oxidative cytotoxicity may be due to upregulation of the mitochondrial SOD2, or it increases the expression of genes of antioxidants (catalase, copper chaperone for superoxide dismutase 1, glutathione S-transferase zeta1) through transcriptional regulation via nuclear factor E2-related factor 2 (Nrf2) (26). Moreover, resveratrol caused significantly abolished the phosphorylation of the platelet-derived growth factor (PDGF) receptor and reduced the proliferation of mesangial cells, which are involved in the pathogenesis of glomerulonephritis exerted nephroprotection properties via its anti-nitrosative and anti-apoptotic effects prior to methotrexate (27). Resveratrol inhibits the expression of urine albumin and β 2-microglobulin and increases total antioxidant capacity in kidney tissue and SOD in serum (28).

Concerning the histopathological changes, the results confirmed the ability of H₂O₂ to induce progressive adverse effects on the components of the cell as illustrated in figures belonging to group G1, maybe due to LPO and oxidative stress, which led to increases in intracellular calcium, activates membrane phospholipid proteases, mitochondrial dysfunction (3), glomerular tuft degeneration and promote the initiation of autophagy and apoptosis in the different pathway (29). Current observations showed that resveratrol rescued renal histopathological damage against H₂O₂. These results agreed with other researchers (30). Presumably, resveratrol can act through different mechanisms in ameliorating renal damage due to its potent antioxidative, anti-inflammatory, anti-apoptotic, and anti-complement effects (9,20). Moreover, resveratrol improvement of renal functions may be through increase the expression of antioxidant enzymes via transcriptional regulation of Nrf2 and forkhead box O (FOXO) (31) with reduced the expression of glomerular fibronectin, collagen IV, and nephrin in diabetic rats (32). In the same context, the renoprotective effect of resveratrol appears via activation of the SIRT1/FOXO1 pathway and enhances mitochondrial biogenesis with Mn-SOD. Moreover, it prevents glomerulosclerosis, and attenuated renotoxicity- induced by lipopolysaccharides may be via reduced SIRT3 activity (33-38).

Conclusion

Together, the beneficial effects of resveratrol are not elucidated but have been related mainly to its antioxidant and anti-inflammatory activities that have been demonstrated to protect kidney damage caused by oxidative stress.

Acknowledgments

The authors are grateful to the College of Veterinary Medicine, the University of Baghdad, supporting the laboratory facilities.

Conflict of interest

The authors reveal that there is no conflict of activity.

References

1. Obeagu EI. A review on free radicals and antioxidants. *Int J Curr Res Med Sci.* 2018;4(2):123-133. DOI: [10.22192/ijcrms.2018.04.02.019](https://doi.org/10.22192/ijcrms.2018.04.02.019)
2. Aziz N, Jamil RT. *Biochemistry, Xanthine Oxidase.* New York: Stat Pearls Publishing; 2021. [[available at](#)]
3. Aggarwal A, Tuli HS, Varol A, Thakral F, Year MB, Sak K, Varol M, Jain A, Khan A, Sethi G. Role of reactive oxygen species in cancer progression: Molecular mechanisms and recent advancements. *Biomolecules.* 2019;9:735. DOI: [10.3390/biom9110735](https://doi.org/10.3390/biom9110735)
4. Ratliff BB, Abdulmahdi W, Pawar R, Wolin MS. Oxidant mechanisms in renal injury and disease. *Antioxid Redox Signal.* 2016;25(3):119-146. DOI: [10.1089/ars.2016.6665](https://doi.org/10.1089/ars.2016.6665)
5. Lismont C, Revenco I, Franssen M. Peroxisomal hydrogen peroxide metabolism and signaling in health and disease. *Int J Mol Sci.* 2019;20(15):3673. DOI: [10.3390/ijms20153673](https://doi.org/10.3390/ijms20153673)
6. Barja G. Free radicals and aging. *Trends Neurosci.* 2004;27(10):595-600. DOI: [10.1016/j.tins.2004.07.005](https://doi.org/10.1016/j.tins.2004.07.005)
7. Gyurászová M, Gurecká R, Bábíčková J, Tóthová L. Oxidative stress in the pathophysiology of kidney disease: Implications for noninvasive monitoring and identification of biomarkers. *Oxid Med Cell Longev.* 2020;1-11. <https://doi.org/10.1155/2020/5478708>.
8. Fogo AB. Causes and pathogenesis of focal segmental glomerulosclerosis. *Nat Rev Nephrol.* 2015;11(2):76-87. DOI: [10.1038/nrneph.2014.216](https://doi.org/10.1038/nrneph.2014.216)
9. Akaishi T, Abo M, Okuda H, Ishizawa K, Abe T, Ishii T, Ito S. High glucose level and angiotensin II type I receptor stimulation synergistically amplify oxidative stress in renal mesangial cells. *Sci Rep.* 2019;(9):5214. DOI: [10.1038/s41598-019-41536-z](https://doi.org/10.1038/s41598-019-41536-z)
10. Pezzuto JM. Resveratrol twenty years of growth, development, and controversy. *Biomol Ther.* 2019;27(1):1-14. <https://doi.org/10.4062/biomolther.2018.176>
11. Malhotra A, Bath S, Elbarbry F. An organ system approach to explore the antioxidative, anti-inflammatory, and cytoprotective actions of resveratrol. *Oxid Med Cell Long.* 2015;8093. DOI: [10.1155/2015/803971](https://doi.org/10.1155/2015/803971)
12. Colica C, Milanović M, Milić N, Aiello V, De Lorenzo A, Abenavoli L. A Systematic review on natural antioxidant properties of resveratrol. *Nat Prod Comm.* 2018;13:1-9. DOI: [h.org/10.1177/1934578X1801300923](https://doi.org/10.1177/1934578X1801300923)
13. Yan F, Sun X, Xu C. Protective effects of resveratrol improve cardiovascular function in rats with diabetes. *Exp Ther Med.* 2018;15:1728-1734. DOI: [10.3892/etm.2017.5537](https://doi.org/10.3892/etm.2017.5537)
14. Xiao Q, Zhu W, Feng W, Lee SS, Leung AW, Shen J, Gao L, Xu C. A Review of resveratrol as a potent chemoprotective and synergistic agent in cancer chemotherapy. *Front Pharmacol.* 2019;9:1534. DOI: [10.3389/fphar.2018.01534](https://doi.org/10.3389/fphar.2018.01534)

15. Baker SA, Abdullah MA, Abed AA. Protective effect of quercetin against corneal toxicities induced by cisplatin in male mice. *Iraqi J Vet Sci.* 2022;36(2):321-326. DOI: [10.33899/ijvs.130145.1741](https://doi.org/10.33899/ijvs.130145.1741)
16. Al-Sabaawy HB, Rahawi Am, Al-Mahmood SS. Standard techniques for formalin-fixed paraffin-embedded tissue: A Pathologist's perspective. *Iraqi J Vet Sci.* 2021;35(suppl I-III):127-135. DOI: [10.33899/ijvs.2021.131918.2023](https://doi.org/10.33899/ijvs.2021.131918.2023)
17. Snedecor GW, Cochran W G. *Statistical Methods.* 6th ed. USA: The Iowa State University Press; 1973. 238-248 p.
18. Alabdaly YZ, Saeed M G, Al-Hashemi H M. Effect of methotrexate and aspirin interaction and its relationship to oxidative stress in rats. *Iraqi J Vet Sci.* 2021;35(1):151-156. DOI: [10.33899/ijvs.2020.126490.1335](https://doi.org/10.33899/ijvs.2020.126490.1335)
19. Ozbek E. Induction of oxidative stress in kidney. *Int J Nephrol.* 2012;12:9. DOI: [10.1155/2012/465897](https://doi.org/10.1155/2012/465897)
20. Takemura K, Nishi H, Inagi R. Mitochondrial dysfunction in kidney disease and uremic sarcopenia. *Front Physiol.* 2020;4:11:565023. DOI: [10.3389/fphys.2020.565023](https://doi.org/10.3389/fphys.2020.565023)
21. Mohammed IH, Kakey IS, Farimani MM. Some anti-diabetic properties of *Prosopis farcta* extracts in alloxan-induced diabetic in adult rats. *Iraqi J Vet Sci.* 2020;34(1):109-113. DOI: [10.33899/ijvs.2019.125557.1076](https://doi.org/10.33899/ijvs.2019.125557.1076)
22. Kaludercic N, Lisa FD. Mitochondrial ROS formation in the pathogenesis of diabetic cardiomyopathy. *Front Cardio Med.* 2020;7:12. DOI: [10.3389/fcvm.2020.00012](https://doi.org/10.3389/fcvm.2020.00012)
23. Rathi M, Jeloka T, Prasad N, Bansal S, Kumar S. Chronic kidney disease and hypertension with reference to COVID-19. *Indian J Nephrol.* 2020;30(3):155-157. DOI: [10.4103/ijn.IJN16820](https://doi.org/10.4103/ijn.IJN16820)
24. Den Hartogh D J, Tsiani E. Health benefits of resveratrol in kidney disease: Evidence from in vitro and in vivo studies. *Nutrients.* 2019;11(7):1624. DOI: [10.3390/nu11071624](https://doi.org/10.3390/nu11071624)
25. Kitada M, Koya D. Renal protective effects of resveratrol. *Oxid Med Cell Longev.* 2013;2013:568093. DOI: [10.1155/2013/568093](https://doi.org/10.1155/2013/568093)
26. Li JA, Li LA, Wang SA, Zhang CA, Zheng LA, Jia YA, Xu MA, Zhu TA, Zhang YB, Rong RA. Resveratrol alleviates inflammatory responses and oxidative stress in rat kidney ischemia-reperfusion injury and H₂O₂-induced NRK-52E cells via the Nrf2/TLR4/NF-κB Pathway. *Cell Physiol Biochem.* 2019;45:1677-1689. DOI: [10.1159/000487735](https://doi.org/10.1159/000487735)
27. Xian Y, Gao Y, Lv W, Ma X, Hu J, Chi J, Wang W, Wang Y. Resveratrol prevents diabetic nephropathy by reducing chronic inflammation and improving the blood glucose memory effect in non-obese diabetic mice. *Naunyn Schmiedeberg's Arch Pharmacol.* 2020;393:2009-2017. DOI: [10.1007/s00210-019-01777-1](https://doi.org/10.1007/s00210-019-01777-1)
28. Ganie S A, Haq E, Hamid A, Masood A, Zargar M A. Long dose exposure of hydrogen peroxide (H₂O₂) in albino rats and effect of Podophyllum hexandrum on oxidative stress. *Eur Rev Med Pharmacol Sci.* 2011;15:906-915. [\[available at\]](#)
29. Gu T, Wang N, Wu T, Ge Q, Chen L. Antioxidative stress mechanisms behind resveratrol: A multidimensional analysis. *J Food Qual.* 2021;2021:12. DOI: [10.1155/2021/5571733](https://doi.org/10.1155/2021/5571733)
30. Manna SK, Mukhopadhyay A, Aggarwal BB. Resveratrol suppresses TNF-induced activation of nuclear transcription factors NF-κB, activator protein-1, and apoptosis: Potential role of reactive oxygen intermediates and lipid peroxidation. *J Immunol.* 2000;164(12):6509-6519. DOI: [10.4049/jimmunol.164.12.6509](https://doi.org/10.4049/jimmunol.164.12.6509)
31. Cosín-Tomás M, Senserrich J, Arumí-Planas M, Alquézar C, Pallàs M, Martín-Requero Á, Suñol C, Kaliman P, Sanfeliu C. Role of resveratrol and selenium on oxidative stress and expression of antioxidant and anti-aging genes in immortalized lymphocytes from Alzheimer's disease patients. *Nutrients.* 2019;11(8):1764. DOI: [10.3390/nu11081764](https://doi.org/10.3390/nu11081764)
32. El-Sheikh A A, Morsy M A, Al-Taher A Y. Protective mechanisms of resveratrol against methotrexate-induced renal damage may involve BCRP/ABCG2. *Fundam Clin Pharmacol.* 2016;30(5):406-18. DOI: [10.1111/fcp.12205](https://doi.org/10.1111/fcp.12205)
33. Xiao B, Ma W, Zheng Y, Li Z, Li D, Zhang Y, Li Y, Wang D. Effects of resveratrol on the inflammatory response and renal injury in hyperuricemic rats. *Nutr Res Pract.* 2021;15(1):26-37. DOI: [10.4162/nrp.2021.15.1.26](https://doi.org/10.4162/nrp.2021.15.1.26)
34. Su LJ, Zhang JH, Gomez H, Murugan R, Hong X, Xu D, Jiang F, Peng ZY. Reactive oxygen species-induced lipid peroxidation in apoptosis, autophagy and ferroptosis. *Oxid Med Cell Longev.* 2019;2019:50. DOI: [10.1155/2019/5080843](https://doi.org/10.1155/2019/5080843)
35. Arici MA, Sahin A, Cavdar Z, Ergur BU, Ural C, Akokay P, Kalkan S, Tuncoek Y. Effects of resveratrol on alpha-amanitin-induced nephrotoxicity in BALB/c mice. *Hum Exp Toxicol.* 2020;39(3):328-337. DOI: [10.1177/0960327119888271](https://doi.org/10.1177/0960327119888271)
36. Ahmed SM, Luo L, Namani A, Wang X J, Tang X. Nrf2 signaling pathway: Pivotal roles in inflammation. *Biochim Biophys Acta Mol Basis Dis.* 2017;1863(2):585-597. DOI: [10.1016/j.bbdis.2016.11.005](https://doi.org/10.1016/j.bbdis.2016.11.005)
37. Qiao Y, Gao K, Wang Y, Wang X, Cui B. Resveratrol ameliorates diabetic nephropathy in rats through negative regulation of the p38 MAPK/TGF-β1 pathway. *Exp Ther Med.* 2017;13(6):3223-3230. DOI: [10.3892/etm.2017.4420](https://doi.org/10.3892/etm.2017.4420)
38. Xu S, Gao Y, Zhang Q, Wei S, Chen Z. SIRT1/3 Activation by resveratrol attenuates acute kidney injury in a septic rat model. *Oxid Med Cell Longev.* 2016;33(3):1-12. DOI: [10.1155/2016/7296092](https://doi.org/10.1155/2016/7296092)

تأثير تحسين الكلى بالريسفيراترول في الجرذان المستحدثة ببيروكسيد الهيدروجين

نور تقي خضير و براء نجم العقيلي

فرع الفلسفة، الكيمياء الحيوية والأدوية، كلية الطب البيطري، جامعة بغداد، بغداد العراق

الخلاصة

هدفت هذه الدراسة الى معرفة التأثير المحتمل لمكملات الريسفيراترول في التخفيف من أصابه الكلى الناتجة عن بيروكسيد الهيدروجين 0.5% في ذكور الجرذان. تم تقسيم أربعين جرذاً بالغاً إلى أربع مجموعات (10 في كل مجموعة) على النحو التالي: أعطيت مجموعة السيطرة الماء المقطر، المجموعة الأولى أعطيت مياه الصنبور المضاف إليها 0.5% بيروكسيد الهيدروجين، المجموعة الثانية أعطيت ماء الصنبور المضاف إليه 0.5% بيروكسيد الهيدروجين والريسفيراترول 87 ملغم/كغم من وزن الجسم والمجموعة الثالثة أعطيت الريسفيراترول 87 ملغم/كغم من وزن الجسم. تم أخذ عينات الدم قبل المعاملة وبعد 45 يوماً من المعاملة اليومية. تم تقييم تركيز الكرياتينين والنيتروجين اليوريا والبيليروبين الكلي في المصل. في يوم 45 من التجربة تم القتل الرحيم لذكور الجرذان وأخذت عينات من أنسجة الكلى لتحديد تركيز المالنودالدهايد ونشاط أنزيم سوبراوكسيد دسميونيز وأيضاً تم الحصول على عينات أخرى لدراسة التغيرات النسيجية المرضية. أظهرت النتائج زيادة معنوية في تركيز الكرياتينين والنيتروجين يوريا والبيليروبين الكلي في المصل مرتبطة مع زيادة معنوية في تركيز المالنودالدهايد وانخفاض معنوي في نشاط أنزيم سوبراوكسيد دسميونيز تركيز في أنسجة كلى جرذان المجموعة GI بمقارنة مع المجموع الأخرى. حافظ الريسفيراترول جزئياً على المعايير المدروسة المتعلقة بوظائف الكلى مع تعديل التغيرات النسيجية المرضية في الكلى التي يسببها بيروكسيد الهيدروجين. يمكن الاستنتاج أن إعطاء مكملات الريسفيراترول يحافظ على آلية دفاعات مضادات الأكسدة في الجرذان المجهدة ويمكن أن يكون مفيداً في الوقاية من الإجهاد التأكسدي الكلي.