




## Survey and diagnostic study of *Eimeria truncata* in geese and ducks

Ahlam F. Al-Tae 

Department of Microbiology, College of Veterinary Medicine, University of Mosul, Mosul, Iraq

### Article information

#### Article history:

Received October 06, 2020  
Accepted February 01, 2021  
Available online October 27, 2021

#### Keywords:

Renal coccidiosis  
*Eimeria truncata*  
Geese  
Ducks

#### Correspondence:

H.O. Dyary  
[ahlaam.altae@gmail.com](mailto:ahlaam.altae@gmail.com)

### Abstract

This trial was aimed to determine the prevalence of renal coccidiosis in domestic geese and ducks in Nineveh governorate, Iraq. One hundred and thirty birds of both sexes and different ages were randomly purchased from many localities of Nineveh governorate during the period between 2017 and 2018. According to geese and ducks' age, the overall infection was 70.00% and 51.66%, respectively, 74.35% for geese and 53.19% for ducks <6 months, 64.51% and 46.15% for  $\leq 7$  months. Sex distribution of renal coccidiosis showed that 75.55%, 54.05% of female geese and ducks, and 60.00%, 47.82% of male geese and ducks were positive, respectively. Impression smears from kidneys for the presence of *Eimeria truncata* in geese showed that 49 (70 %) were positive, while 31 (51.66%) were positive for ducks. Cloacal fecal samples for *Eimeria truncata* oocysts were tested by flotation technique revealed that 22.85% were positive for geese and 16.66% for ducks. The dimensions of *Eimeria truncata* development stages (schizonts, macrogametes, microgametes, and oocytes) were measured. The histological sections of the infected geese and ducks' kidneys showed the different developmental stages of the *Eimeria truncata* parasite with various pathological changes.

DOI: [10.33899/ijvs.2021.128585.1591](https://doi.org/10.33899/ijvs.2021.128585.1591), ©Authors, 2022, College of Veterinary Medicine, University of Mosul.  
This is an open access article under the CC BY 4.0 license (<http://creativecommons.org/licenses/by/4.0/>).

### Introduction

Coccidiosis is a worldwide disease caused by a single celled parasite belonging to the phylum Apicomplexa, family Eimeriidae. The parasite could enter the duck's and geese's gut cells to reproduce, meronts and gamonts occur in the epithelial cells of kidney tubules. The degree of damage will depend on how many coccidial (oocysts) have been taken in addition to the feverish environmental condition (1). Many adverse health conditions were recorded, like reducing nutrient absorption, weight loss, and diarrhea, or even bloody diarrhea in severe cases, leading to mortality 5-10% (2-5). Coccidial eggs (oocysts) have a very thick wall and can resist severe environmental stresses and disinfectants. Intestinal coccidiosis in geese and ducks was reported here in Iraq (and elsewhere throughout the world (6) renal coccidiosis was described all over the world (7-9) but does not yet report in Nineveh governorate. Renal coccidiosis has been reported in 10 members of the Order Anseriformes, two

Procellariiformes, and one member in each of the Charadriiformes and Strigiformes (10). The mysterious transmission of intestinal coccidiosis to kidney coccidiosis by infection with *E. truncata* has not been resolved as was mentioned by Oksanen (11). Infected geese and ducks shed the oocysts with their ureters, sporont (zygote) present in oocyst divides and forms four sporocysts, each containing two infective sporozoites within 1-5 days. Infective oocysts could be ingested by birds feeding in a contaminated environment. The Parasite reaches kidneys and junction of ureters, where sexual reproduction produces oocysts. Heavily infected birds may die due to kidney failure. The life cycle is continued by infected birds shedding oocysts into the environment (4). Ducks and geese are highly efficient in the production of eggs and animal protein. In Iraq and here in Nineveh governorate, the usefulness of ducks and geese in providing a part of the animal protein urged the population in breeding these kinds of birds in small herds on farms and homes. Most renal coccidiosis reports in ducks and geese are

asymptomatic birds or birds that show minor physiological or pathological changes due to the parasite. Young birds and those stressed by various conditions are most likely to have clinical cases of renal coccidiosis. Mortality has occurred in free-ranging wild geese and ducklings. Disease in domestic geese is usually acute, lasts only 2-3 days, and can kill large flock segments (12,13).

However, no reports about renal coccidiosis in ducks and geese were reported in Nineveh governorate; therefore, this study was carried out to determine renal coccidiosis frequency in domestic ducks and geese in Nineveh governorate, Iraq.

## Materials and methods

Sixty local domestic ducks and seventy geese of different ages and sexes were randomly selected from various localities of Nineveh governorate, Al-Hamdania, Al-Khazer, Al-Salamia, Bazwea, Kokjali, and from some local markets, during the period from October 2017 to October 2018. All birds were delivered to the laboratory of parasitology in the college of veterinary medicine. Birds were sacrificed in the laboratory and necropsied for renal coccidiosis; affected kidneys were freshly sampled. The diagnosis was based on the observation of the clinical signs, necropsy renal findings, pathological and histopathological changes of the kidneys and ureters, microscopic features of the development stages, and impression smears of the affected kidneys and flotation fecal. Kidneys were almost enlarged in size; they were removed and impressed from at least five different regions to get the wet tissue smears, which were stained by Giemsa stain (Romanowsky) for detecting the developmental stages of coccidian parasite (4,14). Both kidneys and ureters were cut to get samples from the anterior, middle, and posterior portions for histopathological by fixing 10% phosphate-buffered formalin (15). Fixed tissues were sectioned at 5 µm by using standard histological procedures and stained with Harris's hematoxylin-eosin stain (H&E). Morphometric measurements of smears were examined for identifying different developmental coccidian stages using a light microscope at 40X and 100X magnification (16).

## Results

The age of birds tested for renal coccidiosis influences the prevalence of their infectivity in both types, geese, and ducks. The distribution of *Eimeria truncata* in these birds to their different ages (Table 1). From the Table, it is evident that goslings and ducklings less than 6 months of age had a higher prevalence of renal coccidiosis compared to those of 7 and more. Geese showed a higher prevalence than ducks. The overall prevalence for geese and ducks according to their age were 70.00% and 51.66%, respectively, while the age distribution of renal coccidiosis for both of them was as follows, 74.35% for geese and 53.19% for ducks at <6 months of age and were 64.51% and 46.15% for both geese and ducks respectively at 7 months of age and more. In addition to age, sex affected the prevalence of renal coccidiosis in both geese and ducks. The distribution of *Eimeria truncata* in these birds (Table 1).

Females were infected more than males in their renal coccidiosis, but geese in the meantime had a higher prevalence than ducks. Sex distributions of renal coccidiosis were 75.55% and 54.05% for female geese and ducks, respectively, and were 60.00% and 47.82% for male geese and ducks, respectively.

## Impression smears

In geese the table 3 shows that out of 70 geese examined through impression smears, 49(70%) were positive for renal coccidiosis. Impression smears of the infected geese kidneys showed the different reproductive stages of the *Eimeria truncata* parasite, macrogametocyte, microgametocyte, and schizonts (Figure 1).

In ducks the table 3 shows that out of 60 ducks examined for renal coccidiosis through impression smears, 31(51.66%) were positive for the presence of *Eimeria truncata* development stages. Impression smears of the infected ducks' kidneys showed different reproductive stages of the *Eimeria truncata* parasite, macrogametocyte, microgametocyte, and schizonts (Figure 2).

Table 1: Prevalence of renal coccidiosis in infected geese and ducks according to their age and sex

Age / Sex	Geese		Ducks	
	No examined	No(%) +ve	No examined	No(%) +ve
< 6 months	39	29(74.35%)	47	25(53.19%)
≥ 7 months	31	20(64.51%)	13	6(46.15%)
Total	70	49(70.00%)	60	31(51.66%)
Female	45	34(75.55%)	37	20(54.05%)
Male	25	15(60.00%)	23	11(47.82%)
Total	70	49(70.00%)	60	31(51.66%)

Table 3: Renal coccidiosis prevalence by kidney impression

Birds	No examined	Kidney's impression	
		No. +ve	%
Geese	70	49	70
Duck	60	31	51.66

Table 4: *Eimeria truncata* in infected by fecal examination

Birds	No examined	Kidney's impression	
		No. +ve	%
Geese	70	16	22.85
Duck	60	10	16.66

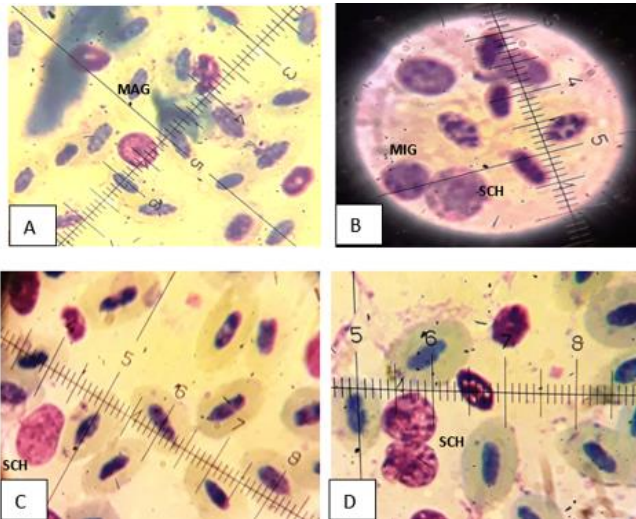


Figure 1: Impression smear of geese kidney infected with *Eimeria truncata* with different developmental stages. (Giemsa stain, 1000 X). A= Macrogametocyte (MAG); B=Microgametocyte (MIG) and Schizonte (SCH); C and D= Schizonts(SCH).

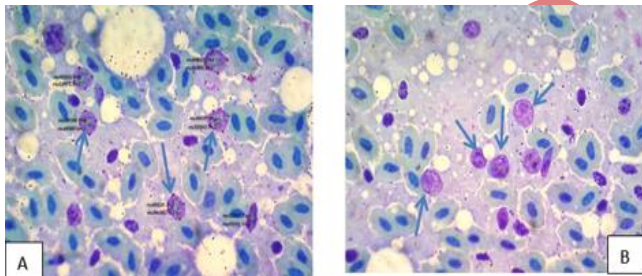


Figure 2: Impression smears showing different reproductive stages (blue arrow) of *Eimeria truncata* in duck's kidneys. (Giemsa stain, 1000X).

### Fecal examination

In geese fecal examination (flotation) for the detection of *Eimeria truncata* oocyst in geese showed that 16/70 (22.85%) were positive.

In ducks the fecal examination (flotation) for the detection of *Eimeria truncata* oocyst in ducks showed that 10/60 (16.66%) were positive (Table 4).

### Coccidian oocysts

The Coccidian oocyst identified in this study was *Eimeria truncata* depending on the oocysts morphology 9 for both geese and ducks (Figures 3,4). *Eimeria truncata* oocysts appear as ovoid to ellipsoidal, asymmetric with smooth walls and truncated narrow end.

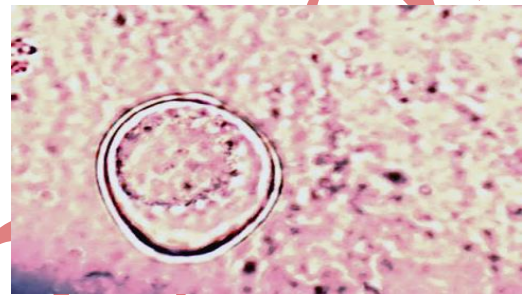


Figure 3: Unsporulated *Eimeria truncata* oocyst from kidney (H&E, 400X).

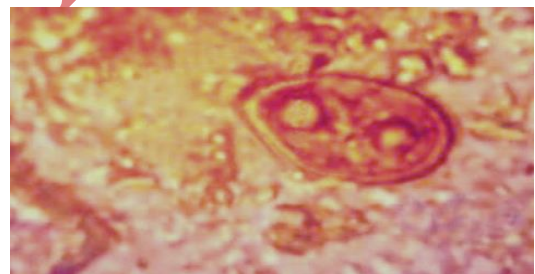


Figure 4: Sporulated *Eimeria truncata* oocyst isolated from the feces (400X).

### Histopathological measurements

In geese the dimensions of *Eimeria truncata* endogenous development stages in kidney impression smears, kidney histological sections, and urethra histological sections of infected geese were shown in 49 (70%) of tested geese (Table 2). All development stages were ellipsoids, ovoid, spherical or sub spherical in shape, being less in their width than their length. In duck the dimensions of *Eimeria truncata* endogenous development stages in kidney impression smears, kidney histological sections, and urethra histological sections 30 (51.66%) of infected ducks (Table 2). All development stages were ellipsoids, ovoid, spherical, or sub spherical in shape being less in their width than their length measurements.

Table 2: Measurements of *Eimeria truncata* developmental stages

	Score	Macrogamete		Microgamete		Schizont		Oocyst		
		Mean±SD	Rang	Mean±SD	Rang	Mean±SD	Rang	Mean±SD	Rang	
Kidney Impression	Duck	Length (μ)	7.2±1.51	5.5-11.5	5.6±1.02	4-7	8.4±2.73	5-12	6.6±1.18	5-8.6
		Width (μ)	6.3±1.24	3.5-9.6	5.6±7.83	3.3	7.7±2.68	4-10.6	3.5±0.63	2.5-4
	Geese	Length (μ)	7.6±1.97	6.1-9.6	5.6±0.77	4.4-7.4	6.9±0.94	6.3-8.1	7.1±0.37	6.8-7.7
		Width (μ)	7.0±0.64	7.2-9	4.7±0.61	3.9-5.7	6.1±0.80	4.2-7	3.2±0.38	3-4
kidney histological	Duck	Length (μ)	6.5±1.73	5-11.5	5.2±0.68	4.2-5.7	6.7±1.97	4.2-9.4	4.64±0.97	3.1-5.9
		Width (μ)	5.9±1.41	4.5-8.7	5.2±1.25	3.3-7.8	6.5±2.12	2.8-11	3.14±1.43	2.3-6.0
	Geese	Length (μ)	6.5±1.34	4.7-9.6	5.7±0.80	3.7-7.4	6.7±1.67	4.7-9.5	5.1±1.68	3-7.7
		Width (μ)	6.1±1.23	4-8.5	5.7±0.80	3-6.4	6.7±1.67	4.3-9.4	4.9±2.38	2.3-6.8
urethra histological	Duck	Length (μ)	5.5±0.61	4-6	4.8±0.48	4-5	5.4±0.48	5-6	5.0±0.47	4-8
		Width (μ)	4.2±0.61	3-5	3.6±0.48	3-4	4.8±0.48	4-5	3.3±0.47	3-4
	Geese	Length (μ)	4.6±0.41	4-5	3.8±0.43	3-4	4.7±0.69	4-6	5.5±0.44	5-6
		Width (μ)	4.8±0.40	4-6	4.6±0.41	4-5	5.0±0.53	4-6	4.0±0.44	3.5-5

### Histopathology findings in geese

Sections of geese kidney show the presence of reproductive stages of *Eimeria truncata* (Figure 5), vacuole in the epithelial cells (Figure 6) infiltration of inflammatory cells (Figure 7).

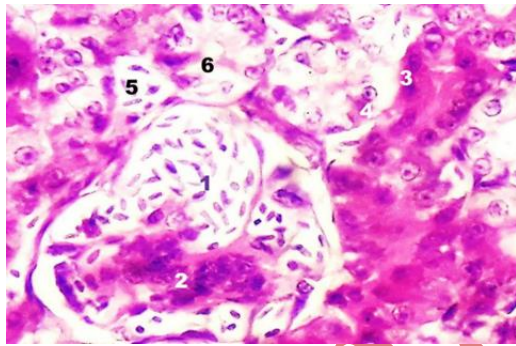


Figure 5: Section of geese kidney showed merozoites in glomerulus and tubule (1,5) shrinkage of glomerular lumen (2) coagulative necrosis in renal tubule (3) reproductive stages (4) narrowing of tubule lumen (6) (H&E. 1000X).

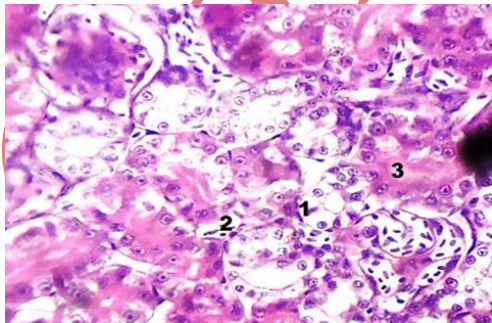


Figure 6: Section of geese kidney shows presence of vacuole (1) in the epithelial cells lining the renal interstitial tissue (2) coagulative necrosis (3). (H&E. 1000X).

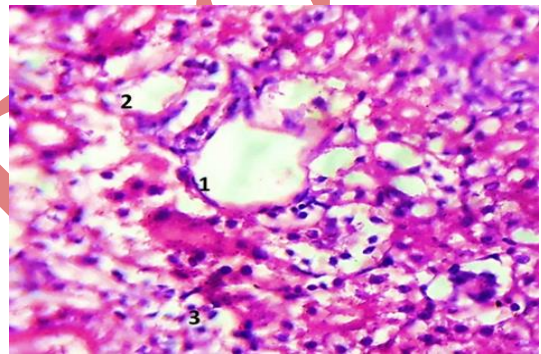


Figure 7: Histological section of geese kidney showing cystic kidney (1), necrosis of epithelial cell lining of renal tubules (2), infiltration of inflammatory cells (3). (H&E. 1000X).

### Histopathology findings in ducks

Histological sections of duck kidney show swelling, vacuole degeneration, coagulative necrosis of epithelial cell, shrinkage of Bowman's capsule, presence of hyaline cast, infiltration of inflammatory cells (Figures 8-10).

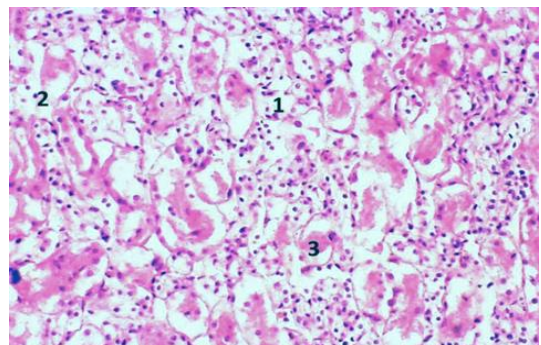


Figure 8: Section of duck kidney showing acute cell swelling (1), coagulative necrosis (2), hyaline cast (3). (H&E 400X).

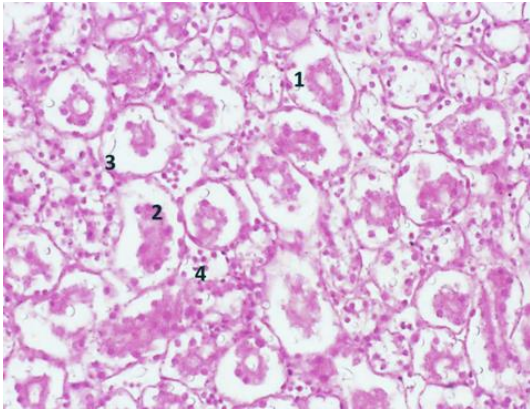


Figure 9: Histological section of duck's kidney showing coagulative necrosis of epithelial cells (1), and sloughing of these cells (2), detachment of basement membrane (3), infiltration of inflammatory cells (4), (H&E 400X).

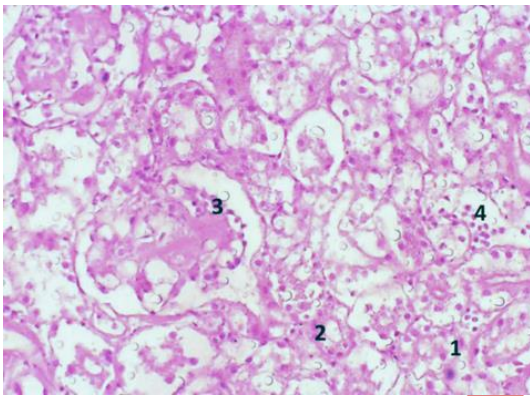


Figure 10: Sever coagulative necrosis of epithelial lining of renal tubules (1), hydropic degeneration of renal epithelial cells (2), necrosis of mesangial cells of glomerulus (3) and infiltration of inflammatory cells (4), (H&E 400X).

## Discussion

In Nineveh governorate, no attention has been paid for a long time to renal coccidiosis in geese and ducks despite its great economic importance due to the prophylactic and treatment measures, lowering bird's production and the mortalities it causes. No Previous study was accomplished about this subject here in the governorate, although renal and intestinal coccidiosis in both geese and ducks were reported all over the world (17). Intestinal coccidiosis was the only type reported here Al-Tae, *et. al*, (6). The significance of renal coccidiosis caused by *Eimeria truncate* in geese and ducks has been mostly related to the serious losses through kidney damage and mortalities, which may rise to 80-100% (18). The purchased geese and ducks assigned for the study were aged from 3 months and more, the most predicted age of goslings and duckling's infection with renal coccidiosis

(19). In Nineveh governorate, nesting geese and ducks are not practiced on a large scale. So morbidity and mortality percentages from the affected birds with renal coccidiosis could not be estimated or recorded. However, it still and should be regarded an important issue due to the easy way of oocyst transmission through the feed, water, litter, and soil since the purchased geese and ducks were from those fed on pasture and claimed to be suffered from malnutrition, exposition to many different parasitic infections and other concurrent diseases and immunosuppression. The rapidity of sporulation of unsporulated oocytes outside the body (approximately 3 days) after shedding from kidneys through ureters and passed via cloaca with feces increase the possibility of fecal contamination of these birds to get an infection on a wide scale, especially under the favorable environmental conditions of wet litter or soil and warm temperature 21-32°C, causing the high rate of deaths in goslings, ducklings, sub-adults and adult birds both accidentally or through breeding colonies (20) in addition to the role of persons, vehicles, wheels insects and others in transmitting infection (5).

The significance of their importance is their significant economic importance to the rural geese and duck's holders. Both type of birds, when attained for necropsy, were in poor performance, ruffled feathers, anemic, depressed, weakened, listlessness, anorexic, and so they experienced clinical infection since they suffered from whitish -yellowish diarrhea, the signs described by many others in ducks and geese infected with renal coccidiosis (21,22). These signs were at different severity among necropsied birds, agreed with the reports declared that renal coccidiosis is on one side asymptomatic disease in some birds, or may show minor physiological or pathological changes (23). Relatively few worldwide reports about heavy losses of renal coccidiosis in ducks comparing to those in geese (2). At necropsy, birds were emaciated with obvious changes in kidneys characterized by enlargement, extensively damaged, pale, containing discrete foci of infection that may coalesce into a mottled appearance. These changes were also mentioned by Gelberg (24). Our diagnosis of the disease was based on the described clinical signs, kidney lesions, impression smears, histological findings, and the shape of the fecal oocytes.

Although different species of *Eimeria* like *E. boschadi*, *E. somatarie* were reported (20,19), *Eimeria truncata* is one of the species that can be found in both geese and ducks (5), as we found here in our study with oocyst averaged 27.5\*17.5 µm, ovoid to ellipsoid in shape with smooth wall and narrow truncated ends. In spite that some authors reported about the uncertainty of renal coccidiosis in ducks, but Saif *et. al*, (2) and Fitz-Coy (5) noticed that *E. truncata* was isolated from renal coccidiosis of domestic ducks and geese. This is the first report of renal coccidiosis in geese and ducks caused by *Eimeria truncate* in Nineveh governorate. Another coccidian *Eimeria (Eimeria somateriae)* with mean dimensions of 33.5 by 14.8 µm was also reported in ducklings (19, 20), and

*Eimeria gaviae* with a mean diameter of 36.6 µm (15 measurements with a range of 30.3 to 40.1 µm) (25) compared to *Eimeria truncata*.

In this study, the prevalence of renal coccidiosis in geese and ducks were 70.00% and 51.66%, respectively, confirmed by kidneys necropsy and impression smears, compared to 22.85% and 16.66% by fecal flotation test. The incompatibility of these results confirmed by the findings of Gomis *et. al.*, (26) who stated that dropping examination is not a good indicator of the severity of renal coccidiosis infection in individual geese and ducks. The severity of renal coccidiosis may vary according to the level of infection, age, sex, the strain of the parasite or host, and even intercurrent infection (27). Our findings revealed that immature geese and ducks (< 6 months) showed to be more infected than adults (≥ 7 months), results confirmed by Benjamin and John (12), in that young birds are most likely to have clinical cases of renal coccidiosis (28). Regarding the gender of these birds in this study, the prevalence of infection with renal coccidiosis in females was higher than that of males, being 49% and 31% in geese and ducks respectively, 70% and 51% in their kidney impression smears, while the oocytes shedding was 22.85% and 16% respectively, compared to 6.8% in Canada geese from three locations in the Mississippi Flyway (12), 37.8% in Turkey (22), and 45.3% in Canada (9). The reason may be largely traced to the poor hygienic and nutritional conditions under which geese and ducks were confounded in our study. The histological sections of the infected bird kidneys in our sections showed eventually highly destructive changes due to *Eimeria truncata* parasite's presence and its different reproductive stages with numerous sloughed ureteral epithelial cells also described by Zachary (29,30). Histologic changes in kidneys in both bird species may predispose to rapid weight loss and emaciation, with high mortality percentages reaching up to 80 or even 100% reported in severe outbreaks by Saif *et. al.*, (2). It should be stressed that renal coccidiosis in Nineveh governorate imposes a serious threat to the domestic geese and duck's industry, and further studies should be carried out on the epidemiology of this protozoan parasite.

In domestic and wild ducks and geese (due to the less economic profit from wild types of them) and natural infections as those studies on protozoal infections accomplished in Iraq (31,32), for more understanding controlling this disease and other protozoal diseases (33).

## Conclusion

It could be concluded that ducks could also be infected with the same species of *Eimeria truncata* that affect geese.

## Conflict of interest

The author declares that he has no conflict of interest with regards to the manuscript

## Acknowledgments

I would like to thank the College of Veterinary Medicine for supporting, assisting, and providing space and facilities.

## References

1. Taylor MA, Coop RL, Wall RL. Veterinary parasitology. 4<sup>th</sup> ed. Oxford: Wiley Black Well; 2016. 259-276 p.
2. Saif AM, Barnes HJ, Fadly IS, Gilson JR, McDougall LR, Swayne DE. Diseases of poultry. 11<sup>th</sup> ed. USA: Iowa State Press; 2003. 880-883 p.
3. Levine ND. Veterinary parasitology. USA: Iowa state university press; 1985. 414 p.
4. Soulsby EJJ. Helminthes, Arthropods and protozoa of domestic animals. 7<sup>th</sup> ed. London: Bailliere Tindal; 1986. 763-772 p.
5. Fitz-Coy SH. Parasitic diseases. In: Boulianne M (ed). Avian histopathology. 7<sup>th</sup> ed. USA: American Association of Avian Pathologists. 2013. 479 p.
6. Al-Tae AF, Mohammed RG, Mohammed NH. Diagnosis of some helminthic eggs in feces of ducks and geese in Nineveh governorate, Iraq. Iraqi J Vet Sci. 2011;25(1):5-10. DOI: [10.33899/ijvs.2011.5696](https://doi.org/10.33899/ijvs.2011.5696)
7. Abdulla DA. Coccidiosis in domesticated ducks in Nineveh governorate. Iraqi J Vet Sci. 2010;24(2):149-153. DOI: [10.33899/ijvs.2010.5602](https://doi.org/10.33899/ijvs.2010.5602)
8. Bruno PB, Marcel T, Lopes CWG. *Tyzzzeria parvula* (Kotlan, 1933) Klimes, 1963 (Apicomplexa: Eimeriidae) in the greylag goose (*Anser anser* Linnaeus, 1758) in southeastern Brazil. Brazil J Vet Parasitol. 2007;16(3):156-158. DOI: [10.1590/S1984-29612007000300008](https://doi.org/10.1590/S1984-29612007000300008)
9. Gajadhar AA, Wobeser G, Stockdale PG. Coccidia of domestic and wild waterfowl (*Anseriformes*). Canad J Zool. 1983;61(1):1-24. DOI: [10.1139/z83-001](https://doi.org/10.1139/z83-001)
10. Wobeser G. Renal coccidiosis in mallard and pintail ducks. J Wild-life Dis. 1974;10:249-256.
11. Oksanen A. Mortality associated with renal coccidiosis in juvenile wild greylag geese (*Anser anser*). J Wildlife DIS. 1994;30:554-556. DOI: [10.7589/0090-3558-30.4.554](https://doi.org/10.7589/0090-3558-30.4.554)
12. Benjamin NT, John LC. Renal coccidiosis in interior Canada geese, *Branta canadensis* interior Todd, of the Mississippi Valley population. 1984;20(4):272-278. DOI: [10.7589/0090-3558-20.4.272](https://doi.org/10.7589/0090-3558-20.4.272)
13. Merck CO. The Merck Veterinary Manual. 8<sup>th</sup> ed. Meril: CRC press; 2008. 300 p.
14. Islam MR, Shaikh H, Baki MA. Prevalence and pathology of helminth parasites in domestic ducks of Bangladesh. Vet Parasitol. 1988;29(1):73-77. DOI: [10.1016/0304-4017\(88\)90009-X](https://doi.org/10.1016/0304-4017(88)90009-X)
15. Luna LG. Manual of histology staining methods of the armed forces institute of pathology. 3<sup>rd</sup> ed. New York: McGraw-Hill Book Co; 1968. 258 p.
16. Foreyt WI. Veterinary parasitology. 5<sup>th</sup> ed. USA: Iowa State University Press; 2001. 5-9 p.
17. Gajadhar AA, Wobeser G, Stockdale PG. Coccidia of domestic and wild waterfowl (*Anseriformes*). Canadian J Zool. 2011;61(1):1-24. DOI: [10.1139/z83-001](https://doi.org/10.1139/z83-001)
18. Bowman DB. Georgis' parasitology for veterinarians. 10<sup>th</sup> ed. St. Louis: Elsevier Saunders; 2014. 98-103 p.
19. Oksanen A. Mortality Associated with Renal Coccidiosis in Juvenile Wild Greylag Geese (*Anser anser*). J Wildlife Dis. 1994;30(4):554-6. DOI: [10.7589/0090-3558-30.4.554](https://doi.org/10.7589/0090-3558-30.4.554)
20. Mendenhall V, Milne H. Factors affecting duckling survival of eiders *Somateria mollissima* in northeast Scotland Ibis. Inter J Avian Sci. 2008;127(2):148-158. DOI: [10.1111/j.1474-919X.1985.tb05051.x](https://doi.org/10.1111/j.1474-919X.1985.tb05051.x)
21. Yabin Dai, Mei L, Nongyue H, Jianping T. The life cycle and pathogenicity of *Eimeria fulva* Farr, 1953 in domestic goslings. Acta Protozool. 2005;44(4):311-319. DOI: [10.1645/GE-476R1.1](https://doi.org/10.1645/GE-476R1.1)
22. Entzeroth R, Scholtyseck E, Sezen IY. Fine structural study of *Eimeria truncata* from the domestic goose (*Anser anser dom*) Z Parasitenkd. 1981;66(1):1-7. DOI: [10.1007/BF00941939](https://doi.org/10.1007/BF00941939)
23. Urquhart GM, Armour J, Duncan JL, Dunn AM, Jennings FW.

- Veterinary parasitology. 2<sup>nd</sup> ed. Oxford: Wily Black Well; 2003. 276-277 p.
24. Gelberg HB. Alimentary system and the peritoneum, omentum, mesentery, and peritoneal cavity. In: Zachary JF, ed. Pathological basis of veterinary disease. 6<sup>th</sup> ed. Philadelphia: Mosby Elsevier Inc; 2017. 382 p.
  25. Michael JY, Nicole LG, John RF. Description of a new *Eimeria* sp. and associated lesions in the kidneys of double-crested cormorants (*Phalacrocorax auritus*). J Parasitol. 2002;88(6):1230-3. DOI: [10.1645/0022-3395](https://doi.org/10.1645/0022-3395)
  26. Gomis S, Didiuk AB, Neufeld J, Wobeser G. Renal coccidiosis and other parasitologic conditions in lesser snow goose goslings at Thaanne River, west coast Hudson Bay. J Wildl Dis. 1996;32(3):498-504. DOI: [10.7589/0090-3558-32.3.498](https://doi.org/10.7589/0090-3558-32.3.498)
  27. Pellerdy LP. Coccidia and coccidiosis. 2<sup>nd</sup> ed. Berlin: Verlag Paul Parey; 1974. 155-374 p.
  28. Woolcock, BM. Diseases of the duck. In: Boulianne M (ed). Avian disease manual. 7<sup>th</sup> ed. Jacksonville: American Association of Avian Pathologists; 2013. 233 p.
  29. Zachary JF. Mechanisms of microbial infection. In: Zachary JF (ed). Pathological basis of veterinary disease. 6<sup>th</sup> ed. Philadelphia: Mosby Elsevier Inc; 2017. 237 p.
  30. Taha AM. Comparative histological and histochemical study of the ileum in two different birds. Iraqi J Vet Sci. 2021;35(3):479-487. DOI: [10.33899/ijvs.2020.127046.1447](https://doi.org/10.33899/ijvs.2020.127046.1447)
  31. Mohammad NH. Study on the blood protozoa in geese. Iraqi J Vet Sci. 2019;34(1):23-27. DOI: [10.33899/ijvs.2019.125499.1028](https://doi.org/10.33899/ijvs.2019.125499.1028)
  32. Mohammad ZA. Some chewing lice (Phthiraptera) species as ectoparasites infested aquatic birds with a new record of three species from Al-Sanah marsh/southern Iraq. Iraqi J Vet Sci. 2020;34(1):173-180. DOI: [10.33899/ijvs.2019.125499.1028](https://doi.org/10.33899/ijvs.2019.125499.1028)
  34. Al-Lahaibi BY, Hasan MH, Al-Tae AF. Incidence of internal parasites of the slaughtered local breeds of ducks and geese. Iraqi J Vet Sci. 2021;35(1):39-44. DOI: [10.33899/ijvs.2020.126242.1272](https://doi.org/10.33899/ijvs.2020.126242.1272)

## دراسة مسحية وتشخيصية لطفيلي الايميريا ترونكاتا في الإوز والبط

أحلام فتحي الطائي

فرع الأحياء المجهرية، كلية الطب البيطري، جامعة الموصل، الموصل، العراق



الخلاصة

يهدف البحث إلى تحديد مدى انتشار الاكريات الكلوية في كل من الإوز والبط المحلي في محافظة نينوى، العراق. إذ تم شراء مائة وثلاثين طير من كلا النوعين مع اختلاف الجنس والعمر من مناطق مختلفة في محافظة نينوى، خلال الفترة من ٢٠١٧ إلى ٢٠١٨. كانت الإصابة الإجمالية للإوز والبط حسب أعمارهم ٧٠,٠٠% و ٥١,٦٦% على التوالي، حيث بلغت للأعمار اقل من ٦ اشهر ٧٤,٣٥% للإوز و ٥٣,١٩% للبط على التوالي بينما بلغت ٦٤,٥١% و ٤٦,١٦% لكليهما عند عمر ٧ شهور فأكثر. أظهر توزيع الإصابة بالاكريات الكلوية في كلا الجنسين أن ٧٥,٥٥% و ٥٤,٥٠% من إناث الإوز والبط، و ٦٠,٠٠% و ٤٧,٨٢% من ذكور الإوز والبط كانت موجبة على التوالي. أظهر مسح طبعات أنسجة الكلى بوجود طفيلي الايميريا ترونكاتا في ٤٩ (٧٠%) للإوز بينما كانت موجبة ٣١ (٥١,٦٦%) للبط. تم فحص عينات البراز للكشف عن أكياس البيض لطفيلي الايميريا ترونكاتا بتقنية الطفو وأن ٢٢,٨٥% كانت موجبة للإوز و ١٦,٦٦% للبط. تم قياس أبعاد مراحل تطور الايميريا ترونكاتا (المفلوقات، الأمشاج الكبيرة، الأمشاج الدقيقة وأكياس البيض). أظهرت المقاطع النسيجية لكليتي الإوز والبط المصاب بوجود مراحل تكاثر الطفيلي الايميريا ترونكاتا المختلفة مع تغييرات مرضية عديدة.

Galley