



Effect of Oregostem[®] and imbalance diet on body performance and reproductive efficiency in male quails

H.N. Maty¹, M.S. Al-Maatheedi¹ and S.M. Ahmed¹

Department of Physiology, Biochemistry and Pharmacology, College of Veterinary Medicine, University of Mosul, Mosul, Iraq

Article information

Article history:

Received October 28, 2020
Accepted January 23, 2021
Available online October 13, 2021

Keywords:

Oregostem[®]
Spermatogenesis
Hematology
Low protein diet
Male quails

Correspondence:

H.N. Maty
hemyatem@yahoo.com

Abstract

This study was aimed to determine the influence of Oregostem[®] and imbalance diet on body performance, hematology and spermatogenesis of male quails. A total of 160 birds have been distributed into four groups (40 birds) each with 2 replicates starting at 12 weeks of age, the four treatments includes: G1 was fed on balanced diet only. G2 was received a balanced diet with Oregostem[®] with drinking water. While G3 was fed on imbalance diet (ground yellow corn) and G4 received imbalance diet with Oregostem[®]. The parameters including body performance, reproduction, blood and biochemical Figure and histology of testes were measured at 4th and 8th weeks from beginning of treatment. The results showed that the supplementation of Oregostem[®] caused a significant increase in body and right testis weight, gonadosomatic index, sperm count as well as live sperm in G2 relative to other groups at 4th and 8th weeks post treatment. In G3, WBC and lymphocytes decrease significantly with increasing heterophils percentage and stress index at 4th and 8th weeks post treatment. Also there was a significant decrease of cholesterol with an increase of total protein and creatine kinase in G3 at 8th week of treatment. While the groups treated with Oregostem[®] did not differ from control group. This study concluded that liquid form of Oregostem[®] had a positive effect on body weight, sperm count with improvement hematological and biochemical parameters of the male quails.

DOI: [10.33899/ijvs.2021.128810.1602](https://doi.org/10.33899/ijvs.2021.128810.1602), ©Authors, 2022, College of Veterinary Medicine, University of Mosul.
This is an open access article under the CC BY 4.0 license (<http://creativecommons.org/licenses/by/4.0/>).

Introduction

Japanese quail Belongs to the family Phasianidae and considered as pheasant birds (1). Males of Japanese quail have highly breeding activity during the summer, particularly when the size of the testes is increase and concentration of testosterone reaches to the peak. Therefore the production and reproduction of quail are very important because has play an active role in industry and scientific researches (2). Oregostem[®] is the 100% natural feed additive characterized by special aromatic flavor, used globally in livestock diets to improve overall function in the body such as it promotes growth and improve utilization of the feed and make the animals healthier as well as give in the times of stress. Oregostem[®] is obtained from the

oregano plant, a perennial herb of the mint family grown in colder condition. Tastes range from spicy or maybe astringent and sweet. Active ingredients of it (thymol and carvacrol) that have antiseptic antimicrobial (3), antioxidant, antiviral properties and in addition to immunomodulatory effect (4). The oregano is contributing to protecting the intestine against gram-negative and gram-positive bacteria and other physiological effects because the presence of phenolic acids, and flavonoids as main compounds of it (5,6). As well as it has been revealed anti-inflammatory action by activation of the immune system, Therefore Oregano considered as prophylactic plans against intimidating pathogens (7). Also, the oil of oregano has shown optimistic effects on microbes. Thus, recently, it is applied as substitute to antibiotics in animal diet to avoid

the antibiotic resistance of microorganisms (8). The oregano has more than 20 ingredients but the phenolic component has antioxidant properties, it is possible to transfer of antioxidant components in to the body by feeding hens with oreganum because the phenolic component act to inhibit the chain reaction associated with lipid oxidation (9). Oregano has to show andrological properties by precautionary effects against testicular destruction and recovered full spermatogenesis and spermatozoa creation within one full spermatogenic maturation cycle (10). To overcome the physiological and chemical stress on the sperm membrane when is cryopreservation of semen, the researchers suggested adding different concentrations from *Origanum Vulgare* to semen samples that play crucial role as antioxidants to improve sperms quality, motility, viability and plasma membrane integrity of sperms as well as significantly decreased the lipid peroxidation (11). In one of recent study on poultry demonstrated, the supplementation of oregano improved the gut health that can make energy reserves for reproductive processes by reducing animal stress, in cooperation of these two reasons which may lead to increasing fertility. Thus consequently, improving productive and reproductive performance traits, egg quality, semen quality and has positive effects on some physiological effects during the laying period (12). Therefore, this work was aimed to assess the efficacy of liquid form of Oregostem® (is a high quality eubiotic composed of 100% natural) on the productive and reproductive performance of male quails as well as suggest to reduce stressful condition and improve profitability.

Materials and methods

The experimental design and the use of male quails for this study have been studied by the Department of Physiology, Biochemistry and Pharmacology Scientific Committee and Veterinary Medicine College, University of Mosul.

Birds

The study was presented in the Laboratory Animal House, College of Veterinary Medicine, University of Mosul. The quails were housed in horizontally isolated floor pens in order to prevent interference. The room temperature ranged from 20±5°C and the relative humidity ranged from 45% to 60%. During the rearing and development cycles (8 weeks) clean drinking water ad libitum basal diet ingredient and nutrient levels provided according to National Research Council (NRC) recommendation (13). The experiment designed to include 160 male quails starting at 12 weeks of age. Quails have been obtained from the Ebaa Research Center/Ministry of Agriculture. And randomly distributed into four groups (40 birds / group) each with 2 replicates and divided in to four

treatment Includes: (G1) was fed on balanced diet only (Table 1) (G2) was receiving a balanced diet with Oregostem® by drinking water (Dosage:0.3 ml \ L), while G3 was fed on imbalance diet (ground yellow corn only) and G4 received imbalance diet with Oregostem®. All groups were treated until 8th weeks from beginning of the experiment and parameters were measured at 4th and 8th weeks of experiments.

Table 1: Percentage of balanced diet contents

Contents	Grower %	Production %
Yellow corn	36	42
Wheat	22	22
Soya bean meal 44%	35	30
Concentrated protein 40%	5	4
Sunflower oil	1	1
Calcium phosphate	0.7	0.7
Salt	0.3	0.3
Total	100%	100%
Calculated energy		
Metabolic energy	2821.8	2985.1
Kcal/kg of diet	24.270	21.998
Crude protein %	3.975	3.650

Oregostem®

A liquid product containing 100% natural oregano essential oil produced by Anpario company /UK. Oregostem® administrated with dosage of 300 ml/1000 litter of drinking water as a recommendation of manufacturer.

Body weight and internal organs weight

Birds were slaughtered at the end of 4th and 8th weeks of the experiment respectively. Visceral organs, including the heart, liver, gizzard, chest muscle, and testes, were weighted (records of organ weight/100 gm body weight).

Blood samples

Blood samples were collected during slay and divided into two parts: one for serum that separated by blood centrifugation for 15 min at 3000 rpm and kept at -26°C until further processing of biochemical parameters that included: cholesterol, total protein and creatinine kinase using commercial kits (Biolabo/France) (14), While blood samples with anticoagulant were used for complete blood count by using Wright stain to estimate RBCs, WBCs, differential leukocytic count (DLC) by using Natt and Herrick solution and for concludes stress index.

Spermatogenesis parameters

Which include number of live, dead and abnormal sperms. The epididymis male quails were removed, crushed and homogenized in 1 ml 0.9% NaCl according to the protocol described by (15). The final volume obtained by

counting the total number of sperm from epididymis and the number of sperm \cubic mm was performed using a Neubauer chamber under an optical microscope with 40 X magnification.

Evaluation of sperm viability

The morphology of spermatozoa was studied in nigrosine-eosin smears under a light microscope to evaluate the percentage of normal and abnormal sperms. The ducts deferens were rinsed with 1mL 0.9% NaCl and a sperm suspension was subsequently obtained. An aliquot of sperm suspension was stained with 2% eosin and nigrosine to assess the percentage of morphologically abnormal sperm. Two hundred sperm/animal were analyzed microscopically (X 400 total magnification) (15).

Gonadosomatic index (GSI)

In male quails, in order to determine GSI, the weight of the right and left testes of each quail was divided to the body weight of the bird and the calculation of gonadosomatic index according the equation (16). $GSI = [gonads\ weight/body\ weight] \times 100$. This index used to determine the sexual maturity of bird and testes development as well as used as indication of endocrine function (17).

Histological examination of the quail's testis

After separating the testes from the bird's body, testes were instantly preserved in sufficiently buffered formalin

10 % for fixation its structure. Then, the testes were embedded into paraffin wax for 24 hrs. The thin sections was obtained after slicing by microtome after that floated on the water bath, shifted by a glass slide, dried and dyed with hematoxylin and eosin stains. The slide was then observed under a light microscope (Olympus-CX3) to assessment of the morphometric changes (18).

Statistical analysis

Data is determined by means of one-way analysis of variance (ANOVA). The significance of variations among means was assessed by using the Duncan Multiple Range Test (P<0.05) (19).

Results

The experimental results logged in table 2 of the present study indicated that the effect of Oregostem® produced a significant raise in body weight (P<0.05) in G2 when compared with G3 and did not differ significantly from G1 and G4 at 4th, 8th weeks respectively. The heart weight showed significant decreased in G3 relative to G1, G2 and G4 at 4th weeks of treatment as well as in G3 and G4 relative to G2 and at 8th weeks and not differ from control group. There is no significant change in liver weight between groups at 4th and 8th weeks of treatment. Also the gizzard and chest muscles weight no significant change among the groups at 4th weeks, but at 8th weeks decreased significantly (P<0.05) in G3 compare with G1, G2 and G3.

Table 2: Impact of Oregostem® and imbalance diet on male quail's body and organs weight

Groups	Age after treatment	Mean (g) ± SE				
		body weight (g)	Heart weight g/100 g.bw	Liver weight g/100 g.bw	Gizzard g/100 g.bw	Chest weight g/100 g.bw
G1	4	179.80±4.48ab	0.094±0.04a	1.43±0.08a	1.77±0.13a	22.12±0.53a
	8	190.00±5.64ab	0.93±0.02ab	1.51±0.10a	1.83±0.04a	25.84±1.09a
G2	4	193.20±6.31a	0.89±0.04a	1.36±0.04a	1.69±0.09a	23.16±0.42a
	8	193.40±4.76a	1.06±0.06a	1.37±0.06a	1.83±0.05a	25.01±1.04a
G3	4	174.80±3.26b	0.77±0.02b	1.31±0.04a	1.48±0.14a	21.69±0.62a
	8	177.20±2.95b	0.84±0.05b	1.55±0.05a	1.55±0.15b	20.68±1.79b
G4	4	186.80±2.41ab	0.93±0.03a	1.40±0.03	1.69±0.03a	22.24±1.79a
	8	185.80±4.22ab	0.85±0.07b	1.30±0.07a	1.86±0.07a	24.76±1.22a

Values in the column with different letters are significantly different at P<0.05.

Administration of the Oregostem® showed no any significant (P>0.05) changes in the weight of the left testis in comparison with other groups at 4th and 8th weeks of treatment; whereas the weight of the right testis significantly increased in G2 relative to G3 but at a same time did not differ from G1 and G4 at 4th weeks of treatment. In 8th weeks no significant change in the right testis weight between groups. The data indicated a significant increase in the GSI in G2 and G4 relative to G3; whereas these groups did not differ about G1 at 4th weeks of

treatment, also the data of GSI at 8th weeks not record any significant differences between groups (Table 3).

Table 4 showed that administration of Oregostem® resulted in a significant increase in of sperm count (P<0.05) in G2 relative to G1, G3 and G4 at 4th weeks; while at 8th weeks the sperm count increased clearly in G4 as compare with other groups. It was the highest value of live sperm count, and lowest value in dead sperm in G1 and G2 relative to other groups, while G3 showed significant reduction in live sperm with increased in dead sperm at 4th

weeks of treatment, but at 8th weeks there was a clearly reduction of live sperm with highest value of dead sperm in G3 relative with other groups. No significant difference

(P>0.05) between groups in sperm abnormality at 4th weeks of treatment, but at 8th weeks showed high significant value in G3 relative to G2 and G4 while did not differ from G1.

Table 3: Impact of Oregostem[®] and imbalance diet on sex organs weight of male quail's

Groups	Age after treatment	Mean ± SE		
		Left testis weight g/100 g.bw	Right testis weight g/100 g.bw	Gonadosomatic index
G1	4	1.10±0.03 a	1.28±0.06 ab	2.38±0.09 ab
	8	1.31±0.18 a	1.35±0.18 a	2.67±0.34 a
G2	4	1.21± 0.06 a	1.31±0.03 a	2.52±0.09 a
	8	1.14±0.12 a	1.34±0.11 a	2.48±0.23 a
G3	4	1.06±0.09 a	1.03±0.08 b	2.10±0.10 b
	8	1.22±0.17 a	1.40±0.18 a	2.62±0.35 a
G4	4	1.02±0.08 a	1.17±0.12 ab	2.20±0.19 a
	8	1.17±0.15 a	1.50±0.22 a	2.70±0.37 a

Values in the column which use different letters are significantly different from P<0.05.

Table 4: Impact of Oregostem[®] and imbalance diet on male quail's spermatogenesis

Treatment	Age after treatment	Mean ± SE			
		Sperm conc. × 10 ⁶	Live sperm %	Dead sperm%	Abnormal sperm %
G1	4	2.68±0.31b	78.40±4.19a	22.00±4.00c	4.80±1.01a
	8	2.91±0.17ab	82.60±4.00a	22.80±3.00b	5.20±1.28ab
G2	4	3.31±0.09a	78.20±3.62a	21.80±3.62c	4.40±0.87a
	8	2.52±0.36ab	77.80±4.47a	16.00±4.67b	3.60±0.81b
G3	4	1.95±0.12c	50.20±5.05c	49.80±5.05a	5.00±1.37a
	8	2.23±0.17b	53.60±4.36b	46.40±4.36a	8.20±2.08a
G4	4	2.03±0.05c	64.40±4.10b	35.60±4.10b	4.40±1.24a
	8	3.14±0.28a	83.20±2.41a	16.80±2.41b	2.20±0.58b

Values in the column which use different letters are significantly different from P<0.05.

The microscopic examination of control group at 4th and 8th weeks showed normal seminiferous tubules with spermatogenesis, normal interstitial tissue, Sertoli cells with the normal distribution of the spermatid, spermatocyte and spermatogonium at different differentiation stage (Figure 1A). While treated groups with Oregostem[®] at 4th and 8th weeks showed no any obvious histological lesions (Figure 1B). In (Figure 1C) the testicular section appearance under microscope of the groups fed with yellow corn and treated with Oregostem[®] in the two different time of period, the experiment reorganization of seminiferous tubules with dilation of tubular lumen which appear free form of spermatid and spermatocyte. But (Figure 1 D and E) showed the section of testis below the lens of microscope on the groups fed just of the yellow corn thickening of tunica albuginea with sever congestion and thickening of blood vessel wall in the interstitial tissue. However different degree of histological changes in the seminiferous tubules was observed, these changes characterized by degeneration of the spermatocytes, sloughing of sertoli cells, furthermore destruction of basement membrane of some seminiferous tubules with distortion of shape.

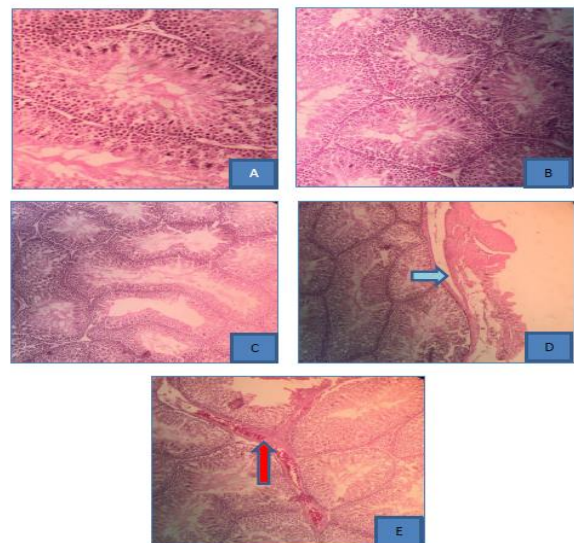


Figure 1: A control group, B treated groups with Oregostem[®], C groups fed yellow corn and treated with Oregostem[®], D and E fed yellow corn.

The data from the current study at 4th weeks showed no any significant ($P>0.05$) changes in the RBC count among groups; while WBC count diminished in G3 and G4 when compare with G1 and G2, as well as reduced percentage of lymphocyte in G3 relative to G1, G2 and G4, but at 8th weeks showed a significant decrease in counts of RBC, WBC and lymphocyte percentage in G3 relative to G1, G2 and G4. While heterophils and stress index increased significantly in G3 relatively to other groups at 4th and 8th weeks. There is no significant difference between groups in the basophils, eosinophil and monocytes in table 5 at 4th and 8th weeks post treatment.

The effect of the dietary additive of Oregostem[®] on biochemical parameters in quails is summarized in table 6. A significant decrease ($P<0.05$) in cholesterol level was

observed in G3 compared with G1, but did not differ from G2 and G4 at 4th weeks of treatment. On the other hand, administration of liquid form of Oregostem[®] for 8th weeks was showed no significant variation ($P>0.05$) in cholesterol level between groups. Furthermore, the administration of Oregostem[®] additives was effect noticeably influence ($P<0.05$) by increasing in the total serum protein level of G4 relatively to G1 and G2 as well as not differ from G3 at 4th weeks, but after at 8th weeks of treatment resulted in a significant rise ($P<0.05$) in the total protein in G3 related to the other groups. The creatine kinase value showed high significant increasing value ($P<0.05$) in G3, and less in G4 but the least in G2 when compare with G1 at 4th weeks. While at 8th weeks has risen significantly in G3 relatively to G1, G2, G4 and G4 relative to G2.

Table 5: Impact of Oregostem[®] and imbalance diet on blood constituent, differential leucocytic count and stress index

Group	Age	Mean ± SE							
		RBC. × 10 ⁶	WBC × 10 ³	Lymphocyte %	Heterophils %	Basophil %	Eosinophil %	Monocyte %	Stress index
G1	4 weeks	3.08 ±0.09a	4.01 ±0.14a	73.80 ± 4.06a	14.80 ± 2.35bc	0.60 ±0.40a	1.20 ±0.37a	12.00 ±0.63a	0.20 ±0.04b
	8 weeks	3.04 ±0.16a	4.33 ±0.20a	71.40 ±3.78a	13.6 ±1.86b	0.80 ±0.37a	0.60 ±0.40a	13.60 ±1.53a	0.19 ±0.39b
G2	4 weeks	3.00 ±0.10a	4.17 ±0.09a	69.60 ± 3.07a	16.20 ± 1.88b	0.60 ±0.24a	1.20 ±0.48a	12.40 ±1.56a	0.23 ±0.03b
	8 weeks	3.02 ±0.27a	4.17 ±0.05a	73.20 ±3.54a	11.2 ±2.22b	0.80 ±0.20a	1.40 ±0.40a	13.40 ±1.80a	0.15 ±0.04b
G3	4 weeks	2.41 ±0.02a	3.34 ±0.19b	47.40 ± 3.10b	32.60 ± 2.76a	1.80 ±0.48a	2.40 ±0.24a	12.40 ±1.02a	0.71 ±0.01a
	8 weeks	2.20 ±0.22b	3.08 ±0.18b	42.20 ±3.86b	41.2 ±2.95a	1.00 ±0.31a	1.40 ±0.24a	13.40 ±1.74a	1.02 ±0.15a
G4	4 weeks	2.67 ±0.21a	3.50 ±0.16b	71.40 ± 2.99a	9.20 ± 1.68c	1.40 ±0.40a	1.80 ±0.37a	12.60 ±0.92a	0.12 ±0.02b
	8 weeks	3.10 ±0.14a	4.36 ±0.08a	74.00 ±3.57a	12.8 ±0.37b	0.80 ±0.37a	0.80 ±0.48a	11.60 ±1.46a	0.17 ±0.03b

Values in the column which use different letters are significantly different from $P<0.05$.

Table 6: Impact of on Oregostem[®] and imbalance diet on biochemical parameters of male quail's

Treatment	Age after treatment	Biochemical parameters		
		Cholesterol mg /dl	Total proteins g/dl	Creatine kinase IU/L
G1	4	386.76±23.67 a	3.69±0.10 b	234.54±10.22 c
	8	315.37±18.47 a	4.15±0.28 b	269.26±14.5 b
G2	4	301.64±31.86 ab	3.77±0.19 b	176.84±17.46 d
	8	358.11±4.63 a	4.17±0.16 b	221.36±4.97 c
G3	4	242.64±36.85 b	4.22±0.24 ab	365.46±16.15 a
	8	368.29±40.36 a	5.39±0.14 a	365.46±16.51 a
G4	4	318.64±30.69 ab	4.52±0.11 a	292.44±13.09 b
	8	364.70±21.17 a	4.41±0.29 b	292.44±13.09 b

Values represented as means ± SE. Values using different letters in the column are significantly different ($P<0.05$)

Discussion

The illation of the recent study was seen that the groups received Oregostem® in the drinking water in the prompted an elevation in body weight at 4th and 8th weeks of treatment, this was agreed with the findings of the supplementation Oregostim® on finisher broiler, regardless about if in the diet or in the drinking water increases the weight of the body, weight gain and detracting the feed conservation ratio (FCR) and mortality rate (20). Oregostem® has a unique property that possess natural phenolic compounds (carvacrol and thymol), which is a powerful antimicrobial agent because Phenols can consider as a slayer of bacteria like *C. perfringens* out of its toxic effect on the protein of the bacterial cell membrane, via denaturing and coagulating of protein in the cell membrane, and therefore the permeability of the bacterial cell membrane will be increased to perform in water thus lead bacterial cell die (21). Or maybe the effect of carvacrol and thymol on digestibility of food, probably due to the enhancement of digestive enzymes by accelerate blood flow (22). Also the current study noticed that the submit yellow corn to quails induced a reduction in body weight, and some organs weight this finding did harmony with the evident scientific findings that indicated the final body weight, weight gain of quail were significantly fall but the feed intake was significantly increased with deficient dietary crude proteins level from 24-20% (yellow corn have low protein proportion), Therefore this is a reason is to show of those results in minimize the proficiency of feed utilization for quail when fed with lower dietary protein level (23). In accordance with the present results shows that the andrological effect of Oregostem® on spermatogenesis regardless of the difference in the time period to give it resulted in elevated of sperm count and percentage of live sperm as well as right testes and gonadosomatic index that used as decent marker for gonadal growth at 4th weeks with decreasing of dead sperm percentage while not affected on sperm abnormality, this research did comply with El-Sawy *et al.* (10), which announced that oral administration of *Origanum* (20 mg/kg) to adult male rats caused increasing number of the sperm, testicular weigh and diameter of seminiferous tubules and the reasons may be the oregano contains carvacrol which plays an antioxidant effects and an anti-apoptotic properties of the sperm cells by acting on repressing expression of P53 protein (24). Also may be attendance of a particular prevalent protein in the epididymal environment that was recognized as hemoglobin which assists sperm metabolism, motility, and/or performance as an antioxidant (25). Moreover, in the recent research improved that thymol have protective role of the testes and testes function (sperm production) by positive effect on Epididymal sperm parameters, testicular histology, and spermatogenesis (26). While Güvenç *et al.* (27) concerning the sperm quality parameters (motility,

concentration, sperm abnormality and live/dead sperm proportion) the carvacrol and thymol have positive influence but at a same time no significant result on the histological evaluation of the animals testis when compare with control groups. The decrease in semen production, live sperm and on the other hand increased dead sperm and abnormality of male's quails in groups that fed on yellow corn maybe due to numerous stresses in poultry such as imbalance diet responsible for decreasing body weight and caused economically loses due to decreased productive and reproductive performing of growing bird associated with excess production of free radicals (28). Hematological and biochemical parameter are an influential tool for evaluating the health and reproduction status of birds as physiological markers, since it essentially indicates the condition of the internal bird environment (29), therefore findings demonstrate that RBC, WBC, lymphocytes, heterophils and stress index of treated groups with Oregnum are similar with control groups at 4th and 8th weeks. Similarly, Silva-Vázquez *et al.* (30) that conclude revelation the positive effect of two type of oregano oils at 0.40 g/kg in the diet on broiler blood Figure specially leukocytes and lymphocytes percentage without changing hemoglobin and hematocrit and oregnum acts as a replacement to artificial antioxidants. Another researcher improved significantly the value of hemoglobin and percentage of lymphocytes on broiler that treated with oregano, because thyme have high concentration of iron to stimulate hemoglobin production, also occurrence flavonoids which have antioxidant properties that able to improve of blood figure (31). The proportion of lymphocytes in this experiment did not differ in G1, G2 and G4 in line with the results of Savoini *et al.* (32), who reported that lymphocytes were increased in piglets when fed by 300 mg/kg of oregano extracts, the increase of some WBC differential values are an indicator for the non-specific stimulation of cellular immunity and demonstrates that the influence of immune response can be determined in any case by the recorded parameters of the blood picture. Or, possibly due to their antioxidant activity of the oregano extract. Also, Flavonoids, which are found in oregano have been shown to promote phagocytic activity (33,34). Vs. versa, Méndez-Zamora *et al.* (35) discovered no influence on biometric parameters of the blood with 0.40 g/kg diet of oregano. While when offer yellow corn to G3 at 4th weeks resulted diminish blood leukocytes and percentage of lymphocytes in contrast raises in heterophils and heterophilic / lymphocyte proportion at 8th weeks that often used as a stress marker for birds (36). Some investigators have described the effect of malnutrition on the hematological profile of mammals and some avian *spp.* (36) when resulted that significant diminished on most of blood leukocytes percentage except heterophils and stress index rises significantly at end of experimental period. These results confirm the chickens are recompensed with elevated non-specific immune element (heterophils) and

stress index heterophils/lymphocytes ratio. Azis (37) showed that malnutrition evokes stress on blood cells. While the percentage of packed cell volume in chickens not affected when offer unbalance diet at 14, 35 day of age (36). According to the biochemical analysis, supplemented yellow corn alone without any treatment (G3) caused a significant decrease in cholesterol level just at 4th weeks from beginning the experiment, furthermore elevated in creatine kinase at periods of the experiment and total protein at 8th weeks but at 4th weeks the total protein raises in G4 (fed yellow corn and supplement with Oregostem[®]), but treated group with Oregostem[®] did not differ from control group. This result is harmonious with a preceding study recorded by Mert and Yildirim (38). One of the negative effects of under nutrition is body weight loss, diminishes in antioxidant levels and elevated of the total protein as a result of stress. The increased level of the total protein in G4, maybe caused by thymol that credited to a direct effect on protein metabolism related to the immune system (39). While the study conducted by the researchers is compatible with the results of the current research, as it was observed that the level of cholesterol and triglyceride clearly decreased in the group that was subjected to diet supported with Lignocellulose at the dose of 1.0% and 0.5 (yellow corn have high percentage of cellulose) in chickens compared with the non-treated group (40). Nevertheless, high levels of creatine kinase in serum are still strictly concomitant with cell hurt, and muscle cell disorder. Likewise, the birds when supplementing an unbalanced diet, these cellular disturbances can cause this enzyme to escape from cells into blood plasma (41). The results got in the current study are disagree with Abd El-Hady *et al.* (31) who reviewed the influences of nourished diet encompasses with oregano to the broiler chicks had significant differ from control groups of total protein with a diminution of cholesterol in treated group with oregano relative to control groups. The reason suggested that the influence of oregano on metabolism of protein may be associated to enhancement of intestinal amino acids absorption in acidic environments that subsequently improves protein creation, or the elevation level of albumin has been sign of the protein retention in the body. Mansoub and Myandoab (42) Mentioned that the level of triglycerides and cholesterol in the serum are decreased because of the provider of thyme extraction in the chicken diet at dose of 200 - 500 ppm may participate to inhibit absorption of cholesterol from intestine. Hong *et al.* (43) improved that 1g/kg thyme when fed of Japanese quail reduce the cholesterol and triglycerides, because thymol and carvacrol have been testified to possessions a cholesterol lowering ability by preventing hepatic 3-hydrox-3-methylglutaryl coenzyme A-reductase, which is a key enzyme in cholesterol synthesis. In contrariwise, Demir *et al.* (44) described that additional 1g/kg origanum to broiler diet significantly raises cholesterol and triglycerides level. Finally, thymol was

more effective for lowering the level of creatine kinase than carvacol, but a synergistic effect of these two components may be credited to antiapoptotic, antioxidant, and ant inflammatory activities (45).

Conclusion

This study concluded that liquid form of Oregostem[®] had a positive effect on body weight, sperm count with improvement hematological and biochemical parameters of the male quails.

Acknowledgments

The Authors thank the College of Veterinary Medicine, University of Mosul for supporting this work.

Conflict of interest

No conflict.

References

1. Awad A, Khalil SR, Abd-Elhakim YM. Molecular phylogeny of some avian species using Cytochrome b gene sequence analysis. Iranian J Vet Res. 2015;16:218-222. DOI: [10.22099/IJVR.2015.3072](https://doi.org/10.22099/IJVR.2015.3072)
2. Ottinger MA, Abdelnabi M, Li Q, Chen K, Thompson N, Harada N, Viglietti-Panzica C, Panzica GC. The Japanese quail: a model for studying reproductive aging of hypothalamic systems. Exp Gerontol. 2004;39:11-12:1679-93. DOI: [10.1016/j.exger.2004.06.021](https://doi.org/10.1016/j.exger.2004.06.021)
3. Gholami-Ahangaran M, Peimani N, Ahmadi-Dastgerdi A. The effect of thyme (*Thymus daenensis*) supplement on growth and hygienic parameters of broilers meat. Iraqi J Vet Med. 2019;33(1):87-92. DOI: [10.33899/ijvs.2019.125526.1048](https://doi.org/10.33899/ijvs.2019.125526.1048)
4. Al agawanty M, Abd El-hack ME, Farag MR, Shaheen HM, Abdelatif MA, Noreldin AE, Patra AK. The usefulness of oregano and its derivatives in poultry nutrition. World's Poult Sci J. 2018;74(3):463-474. DOI: [10.1017/S0043933918000454](https://doi.org/10.1017/S0043933918000454).
5. Mathlouthi N, Bouzaïenne T, Oueslami I, Recoquillay F, Hamdi M, Urdaci M, Bergaoui R. Use of rosemary, oregano, and a commercial blend of essential oils in broiler chickens: In vitro antimicrobial activities and effects on growth performance. J Anim Sci. 2012;90:813-823. DOI: [10.2527/jas.2010.3646](https://doi.org/10.2527/jas.2010.3646)
6. Zhang XL, Guo YS, Wang CH, Li JQ, Xu JJ, Chung HY, Ye WC, Li YL, Wang GC. Phenolic compounds from *Origanum vulgare* and their antioxidant and antiviral activities. Food Chem. 2014;152:300-306. DOI: [10.1016/j.foodchem.2013.11.153](https://doi.org/10.1016/j.foodchem.2013.11.153)
7. Fang SC, Hsu CL, Yen GC. Anti-inflammatory effects of phenolic compounds isolated from the fruits of *Artocarpus heterophyllus*. J Agric Food Chem. 2008;56:4463-8. DOI: [10.1021/jf800444g](https://doi.org/10.1021/jf800444g)
8. Zhai HX, Liu H, Wang SK, Wu JL, Klunter AM. Potential of essential oils for poultry and pigs. Anim Nutr. 2018;4:179-186. DOI: [10.1016/j.aninu.2018.01.005](https://doi.org/10.1016/j.aninu.2018.01.005)
9. Florou-Paneri P, Dostas D, Mitsopoulos I, Dostas V, Botsoglou E, Nikolakakis I, Botsoglou N. Effect of Feeding Rosemary and α Tocopheryl Acetate on Hen Performance and Egg Quality. J Poult Sci. 2006;46(52):143-149. DOI: [10.2141/jpsa.43.143](https://doi.org/10.2141/jpsa.43.143)
10. Elsayy NA, Abdullah Alkushi AG, Mohamed A, Sakran ME. Does oregano protect against testicular toxicity produced by ethylene glycol in adult male albino rat. Inter J Morphol. 2019;37(1):358-362. DOI: [10.4067/S0717-95022019000100358](https://doi.org/10.4067/S0717-95022019000100358)
11. Shiri E, Abolhassani F, Khosravizadeh Z, Najafi A, Khanezad M, Vazirian M, Fallahi P, Rezaeian Z, Hedayatpour A. Aqueous

- Origanum vulgare* extract improves the quality of cryopreserved human spermatozoa through its antioxidant effects. *Biopreservat Biobanking*. 2020;18(4):329-336. DOI: [10.1089/bio.2020.0008](https://doi.org/10.1089/bio.2020.0008)
12. Soliman MM, Mousa SMM, Bahakaim ASA. Effect of dietary oregano supplementation on reproductive performance and some physiological parameters of inshas chicken strain. *Egypt Poultry Sci*. 2016;36:67-83. DOI: [10.21608/epsj.2016.11375](https://doi.org/10.21608/epsj.2016.11375)
 13. Maty HN, Hassan AA. Effect of supplementation of encapsulated organic acid and essential oil Gallant+® on some physiological parameters of Japanese quails. *Iraqi J Vet Med*. 2020;34(1):181-188. DOI: [10.33899/ijvs.2019.125732.1142](https://doi.org/10.33899/ijvs.2019.125732.1142)
 14. Younis D TH. Effect of vitamin E and Selenium supplementation on productive and physiological performance of quail fed rations with high level of fat. *Iraqi J Vet Med*. 2019;33(1):1-7. DOI: [10.33899/ijvs.2019.125553.1072](https://doi.org/10.33899/ijvs.2019.125553.1072)
 15. Ax RL, Dally M, Didion BA, Lenz RW, Love CC, Varner DD, Hafez B, Bellin ME. *Reproduction in farm animals*. 7th Edition. New York: CRC press; 2000. 365-375 p. DOI: [10.1002/9781119265306](https://doi.org/10.1002/9781119265306)
 16. Fessehaye Y, Komen H, Rezk MA, Jo-han AM, Van Arendonk JAM, Bovenhuis H. Effects of inbreeding on survival body weight and fluctuating asymmetry (FA) in Nile tilapia *Oreochromis niloticus*. *J Aquac*. 2007;246:27-35. DOI: [10.1016/j.aquaculture.2006.12.038](https://doi.org/10.1016/j.aquaculture.2006.12.038)
 17. Orlu E, Egbunike GN. Breed and seasonal variations in the testicular morphometry, gonadal and extragonadal sperm reserves of the barredplymouth rock and Nigerian indigenous breeds of the domestic fowl. *Pak J Biol Sci*. 2010;13(3):120-5. DOI: [10.3923/pjbs.2010.120.125](https://doi.org/10.3923/pjbs.2010.120.125)
 18. Al-Bajari SHA, Al-Akash MA, Ismail HKH. Experimental detection of antioxidant and atherogenic effects of grapes seeds extracts in rabbits. *Iraqi J Vet Med*. 2019;33(2):243-249. DOI: [10.33899/ijvs.2019.162881](https://doi.org/10.33899/ijvs.2019.162881)
 19. Steel RGD, Torrie JH, Dickey DA. *Principles and procedures of statistics: A Biometrical Approach*. 3rd ed. New York: McGraw-Hill Book Co; 1997. 350-386 p. DOI: [10.4236/blr.2014.5424](https://doi.org/10.4236/blr.2014.5424)
 20. Akanbi IO, Adekunle IF, Oladele-Bukola MO, Makinde GEO, Fagbohun FA. Comparing the phytobiotic effects of feed-grade and liquid Oregostim® on Performance characteristics, Haematology and Serum biochemistry of Finisher broilers. *J Agric Vet Sci*. 2014;1(3):137-142. DOI: [10.36347/sjavs](https://doi.org/10.36347/sjavs)
 21. Waldenstedt L. Effect of Vaccination against Coccidiosis in Combination with an Antibacterial Oregano (*Origanum vulgare*) Compound in Organic Broiler Production. *Anim Sci*. 2003;53:2. DOI: [10.1080/09064700310007977](https://doi.org/10.1080/09064700310007977)
 22. Hafeez A, Manner K, Schieder C, Zentek J. Effect of supplementation of phytogetic feed additives (powdered vs. encapsulated) on performance and nutrient digestibility in broiler chickens. *Poult Sci*. 2015;95(3):1-6. DOI: [10.3382/ps/pev368](https://doi.org/10.3382/ps/pev368)
 23. Rabie MH, Hayam MA, Abo El-Maaty. Growth performance of Japanese quail as affected by dietary protein level and enzyme supplementation. *Asian J Anim Vet Advan*. 2015;10:74-85. DOI: [10.3923/ajava.2015.74.85](https://doi.org/10.3923/ajava.2015.74.85)
 24. Farhadi M, Jameie B, Honarkaran P, Mollajani R, Jameie M, Jameie M. The effect of carvacrol on the expression of P53 protein in testicular tissue and spermatogenesis of rats treated with methamphetamine. *Thrita*. 2018;7:2-6. DOI: [10.5812/thrita.88303](https://doi.org/10.5812/thrita.88303)
 25. Nixon B, Ewen KA, Krivanek KM, Clulow J, Kidd G, Ecroyd H, Jones RC. Post-testicular sperm maturation and identification of an epididymal protein in the Japanese quail (*Coturnix coturnix japonica*). *Reprod*. 2014;147:265-277. DOI: [10.1530/REP-13-0566](https://doi.org/10.1530/REP-13-0566)
 26. Jafari A, Karimipour M, Khaksar MR, Ghasemnejad-Berenji M. Protective effects of orally administered thymol against titanium dioxide nanoparticle-induced testicular damage. *Environ Sci Pollut Res Int*. 2019;27(2):2353-2360. DOI: [10.1007/s11356-019-06937-7](https://doi.org/10.1007/s11356-019-06937-7)
 27. Güvenç M, Cellat M, Gökçek I, Yavaş I, Özsoy SY. Effects of thymol and carvacrol on sperm quality and oxidant/antioxidant balance in rats. *Arch Physiol Biochem*. 2018;396:403. DOI: [10.1080/13813455.2018.1476979](https://doi.org/10.1080/13813455.2018.1476979)
 28. Surai PF, Kochish I, Fisinin VI. Antioxidant systems in poultry biology: Nutritional modulation of vitagenes. *Europ Poult Sci*. 2017;81. DOI: [10.1399/eps.2017](https://doi.org/10.1399/eps.2017)
 29. Hrabláková P, Voslářová E, I Bedáňová I, Pištěčková V, Chloupek J, Večerek V. Hematological and biochemical parameters during the laying period in common pheasant hens housed in enhanced cages. *Sci World J*. 2014;23(2):23-29. DOI: [10.1155/2014/364602](https://doi.org/10.1155/2014/364602)
 30. Silva-Vázquez R, Duran-Meléndez LA, Hernández-Martínez CA, Gutiérrez-Soto JG, Hume ME, Méndez-Zamora G. Effects of two sources of Mexican oregano oil on performance, blood profile, carcass variables, and meat of broilers. *R Bras Zootec*. 2018;47:1-9. DOI: [10.1590/rbz4720170198](https://doi.org/10.1590/rbz4720170198)
 31. Abd El-Hady AM, El Ashry GM, El-Ghalid OAH. Effect of natural phytogetic extract herbs on physiological status and carcass traits of broiler chickens. *J Anim Sci*. 2020;10:134-151. DOI: [10.4236/ojas.2020.101007](https://doi.org/10.4236/ojas.2020.101007)
 32. Savoini G, Bontempo V, Cheli F, Baldi A, Sala V, Mancin G, Agazzi A, Dell'Orto V. Alternative antimicrobials in the nutrition of postweaning piglets. *Vet Rec*. 2002;151(19):575-580. DOI: [10.1136/vr.151.19.577](https://doi.org/10.1136/vr.151.19.577)
 33. Ncube N, Afolayan SAJ, Okoh AI. Assessment techniques of antimicrobial properties of natural compounds of plant origin: current methods and future trends. *African J Biotechnol*. 2008;7(12):1797-1806. DOI: [10.5897/AJB07.613](https://doi.org/10.5897/AJB07.613)
 34. Méndez-Zamora G, Durán Meléndez LA, Hume ME, Silva Vázquez R. Performance, blood parameters, and carcass yield of broiler chickens supplemented with Mexican oregano oil. *Revista Brasileira de Zootecnia*. 2017;46:515-520. DOI: [10.1590/rbz4720170198](https://doi.org/10.1590/rbz4720170198)
 35. Erol H, Cantekin Z. Influence of intermittent lighting on broiler performance, incidence of tibial dyschondroplasia, tonic immobility, some blood parameters and antibody production. *Asian J Anim Sci*. 2007;20(4):550-555. DOI: [10.5713/ajas.2007.550](https://doi.org/10.5713/ajas.2007.550)
 36. Attiaa YA, Abd-Elhamid E, Abd-Elhamid B, Mustafa M, Al-Harthia MA, Muhammad M. Response of slow-growing chickens to feed restriction and effects on growth performance, blood constituents and immune markers. *Rev Mex Cienc Pecu*. 2017;8(2):175-184. DOI: [10.22319/rmcp.v8i2.4441](https://doi.org/10.22319/rmcp.v8i2.4441)
 37. Azis A. Performance and heterophil to lymphocyte (H/L) ratio profile of broiler chickens subjected to feeding time restriction. *Inter J Poult Sci*. 2012;11:153-157. DOI: [10.3923/ijps.2012.153.157](https://doi.org/10.3923/ijps.2012.153.157)
 38. Mert N, Yildirim BA. Biochemical parameters and histopathological findings in the forced molt laying hens. *Rev Bras Cienc Avic*. 2016;18. DOI: [10.1590/1806-9061-2015-0032](https://doi.org/10.1590/1806-9061-2015-0032)
 39. Zhu X, Lu W, Yuan S, Chen H. The effect of different dietary levels of thyme essential oil on serum biochemical indices in Mahua broiler chickens. *Ital J Anim Sci*. 2014;13(3):576-581. DOI: [10.4081/ijas.2014.3238](https://doi.org/10.4081/ijas.2014.3238)
 40. Bogusławska-Tryk M, Piotrowska A, Szymeczko R, Burlikowska K, Głowińska B. Lipid metabolism indices and fatty acids profile in the blood serum of broiler chickens fed a diet with lignocellulose. *Rev Bras Cienc Avic*. 2016;18:3. DOI: [10.1590/1806-9061-2015-0157](https://doi.org/10.1590/1806-9061-2015-0157)
 41. Totsuka M, Nakaji S, Suzuki K, Sugawara K, Sato K. Break point of serum creatinine kinase release after endurance exercise. *J Appl Physiol*. 2002;93(4):1280-1286. DOI: [10.1152/jappphysiol.01270.2001](https://doi.org/10.1152/jappphysiol.01270.2001)
 42. Mansoub NH, Myandoab MP. The effects of different levels of thyme on performance, carcass traits, blood parameters of broilers. *Ann Biol Res*. 2011;2(3):79-85. DOI: [10.3923/rjps.2011.18.21](https://doi.org/10.3923/rjps.2011.18.21)
 43. Hong JC, Steiner T, Aufy A, Lien TF. Effects of supplemental essential oil on growth performance, lipid metabolites and immunity, intestinal characteristics, microbiota and carcass traits in broilers. *Livestock Sci*. 2012;144:253-262. DOI: [10.1016/j.livsci.2011.12.008](https://doi.org/10.1016/j.livsci.2011.12.008)
 44. Demir E, Sarica S, Özcan MA, Suiçmez M. The use of natural feed additives as alternatives for an antibiotic growth promoter in broiler diets. *J Brit Poult Sci*. 2010;44-45. DOI: [10.1080/713655288](https://doi.org/10.1080/713655288)
 45. El-Sayed EM, Mansour AM, Abdul-Hameed MS. Thymol and carvacrol prevent doxorubicin-induced cardiotoxicity by abrogation of oxidative stress, inflammation, and apoptosis in rats. *J Biochem Mol Toxicol*. 2016;30(1):37-44. DOI: [10.1002/jbt.21740](https://doi.org/10.1002/jbt.21740)

اوريكوستيم عن طريق ماء الشرب. بينما تم تغذية المجموعة الثالثة على نظام غذائي غير متوازن (الذرة الصفراء المطحونة فقط) في حين أعطيت المجموعة الرابعة نظامًا غذائيًا غير متوازن (الذرة الصفراء المطحونة فقط) مع استخدام اوريكوستيم. تم قياس المعايير المتمثلة بأداء الجسم والتكاثر والصورة الدموية والكيموحياتية والصفة النسجية للخصى في الأسبوعين الرابع والثامن من بداية المعاملة. أظهرت النتائج أن إضافة اوريكوستيم تسببت في زيادة معنوية في وزن الجسم والخصية اليمنى، ومؤشر الغدد التناسلية، وأعداد الحيوانات المنوية وكذلك الحيوانات المنوية الحية في المجموعة الثانية مقارنة بالمجاميع الأخرى عند الأسبوع الرابع والثامن بعد المعاملة، وفي المجموعة الثالثة انخفضت أعداد كريات الدم البيض والخلايا اللمفاوية بشكل ملحوظ مع زيادة نسبة كريات الدم المتغيرة ومؤشر الإجهاد عند الأسبوع الرابع والثامن بعد المعاملة. كما كان هناك انخفاض معنوي للكوليسترول مع زيادة البروتين الكلي والكرياتين كابينيز في المجموعة الثالثة عند الأسبوع الثامن من المعاملة. بينما لم تختلف المجاميع التي عوملت باوريكوستيم عن مجموعة السيطرة. نستنتج من هذه الدراسة بأن اوريكوستيم السائل كان له تأثير إيجابي على وزن الجسم وعدد الحيوانات المنوية مع تحسين المعايير الدموية والكيميائية الحيوية في ذكور السمان.

تأثير Oregostem® والعليقة غير المتوازنة على أداء الجسم والكفاءة التناسلية في ذكور السمان

هيام نذير متي، محمود سالم المعاضيدي و سهي محمود احمد

فرع الفلسفة والكيمياء الحياتية والأدوية، كلية الطب البيطري، جامعة الموصل، الموصل، العراق

الخلاصة

هدفت هذه الدراسة إلى تحديد تأثير اوريكوستيم على أداء النمو وصفات الدم وتكوين الحيوانات المنوية في ذكور السمان. قسمت الطيور وعددها ١٦٠ طائرًا على أربع مجاميع (٤٠ طائر/ مجموعة) لكل منها مكررين ابتداءً من عمر ١٢ أسبوعًا، وشملت المعاملات الأربعة المجموعة الأولى تم تغذيتها على نظام غذائي متوازن فقط. المجموعة الثانية وحصلت هذه المجموعة على نظام غذائي متوازن مع