



Ameliorative role of Arabic gum against nephrotoxicity induced by ciprofloxacin in rats

A.D. Abdullah  and M.A. Ahmed 

Department of Biology, College of Education for Pure Science, Tikrit University, Tikrit, Iraq

Article information

Article history:

Received June 24, 2020
Accepted August 30, 2020
Available online October 1, 2021

Keywords:

Arabic gum
Ciprofloxacin
Nephrotoxicity
Antioxidants
MDA

Correspondence:

M.A. Ahmed
dr.measrahmed@tu.edu.iq

Abstract

Medicinal plants have gained wide popularity at present time due the side effects of chemical drugs on the body in general and on the kidneys in particular. This study aimed to explore the protective effect of Arabic gum (AG) against nephrotoxicity of ciprofloxacin. Twenty-four rats divided into four groups administrated for 14 days as following: control group administrated orally with distilled water 1 ml/kg, ciprofloxacin group 750 mg/kg, orally. Third group administrated with AG solution 15% and fourth group administrated with ciprofloxacin 750 mg/kg combined with AG 15% respectively. Results demonstrated the effect of Ciprofloxacin in significant increased levels of nephrotoxicity biomarkers such as blood urea nitrogen, creatinine, uric acid, MDA, and a significant decreased urine flow rate, creatinine clearance and degeneration in renal tissue via attenuate antioxidant system tissue. The combined administration of AG with Ciprofloxacin showed the ameliorative role of AG on nephrotoxicity biomarkers, nephron function, antioxidant availability and protected renal tissue from damage. We concluded that AG in concentration 15% has a protective role against renal toxicity exposed by ciprofloxacin in rats.

DOI: [10.33899/ijvs.2020.127441.1503](https://doi.org/10.33899/ijvs.2020.127441.1503), ©Authors, 2021, College of Veterinary Medicine, University of Mosul.
This is an open access article under the CC BY 4.0 license (<http://creativecommons.org/licenses/by/4.0/>).

Introduction

Nephrotoxicity is when renal nephron's ability to detoxification and excretion obstructed by toxicant (1). The kidney is the most important control system that maintains the body homeostasis and drains endogenous or exogenous toxicants (2).

Exposure to some chemical drugs often induced nephron's toxicity, and damage tissues. Around 20% of nephrotoxicity cases cause by drugs and the percentage raised approximately to 66 % in elderly who exposure to drugs (3).

The pathogenic effect of most chemical drugs lead to nephrotoxicity include tubular toxicity, crystals formation, inflammations, altered in glomerular hemodynamic (4).

Ciprofloxacin approved by Food and Drug agency FDA in 1987, it is the 2nd generation of fluoroquinolone family produces antibiotics against several bacterial infections via

inhibiting DNA gyrase and topoisomerase IV in bacteria preventing bacterial replication (5).

Arabic Gum (AG) defined by FAO and WHO as a dried exudation obtained from the stems of Acacia plant belongs to the Leguminosae family; Chemically Arabic Gum is a complex polysaccharide branched-chain, slightly acidic, mixed with calcium, potassium, and magnesium.

The backbone units contain β -D- galactopyranosyl units joined to side chains of β -L- rhamnopyranose, β D glucuronic acid, α L arabinofuranosyl, and β D galactopyroanose by 1,6- linkages (6). Arabic gum dissolves easily in water and gives color varies from pale yellow to orange - brown. Pharmacologically Arabic gum experimentally used as an antioxidant treatment against hepatic and renal toxicities (7).

The Study aimed to identify the protective and ameliorative role of Arabic gum solution against nephrotoxicity induced by oxidative damage.

Materials and methods

Collection and preparation of Arabic gum

The Arabic gum obtained from Sudan in August 2019 the gum was washed and dried at room temperature 25 ± 2 °C, then crushed and melt in water in concentration 15% according to active dose experiment (8).

Preparation of experimental subjects

Twenty-four healthy male rats weighed 190-220 g, and aged 6-7 weeks housed in an animal unit, College of Vet. Med. Medicine, University of Tikrit. Rats underwent to standard laboratory conditions (9), and free to access to food and water during the experimental period of 14 days. Rats distributed into four groups: Control group administrated with distilled water 1 ml/kg orally using tubular gavage, second group administrated with Ciprofloxacin 750 mg/kg orally, and third group administrated with a solution of Arabic gum solution 15% orally and fourth group administrated with both Ciprofloxacin 750 mg/kg and Arabic gum solution 15%. The administrated doses settled according to pretest to determine the active dose (8).

Urine sample collection

At the end of the experiment period rats caged individually in metabolic cages designed to collect and measure urine volume within 24 hours.

Blood sample preparation

Rats anesthetized by ether and blood was taken from jugular vein. blood centrifuged at 3000 rpm for 15 minutes to obtain the serum. Serum kept in a deep freeze -80°C until biochemical tests performed (9,10).

Kidney tissue homogenization

Kidney removed immediately, 1g of tissue weighted, harvested, and placed in 10 ml of cold homogenization medium at 4°C composed of 0.25 M sucrose, 20 mM Tris-HCl buffer pH 7.4 and 1 mM EDTA. The tissue homogenized by electrical homogenizer 16000 rpm for 30 seconds then centrifuged at 3000 rpm for 15 minutes. The supernatant used for biochemistry tests (11).

Histological study

Kidney tissue obtained immediately fixed in 10% formalin for 24 hours then washed by water then dehydrated using the series concentration of alcohol, samples cleared and infiltrated then embedded in paraffin, and sectioned to 5µm thickness by an electric rotary microtome. Sections stained by hematoxylin and eosin, and examined under a light of optical microscope (12).

Nephrotoxicity diagnosis

In this study, nephrotoxicity determined by measuring concentrations of creatinine, blood urea nitrogen (BUN), creatinine clearance, uric acid, Na/K in serum. Glutathione

(GSH), superoxide dismutase (SOD), and malondialdehyde (MDA) measured in serum and homogenized tissue (13).

Measurement of blood urea nitrogen

The concentration of blood urea nitrogen measured by a chemical method provide with an analyzing kit (Agappe, Switzerland). The basic principle is urea hydrolyzed by urease to give a complex of ammonia and carbon dioxide. The absorbance of the reaction measured spectrophotometry at wavelength 590 nm (13,14).

Measurement of creatinine

Creatinine measured spectrophotometry using an analyzing kit (Biomaghreb Company, Tunis). The basic principle depends on the interaction of creatinine present in the blood serum with alkaline picrate to produce a complex of creatinine picrate and has the highest absorbance at wavelength 490 nm (13,15)

Measurement of creatinine clearance

The method depends on the calculating equation $Cr.cl = \frac{\text{urine creatinine (mg/dl)} \times \text{urine flow (mL/min)}}{\text{Serum creatinine (mg/dl)}}$ (13).

Measurement of uric acid

The method applied according to the kit Procedure provided by (BIOLABO, France). The basic principle depends on uricase to act on uric acid to produce allantoin, carbon dioxide, and hydrogen peroxide, then reacts with a chromogen to form a complex gives a red color can be absorbed at 520 nm (13,15).

Measurements of oxidant - antioxidant

Lipid peroxidation determined via MDA which make a complex with Thiobarbituric acid (TBA) gives pink color can be absorbed spectrophotometry at 532 nm (16). Glutathione level proceed based on the Ellamn reagent method, the sulfhydryl group interact German reagent in an alkaline medium to form sulfured compound and TNB the complex gives a yellow color absorbed via spectrophotometer at 412 nm (17). The superoxide dismutase SOD activity evaluated based on the degradation of the nitro blue tetrazolium by the superoxide radical. Resulted color absorbed in spectrophotometer at 560 nm (17).

Statistical analysis

The experimental data analyzed via One Way ANOVA independent sample tests and the differences among groups achieved using Duncan multiple range test (18).

Results

Administration of Ciprofloxacin significantly increased levels of urea, creatinine, uric acid, Na⁺, and GSH, MDA and extracted tissue and a significantly decreased creatinine in

the urine, creatinine clearance, and GSH in serum in comparison to control group. Administration of AG significantly increased levels of creatinine clearance, K⁺, and MDA, but there was a significant decrease in the levels of uric acid, and urine creatinine, Na⁺, and GSH. While no significant differences appeared in the level of urea, creatinine, and GSH, SOD, and MDA compared to the

control group. The combined administration of ciprofloxacin and AG showed the ability of AG in decreasing levels of uric acid, urea, creatinine, creatinine clearance, Na⁺ and MDA in kidney tissue while there were elevating in levels of K⁺, GSH, in serum, SOD in homogenized tissue, and MDA in serum (Tables 1 and 2) (Figures 1-4).

Table 1: Effect of Ciprofloxacin and Arabic gum on nephrotoxicity indicators

	mean ± SE (n=6)			
	Control	Ciprofloxacin	Arabic Gum	Ciprofloxacin + Arabic Gum
Uric acid (mg/dl)	1.376±0.097	1.561±0.157*	1.026±0.051**	1.330±0.014*
Blood urea nitrogen (mg/dl)	25.846±3.27	40.697±3.395**	28.962±2.614 ^{N.S}	34.416±2.084*
Creatinine (mg/dl)	0.468±0.040	0.691±0.043*	0.547±0.006*	0.567±0.029*
Urine creatinine (mg/dl)	25.52±0.141	19.193±0.099**	23.892±0.115 ^{N.S}	14.353±0.141**

*= significant at P<0.05. **= significant at P<0.01.

Table 2: Effect of ciprofloxacin and Arabic gum on antioxidants concentration in serum and kidney homogenized tissue

	mean ± SE (n=6)			
	Control	Ciprofloxacin	Arabic Gum	Ciprofloxacin + Arabic Gum
GSH (µmol/l)	32.267±2.123	28.063±2.472*	33.463±4.367 ^{N.S}	32.842±1.704*
SOD (µmol/l)	13.071±0.229	13.359±0.076 ^{N.S}	12.259±0.720 ^{N.S}	13.018±0.072 ^{N.S}
MDA (µmol/l)	0.882±0.031	1.560±0.043*	4.337±0.047**	3.485±0.052*
GSH-k (µmol/g)	69.803±8.694	77.982±6.545*	55.799±0.591**	84.921±1.442**
SOD-k (µmol/g)	9.407±0.749	8.086±0.836*	10.059±0.462*	11.381±0.251**
MDA- k (µmol/g)	5.190±0.76	7.702±0.410**	5.223±0.216 ^{N.S}	4.322±0.328**

*= significant at P<0.05. **= significant at P<0.01.

Discussion

Ciprofloxacin nephrotoxicity is associated with renal damage. Ciprofloxacin caused atrophy in the glomerulus and renal cell toxicity leads to necrosis and degeneration in renal tubular cells. Which obstruct tubular function, activate inflammatory cascades, elevating lipid peroxidation and increase ROS influence body to use antioxidant systems such as GSH and SOD to avoid oxidative stress. ROS can activate TNF-α that stimulates apoptosis and necrosis in tubular cells due to inhibit Anti-apoptosis enzymes (19).

Tubular injury increases reabsorption of uric acid and raise its levels in serum. High uric acid combined with drugs is the most causes of nephropathy and induced acute kidney injury (20).

Fluoroquinolone has been involved in rhabdomyolysis and musculoskeletal complication due multifactorial activation of ROS, alteration in cell signaling, and the atom of fluorine cause myotoxicity, then increases concentration of creatinine. Also high levels of ROS inhibit insulin secretion influence the cell to utilize proteins and fats oxidation to provide energy, which increase urea and creatinine levels (21).

Quinolones appeared to increase the synthesis of the antidiuretic hormone ADH, so the urine flow rate and creatinine clearance decreased, the mechanism is not fully

understood, but it is proposed that quinolones can cross blood-brain barrier and stimulate synthesis and release of ADH (22). Also restricted sodium in serum increases reabsorption of water, urea, and decreases urine flow rate. Ciprofloxacin has low solubility in urine resulting in crystallization precipitate within distal tubules obstructing urine flow and increase inflammation (23). Arabic Gum has chemical compounds that have antioxidant properties such as phenols, flavonoids, amino acids and zinc (7). These antioxidant compounds ameliorated the antioxidant capacity in renal injured tissue and attenuated lipid peroxidation in subjects exposed to damages via Ciprofloxacin. AG rehabilitated glomerular shape, and has a protective function against nephrotoxicity observed through reduction of BUN, Creatinine, uric acid, and sodium levels and enhance urine flow rate, creatinine clearance, and potassium levels. The reduction in creatinine levels in serum refers to the protective role of AG against myotoxicity and enhance renal function. According to laboratory experiments AG administration elevating creatinine clearance, increases urinary flow rate, inhibit ADH and increases excretion of phosphate and Na⁺. Studies of showed that AG has antioxidant and anti-inflammatory properties preventing free radical's generation and inflammation associated with apoptosis and necrosis (24). AG contains zinc, which increases production of GSH, and SOD in tissue exposed to oxidative stress and decrease

levels of MDA, and keeps normality of tissue due zinc protein fingers role in DNA repairing and regulation of apoptosis (25) and that observed in this study. GSH and SOD were in a significant level in homogenized tissue more than serum, which refers to the earlier response to increase production of GSH, and SOD influenced by AG.

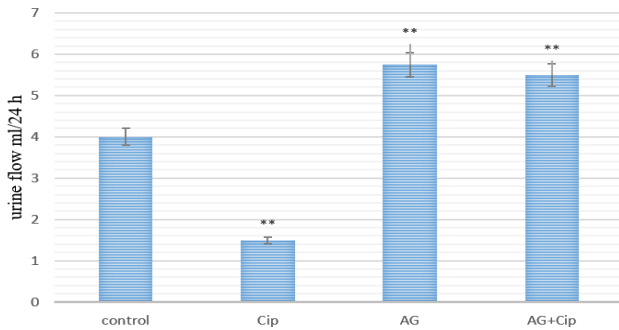


Figure 1: Effect of Ciprofloxacin and Arabic gum on level of urine flow rate. Cipro. = Ciprofloxacin 750 mg/kg. AG= Arabic Gum 15% of solution. *= significant at P<0.05. **= significant at P<0.01.

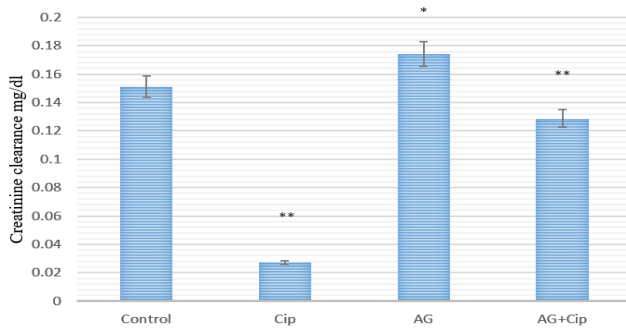


Figure 2: Effect of Ciprofloxacin and Arabic gum on level of creatinine clearance. Cipro. = Ciprofloxacin 750 mg/kg. AG= Arabic Gum 15% of solution. *= significant at P<0.05. **= significant at P<0.01.

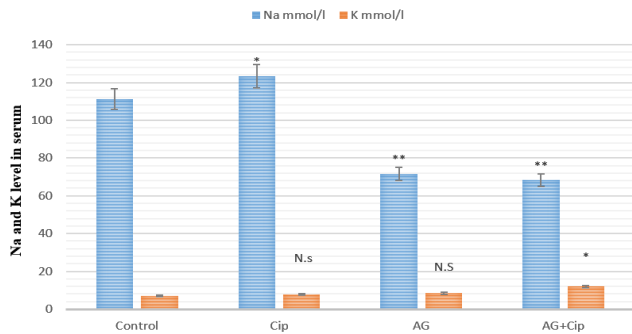


Figure 3: effect of Ciprofloxacin and Arabic gum on Na⁺ and K⁺ levels in serum. Cipro. = Ciprofloxacin 750 mg/kg. AG= Arabic Gum 15% of solution. *= significant at P<0.05. **= significant at P<0.01.

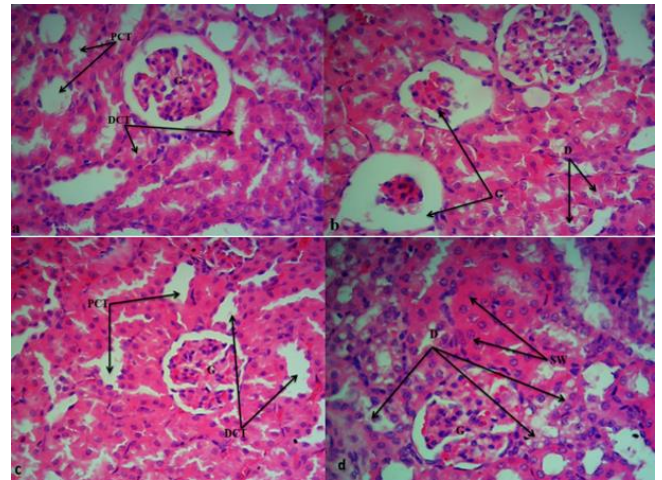


Figure 4: a: Control group showing normal kidney tissue glomeruli (G), proximal (PCT) and distal tubular (DCT). b: Damage in kidney tissue resulted via Ciprofloxacin, degeneration in renal tubular (D), glomerular atrophy (G). c: normal kidney tissue after Arabic gum administration. d: swelling (SW) and degeneration (D) in some tubular with normal glomerular (G) after administration with Arabic gum and Ciprofloxacin. (H&E, 40x).

Conclusion

We concluded that AG in concentration 15% has a protective role against renal toxicity exposed by ciprofloxacin in rats.

Acknowledgments.

The authors appreciate and thanks, the staff of animal facility unit in Veterinary Medicine College, university of Tikrit for their help in complete this scientific study.

Conflict of interest

No conflict.

References

- Ferguson MA, Vaidya VS, Bonventre JV. Biomarkers of nephrotoxic acute kidney injury. *Toxicol.* 2008;245:182-193 DOI: [10.1016/j.tox.2007.12.024](https://doi.org/10.1016/j.tox.2007.12.024)
- Kohli HS, Bhaskaran MC, Muthukumar T, Thennarasu K, Sud K, Jha V, Gupta KL, Sakhuja V. Treatment-related acute renal failure in the elderly: A hospital-based prospective study. *Nephrol Dial Transplant.* 2000;15:212-217. DOI: [10.1093/ndt/15.2.212](https://doi.org/10.1093/ndt/15.2.212)
- Nagai J, Takano M. Molecular-targeted approaches to reduce renal accumulation of nephrotoxic drugs. *Expert Opin Drug Metab Toxicol.* 2010;6:1125-1138. DOI: [10.1017/17425255.2010.497140](https://doi.org/10.1017/17425255.2010.497140)
- Kim S, Moon A. Drug induced nephrotoxicity and its biomarkers. *Biomol Ther.* 2012;20(3):268-272. DOI: [10.4062/molther.20.3.268](https://doi.org/10.4062/molther.20.3.268)
- Meyerhoff A, Albrecht R, Meyer J, Dionne P, Higgins K, Murphy D. US food and drug administration approval of ciprofloxacin hydrochloride for management of postexposure inhalational anthrax. *Clin Infectious Dis.* 2004;39(3):303-308. DOI: [10.1010.1086/421491](https://doi.org/10.1010.1086/421491)

6. Ali BH, Ziada A, Blunden G. Biological effects of gum arabic: A review of some recent research. *Food Chem Toxicol.* 2009;47(8):1-8. DOI: [10.1016/j.fct.2008.07.001](https://doi.org/10.1016/j.fct.2008.07.001)
7. Lopez TL, Nigen M, Williams P, Doco T, Sanchez C. *Acacia senegal* vs. *Acacia seyal* gums-part 1: Composition and structure of hyperbranched plant exudates. *Food Hydrocol.* 2015;51:41-53. DOI: [10.1016/j.foodhyd.2015.04.019](https://doi.org/10.1016/j.foodhyd.2015.04.019)
8. Al-Musawi HT, Al-Tai MI, Al-Musawi MT. The effect of the phenolic and other active compounds of the alcohol and acid extracts of cinnamon on some of the biochemical parameters of induced diabetes mellitus. *J Biotech Res Cent.* 2015;9(1):24-36. [\[available at\]](#)
9. Mustafa KA, Al-Baggou BK. Toxicological and neurobehavioral effects of chlorpyrifos and deltamethrin insecticides in mice. *Iraqi J Vet Sci.* 2020;34(1):189-196. DOI: [10.10.33899/ijvs.2019.125738.1144](https://doi.org/10.10.33899/ijvs.2019.125738.1144)
10. Ahmed MA. Protective effect of aqueous extract of *Alhagi maurorum* in spermatogenesis and antioxidant status of adult rats exposed to carbon tetrachloride. *Iraqi J Vet Sci.* 2019 ;33(1):1-7. DOI: [10.10.33899/ijvs.2019.125509.1031](https://doi.org/10.10.33899/ijvs.2019.125509.1031)
11. Graham JM. Homogenization of mammalian tissues. *Sci World J.* 2002;2:1626-1629. DOI: [10.1100/tsw.2002.849](https://doi.org/10.1100/tsw.2002.849)
12. Al-Haak AG. A gross anatomical and histological study of pancreas in adult Kestrel (*Falco tinnunculus*). *Iraqi J Vet Sci.* 2019;33(2):175-180. DOI: [10.10.33899/ijvs.2019.162960](https://doi.org/10.10.33899/ijvs.2019.162960)
13. Wu A, Tietz NW. *Clinical guide to laboratory test.* 4th ed. New York: CRP; 2006. 1096-1099 p.
14. Jasim RF, Allwsh TA. Effect of plasma isolated Orexin-A on the regulation of metabolites in male rats. *Iraqi J Vet Sci.* 2021;35(3):451-457. DOI: [10.10.33899/ijvs.2020.127001.1429](https://doi.org/10.10.33899/ijvs.2020.127001.1429)
15. Boumezrag A, Hemida H, Boumezrag FA, Smail F, Cisse S. Pathological and biological effects of treatments with lambdacyhalothrin in rabbits. *Iraqi J Vet Sci.* 2021;35(3):443-450. DOI: [10.10.33899/ijvs.2020.126977.1425](https://doi.org/10.10.33899/ijvs.2020.126977.1425)
16. Al-Abdaly YZ, Saeed MG, Al-Hashemi HM. Effect of methotrexate and aspirin interaction and its relationship to oxidative stress in rats. *Iraqi J Vet Sci.* 2021;35(1):151-156. DOI: [10.10.33899/ijvs.2020..1335](https://doi.org/10.10.33899/ijvs.2020..1335)
17. Ellman GL. Tissue sulfhydryl groups. *Arch Biochem Biophys.* 1959;82:70-77. DOI: [10.1016/0003-9861\(59\)90090-6](https://doi.org/10.1016/0003-9861(59)90090-6)
18. Gentle JE. Courses in statistical computing and computational statistics. *Am Statist.* 2000;58(1):2-5. DOI: [10.10.1198/0003130042908](https://doi.org/10.10.1198/0003130042908)
19. Abuelo JG. Normotensive ischemic acute renal failure. *N Engl J Med.* 2007;357(8):797-805. DOI: [10.10.1056/NEJMra064398](https://doi.org/10.10.1056/NEJMra064398)
20. Sedlacek M, Suriawinata AA, Schoolwerth A, Remillard BD. Ciprofloxacin crystal nephropathy: a 'new' cause of acute renal failure. *Nephrol Dial Transplant.* 2006;21(8):2339-2340. DOI: [10.10.1093/ndt/gfl160](https://doi.org/10.10.1093/ndt/gfl160)
21. Goli R, Mukku KK, Raju SB, Uppin MS. Acute Ciprofloxacin-induced crystal nephropathy with granulomatous interstitial nephritis. *Indian J Nephrol.* 2017;27(3):231-233. DOI: [10.10.4103/0971-4065.200522](https://doi.org/10.10.4103/0971-4065.200522)
22. Ahmed MA, Tayawi HM, Ibrahim MK. Protective effect of Silymarin against kidney injury induced by carbon tetrachloride in male rats. *Iraqi J Vet Sci.* 2019;33(1):127-130. DOI: [10.2019.125529.1051/ijvs.10.33899](https://doi.org/10.2019.125529.1051/ijvs.10.33899)
23. Schetz M, Dasta J, Goldstein S, Golper T. Drug-induced acute kidney injury. *Curr Opin Crit Care.* 2005;11(6):555-565. DOI: [10.10.1097/01.ccx.0000184300.68383.95](https://doi.org/10.10.1097/01.ccx.0000184300.68383.95)
24. Nasir O. Renal and extrarenal effects of gum arabic (*Acacia senegal*) what can be learned from animal experiments?. *Kidney Blood Press Res.* 2013;37(4-5):269-279. DOI: [10.10.1159/000350152](https://doi.org/10.10.1159/000350152)
25. Nasir O, Umbach AT, Rexhepaj R. Effects of gum arabic (*Acacia senegal*) on renal function in diabetic mice. *Kidney Blood Press Res.* 2012;35(5):365-372. DOI: [10.10.1159/000336359](https://doi.org/10.10.1159/000336359)

الدور الوقائي للصمغ العربي ضد السمية الكلوية المستحثة بواسطة السبروفلوكساسين في الجرذان

عبدالله ظاهر عبدالله و ميسر عبدالله احمد

قسم علوم الحياة، كلية التربية للعلوم الصرفة، جامعة تكريت، تكريت، العراق

الخلاصة

اكتسب الطب البديل إقبالا واسعا في الوقت الحاضر بسبب الآثار الجانبية التي تتركها العقاقير الكيميائية على الجسم بشكل عام والكلية بشكل خاص. هدفت الدراسة لاستكشاف الدور الوقائي للصمغ العربي ضد السمية الكلوية الناجمة عن عقار السبروفلوكساسين. أربع وعشرون جرذاً تم تقسيمهم إلى أربعة مجاميع تم معاملتها لمدة ١٤ يوماً وكالاتي: مجموعة السيطرة معاملة بالماء المقطر ١ مل/كغم فمويًا، مجموعة السبروفلوكساسين ٧٥٠ ملغم/كغم فمويًا، المجموعة الثالثة المعاملة بمحلول الصمغ العربي ١٥% والمجموعة الرابعة المعاملة بالسبروفلوكساسين ٧٥٠ ملغم/كغم بالتأزر مع الصمغ العربي ١٥% على التوالي. أظهرت النتائج تأثير السبروفلوكساسين في زيادة مستويات المؤشرات الحيوية للسمية الكلوية مثل نتروجين يوريا الدم، الكرياتينين، حامض البوليك، والمالوندايديهايد وانخفاض في معدل جريان البول، إزالة الكرياتينين وتحطم في نسيج الكلى بسبب ضعف مضادات الأكسدة في نسيج الكلى. إن المعاملة المشتركة بمحلول الصمغ العربي والسبروفلوكساسين أظهرت تحسناً في مؤشرات السمية الكلوية وعمل الكليون، وفعالية مضادات الأكسدة وحماية نسيج الكلى من الضرر. نستنتج من ذلك أن استخدام محلول الصمغ العربي بتركيز ١٥% له دور وقائي ضد السمية الكلوية المستحثة بواسطة السبروفلوكساسين في الجرذان.