



Effect of boron on some organs of pregnant BALB/c mice

B.A. Salah 

Department of Biology, College of Education for Pure Science, University of Mosul, Mosul, Iraq

Article information

Article history:

Received July 3, 2020
Accepted August 30, 2020
Available online October 1, 2021

Keywords:

Boric acid
Pregnancy
Embryo
Histopathology
Hematology

Correspondence:

B.A. Salah
baidaamohammed@uomosul.edu.iq

Abstract

Current research had been conducted to assess the impact of boric acid (boron) on the different tissues of the fetal and maternal bodies of pregnant mice *Mus musculus* and its influence on the maternal plasma biochemistry, hematology, in addition to the fetal and maternal bodies weight, moreover the weight of a certain motherly tissues included liver, kidney, lung, brain and spleen. The pregnant mice were administered orally with boric acid at the concentrations of 50 and 100 mg/kg during pregnancy. The observations at a concentration of 50 mg / kg demonstrated several histopathological patterns in different mothers and fetal body parts. The lesions were increased at the dose of 100 mg / kg. Moreover, boron caused weight decrease in the maternal body weight, fetuses, and liver, but it caused an increase in weight of the kidney at the concentration 100 mg/ kg. The biochemical assessment of the maternal serum showed a high rise in the level of liver enzymes, blood urea, creatinine, total protein, total bilirubin, glucose, cholesterol, triglycerides, HDL, and LDL at the concentration 100mg mg/kg. Furthermore, there was a meaningful change in the blood hematology at the concentration 100mg/kg. In conclusion, the exposure of pregnant mice to high concentrations of boric acid can alter the structure, the function of maternal and embryos organs by inducing oxidative stress, which in turn resulting in the accumulation of toxins in the blood that cause different effects during the exposure period.

DOI: [10.33899/ijvs.2020.127549.1509](https://doi.org/10.33899/ijvs.2020.127549.1509), ©Authors, 2021, College of Veterinary Medicine, University of Mosul.
This is an open access article under the CC BY 4.0 license (<http://creativecommons.org/licenses/by/4.0/>).

Introduction

Boric acid is an essential agent used in a variety of products such as; crystal, cleaning products, flame retardants, polymers that used to solidify plane fuselages, armed tackle, real hard substances, infant kindergartens, and sterilizers (1). Several medical articles had indicated the occurrence of borate poisoning as a result of domestic abuse and illegal application in the food industry (2). A few of the adverse effects of boric acid like induction of the programmed death in the HL60 cell line were accidentally noticed (3). At high concentrations, boric acid is a reproductive toxicant in mice, rats, and rabbits (4,5). DNA strand breakage induced by boric acid. Two factors determined the negative effect of boric acid on the DNA and which they are the dose and period of lime exposure (6). The usage of high doses of boric acid (500-3000 mg/kg) during

the first day of gestation has delayed mice's pregnancy due to the impairment of cell proliferation during development (7,8). Boric acid also can cause histone hyperacetylation in a specific tissue of mouse embryos and cause skeletal malformations (9). Boric acid had been expected to induce developmental problems in the derivatives of the brain's frontal lobe, particularly eye abnormalities such as small eyes in chicken embryos. (10,11). Boron impaired embryonic differentiation and cell proliferation when mouse embryos treated with 2000 micrograms (12). In male mice, high boric acid concentrations induced the occurrence of testis degeneration and an abnormal increase in the number of epithelial cells (13). Consumption of 700 mg/kg boric acid for two weeks led to breeding infertility in males of rats and reduced gestation in their females (14,15). Numerous experimental studies had been done on the embryotoxicity of boric acid in a laboratory animal, but the information was

scarce concerning the specific histological influence of boron on various organs of pregnant mice and their embryos.

Therefore, this research was carried out to detect the toxicological influence of specific concentrations of boric acid on inducing histopathological lesions in some organs of pregnant mice *Mus musculus* and their offspring. As well as its effect on some biochemical, and hematological variables, in addition to the weight changes of maternal body weight, fetuses, and several selected organs.

Materials and methods

Animals

In plastic cages with sawdust as bed-sheets, males and females of mice *Mus musculus* get used and preserved. They started eating ad libitum, and instant watering had been provided during all research periods. The animal room environment was kept at 23 - 25 C, and they exposed to a natural day/ night cycle. For mating, one adult male was placed in the cage with three adult females overnight. The next morning the occurrence of pregnancy was checked by the first gross appearance of the vaginal plug, and this considered as 0 days of pregnancy (16). The chemical used in the current study was Boron. It is mainly available in the form of boric acid (H₃BO₃). Boric acid is a salty white odorless powder (Sigma-10043) with a molecular mass of 61.84 g / mol, and a melting temperature of 171 ° C (17). Boric acid was obtained from the central store of the chemicals / College of Education for Pure Sciences, University of Mosul, Mosul, Iraq.

Experimental modelling

Fifty pregnant mice were chosen for experimentation. They were randomly categorized into three groups. Group 1 (ten mice) considered to be a control group and administered filtered water. Group 2 (20 mice) administered 50 mg/kg b.w. of boric acid orally. Group 3 (20 mice) administered 100 mg /kg b.w. of boric acid orally. The concentrations were prepared freshly during the experiment period by dissolving each concentration in 5ml of hot filtered water 70°C. The volume of the selected concentrations solution (50, 100 mg/kg b.w.) was 0.13-0.15 ml depending on the weight of pregnant mice. Dosing was done daily starting from the day 7th until the 17th day of pregnancy.

Blood assessment

Blood samples were collected from all groups 1, 2, and 3 via a retro-orbital method on the 17th day of gestation. The collected blood (2 ml) was divided into two parts. The first part was stored in small tubes without anticoagulants for hematological parameters assessment (which was done manually), those parameters were; the total count of white blood corpuscles (WBCs) was done with a standard counting chamber (hemocytometer slide), and according to the method mentioned in the (18).

Red blood corpuscles (RBCs) count was done according to the methods mentioned in (19). The numbers of platelets (PN) were counted according to the routine method mentioned in (20). Erythrocyte volume fraction (EVF) was estimated by the method mentioned in (21). Hemoglobin concentration (Hb) was estimated depending on the method mentioned in (22). The second part of the collected blood was kept in small tubes containing anticoagulant, those samples were centrifuged (3000 rpm) for 10 mins in order to get the serum for biochemical assessment. The serum was kept frozen at -20°C in the refrigerator until use.

Biochemical assessment

The evaluation of maternal kidney function was done by the estimation of both urea and creatinine levels using commercial kits of both Biomerieux- France, and Bio labo reagent kit, France, respectively. The activities of maternal liver enzymes (aspartate aminotransferase (AST), alkaline phosphatase (ALP), alanine transferase (ALT)) were evaluated using commercial kits manufactured by the company of Biomerieux-France. Furthermore, lipid profile, total protein, total bilirubin, and glucose concentrations in the serum were measured using standard commercial kits of Biolabo, France.

Necropsy

After blood collection was completed, all animal's groups 1, 2 and 3 were sacrificed and dissected, various maternal organs (liver, kidneys, spleen, lung, stomach, large intestine, ileum, and the skin), and embryos were isolated, washed with distilled water and fixed in formalin 10% (Sigma- E4019) for 48 hrs., respectively. For histopathological examination, the selected tissue specimens from both females and their embryos constituted the variables examined, as well as they were processed routinely, and stained with hematoxylin-eosin (Sigma-H3176) stain (23). Additionally, the bodyweight of all animal groups 1, 2 and 3 was measured in the days 7th and 17th of pregnancy. Selected maternal organs (liver, kidneys, spleen, and lung), and embryos were weighed directly after dissection. Furthermore, all previous weights were recorded.

Statistical profile

Recent data, which include weight changes for both mothers, fetuses, chosen organs, the activity of motherly liver and kidney biomarkers was described as an average \pm standard deviation (SD). One-way test (ANOVA) was being established. Dunnett's assessment had been used to signify the variations by matching medians of each test group 2, 3 with the median of the control group 1. Recent analytical data were investigated employing the Graph Pad Prism 5.0 (San Diego, USA) software. The P-value was estimated as; a significant (P<0.05), a very significant (P<0.01), and very strong significant (P<0.001), respectively.

Results

None of the mice of the various groups died during the whole experimental period. Mortality and clinical signs of toxicity in pregnant mice were observed at different times during the study period. Treated mice with selected concentrations of boric acid expressed a loss of appetite, tremors, excitation, and become isolated in one corner of the cage. The most common histopathological lesions were hyperplasia and keratinization in the lining epithelium of stomach wall, particularly those given the concentration of 100 mg/kg boric acid (Figure 1). Lymphoid hyperplasia of the lymph nodules of the ileum was also seen (Figure 2).

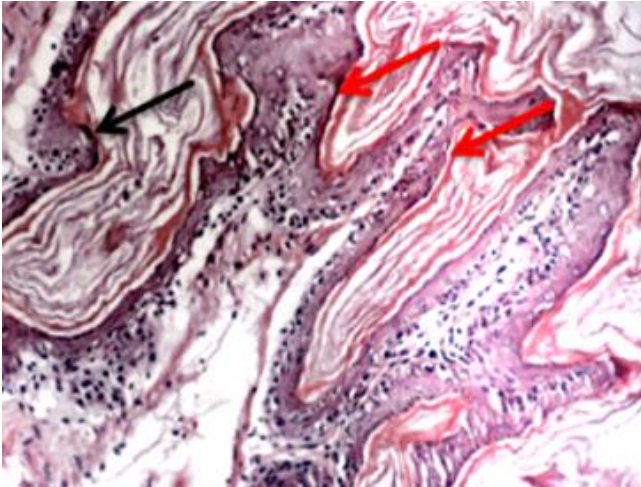


Figure 1. A cross- section of the stomach of a pregnant mouse given 100 mg/kg. b.w. boric acid orally. Hyperplasia (black arrow) and keratinization (red arrows) could be seen. H&E, 100x.

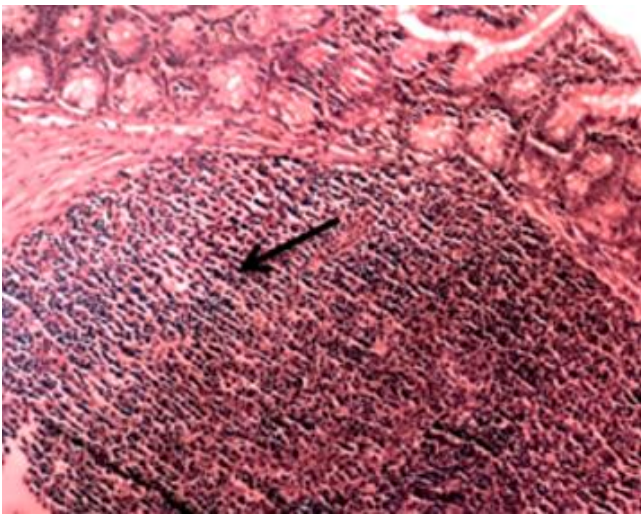


Figure 2: Section of ileum at 100 mg/kg.b.w. boric acid orally. hyperplasia of lymphoid nodule (arrow). H&E, 100x.

The liver exhibited vacuolar degenerative and coagulative necrotic changes with the appearance of binucleated hepatocytes (Figure 3).

Other lesions were mild glomerulonephritis, pulmonary congestion, and emphysema, and minimal to mild extramedullary hematopoiesis in the spleen at 100 mg/ kg. (Figures 4-6).

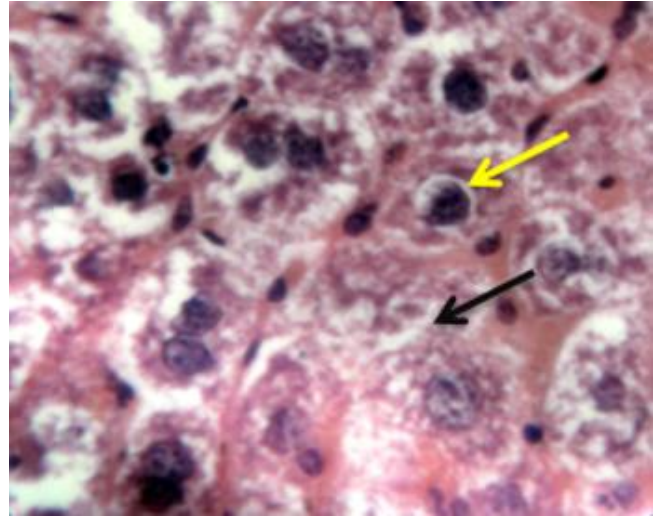


Figure 3. A cross-section showing; vacuolar degeneration (yellow arrow) and necrosis of hepatocytes (black arrow) in the liver of a pregnant mouse given 100mg/kg. b.w. boric acid orally H&E, 400x.

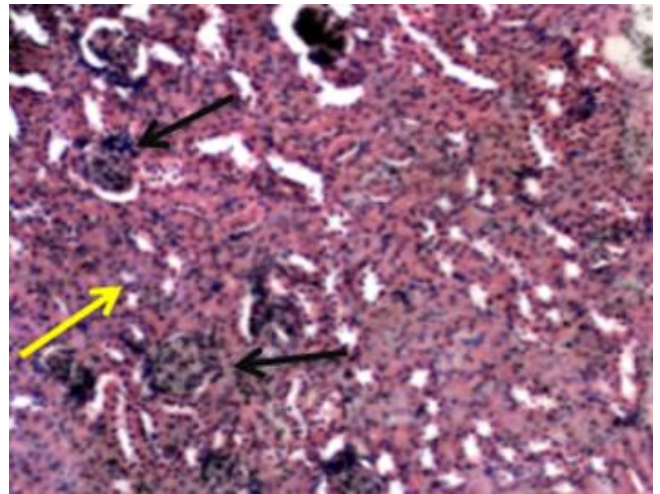


Figure 4. A cross-section showing; glomerulitis (black arrows), and the infiltration of inflammatory cells in the renal interstitium (yellow arrow) could be seen in the kidney of a pregnant mouse given 100mg/kg. b.w. boric acid orally. H&E, 100x.

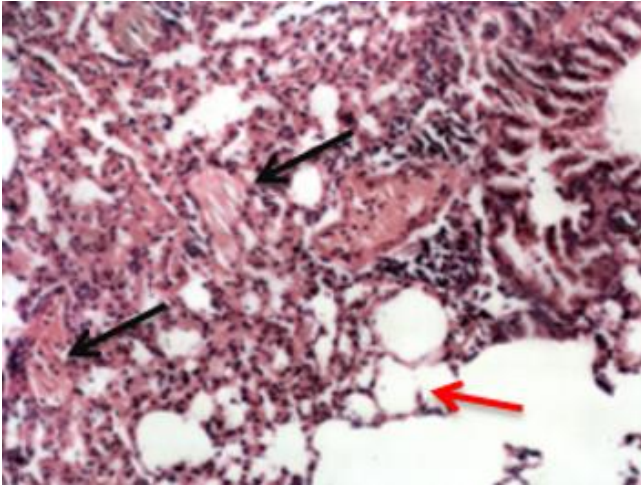


Figure 5. A cross-section showing emphysema (red arrow), and congestion (black arrows) in the lung of a pregnant mouse given 100 mg/kg. b.w. boric acid orally. H&E 100x.

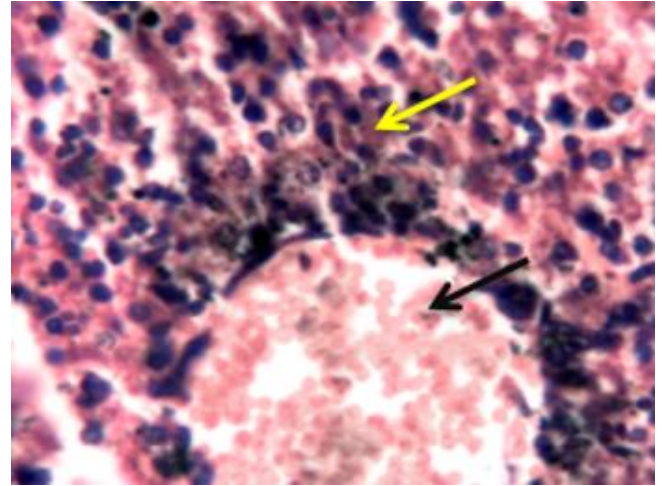


Figure 7. A cross-section of the liver of an embryo from a pregnant mouse given 100 mg/kg. b.w. boric acid orally. Congestion (black arrow) and the infiltration of mononuclear cells (yellow arrow) could be seen. H&E, 400x.

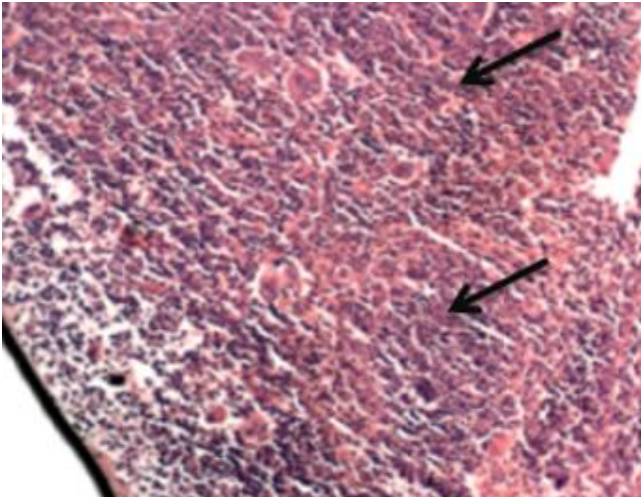


Figure 6. A cross-section showing mild extra-medullary hematopoiesis (arrows) in the spleen of a pregnant mouse given 100 mg/kg. b.w. boric acid orally. H&E. 100x.

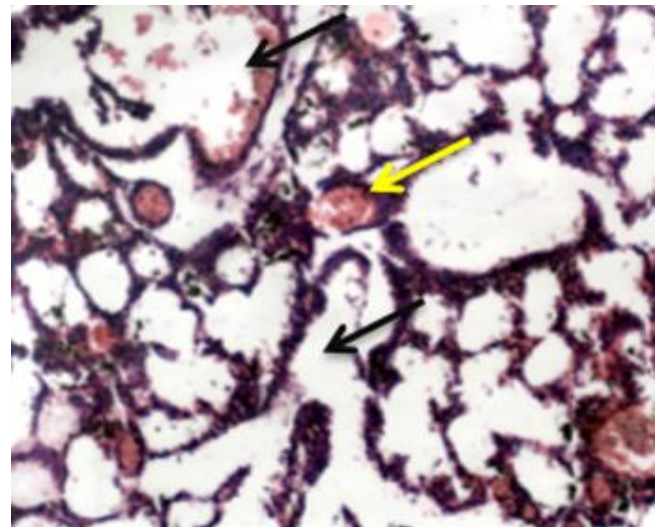


Figure 8. A cross-section showing congestion (yellow arrow) and pulmonary emphysema (black arrow) in the lung of an embryo from a pregnant mouse given 100mg/kg.bw. boric acid orally. H&E, 100x.

Sections prepared from the viscera of the embryo revealed hepatic congestion and abnormal arrangement of the hepatic cords (Figure 7), pulmonary congestion and emphysema (Figure 8), glomerulonephritis (Figure 9), enlargement of the lateral ventricle of the brain (Figure 10), and increased fibrous deposition in the dermis of the skin (Figure 11).

Effect of Boron on the weight of maternal bodies, maternal selected organs, and fetuses

Animals of all groups 1, 2 and 3 were weighted twice once in the beginning of the experiment and other the end of it. Selected maternal organs and fetuses were weighted after dissection immediately.

The results revealed a significant reduction in maternal body weight $P < 0.05$ of group 3. Group 2 showed a non-significant reduction in the weight of maternal liver, whereas group 3 revealed a significant reduction ($P < 0.05$) in its weight compared with the control. Group 2 revealed a significant reduction ($P < 0.05$) in maternal kidney weight. In contrast, group 3 showed a strong significant raise ($P < 0.01$) in the kidney weight compared with the control.

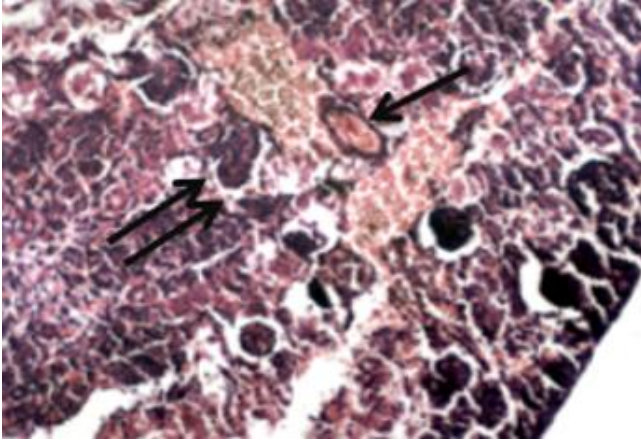


Figure 9. A cross-section of the kidney of an embryo from pregnant mouse given 100 mg/kg.b.w. boric acid orally. Note congestion (arrow) and glomerulonephritis (double arrows). H&E, 400x.

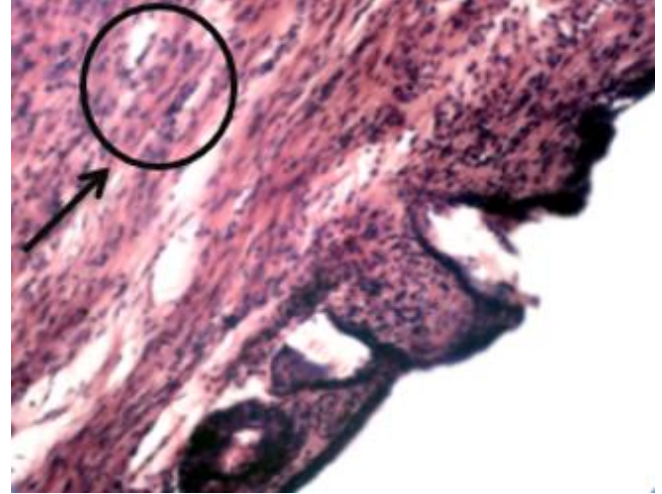


Figure 11. A cross-section of the skin of an embryo from a pregnant mouse given 100 mg/kg.b.w. boric acid orally. Massive fibrous tissue could be seen (arrow).H&E, 400X.

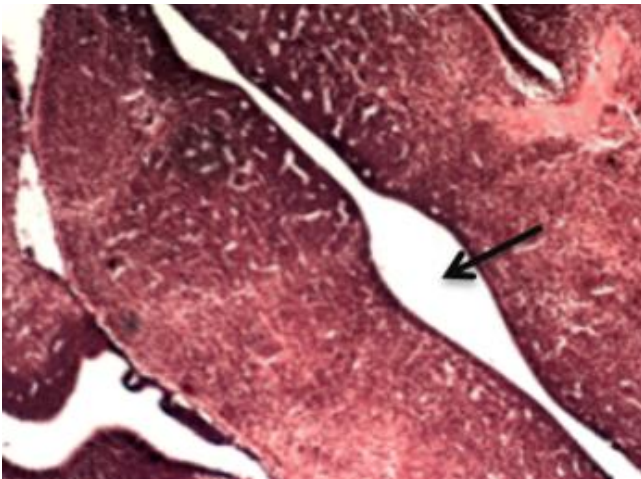


Figure 10. A cross-section of the brain of an embryo from a pregnant mouse given 100 mg/kg.b.w. boric acid orally. Enlargement of the brain ventricles (arrow) could be seen. H&E, 100x.

There was a non - significant reduction in the weight of the maternal brain, spleen, and lung of groups 2. but there was a significant reduction ($P < 0.05$) in the weight of the lung and spleen of group 3 compared with the control. Fetuses of both groups 2 and 3 showed a strong significant reduction ($P < 0.01$), and a very strong significant reduction ($P < 0.001$) in their weight compared with the control, respectively (Figure 12).

The findings confirmed that the selected concentrations impact the maternal blood elements concentrations as follows; both groups 2 and 3 showed a non- change, a significant and a highly significant reduction ($P < 0.01$) In the RBCs count compared to the control group, respectively (Figure 13).

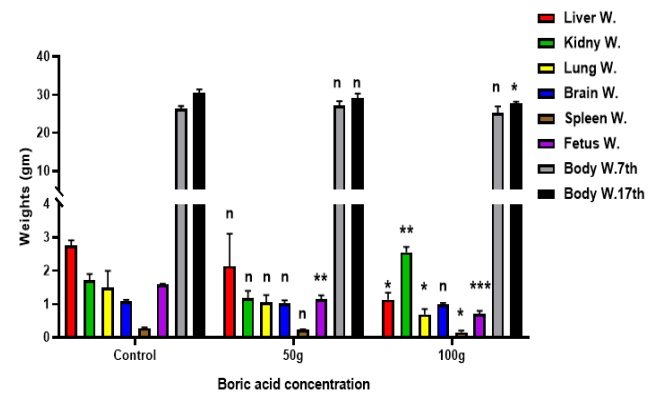


Figure 12: Display weight differences of the mother's body (average \pm SD), fetuses, and selected organs following the administration of two concentrations 50 and 100 mg /kg of Boron administered orally to the pregnant mice at the days 7th till 17th of gestation. * significant at $P < 0.05$, ** significant at $P < 0.01$, *** significant at $P < 0.001$, n = not significant in comparison to control.

Experimental groups showed a non- significant reduction in the WBCs count compared to the control. Besides, group 3 exhibited substantial ($P < 0.05$) improvement in the haemoglobin level, but the level was still in the normal range in group 2 compared to the control, respectively. Furthermore, groups 2 and 3 revealed a significant reduction ($P < 0.05$) and, a highly significant reduction ($P < 0.01$) in the EVF, respectively (Figure 13).

Group 3 confirmed a highly reduction (significant $P < 0.01$) in the count of PN, but there was a non- change in significant their count in group 2 compared to the control, respectively.

The biochemical assessment of the blood serum for liver enzymes revealed no statistically significant alteration in the AST and ALT levels in group 2, although there was a marked improvement ($P < 0.01$) in the ALP level compared with the control. Besides, Group 3 showed a very strong improvement ($P < 0.001$) in the concentrations of all previous enzymes compared with the control (Figure 14).

As well as, group 2 established a non- meaningful change in concentrations of both urea and creatinine, while a meaningful improvement ($P < 0.05$) in creatinine and, a strong significant improvement ($P < 0.01$) in the urea were observed in group 3 compared to the control.

Besides, group 2 showed a non- significant improvement in the total protein and the total bilirubin concentrations, but there concentrations showed strong significant improvement ($P < 0.01$) in group 3 compared to the control.

Furthermore, group 2 showed a non- significant reduction in the glucose concentration, while a strong reduction ($P < 0.01$) in glucose concentration was observed compared with the control (Figure 15).

The analysis of the lipid profile confirmed a remarkable significant improvement ($P < 0.01$), and a very strong significant improvement ($P < 0.001$) in the cholesterol amount of both groups 2, and 3 compared with the control, respectively.

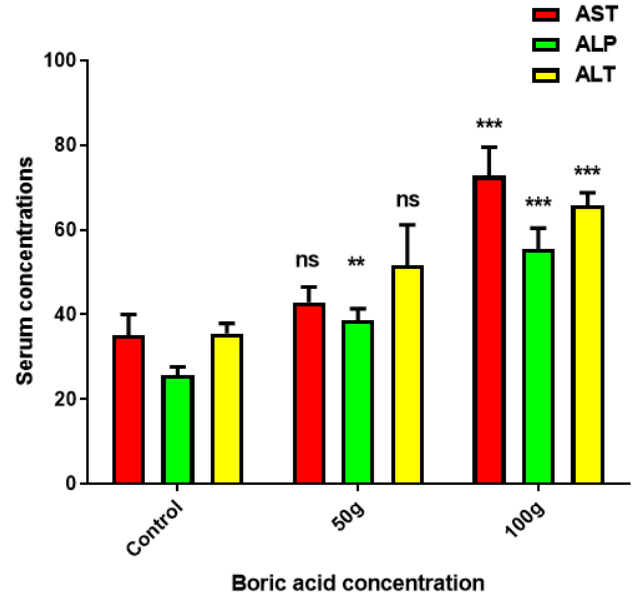


Figure 14: Display maternal blood serum levels of liver enzymes (average \pm SD) after the administration of two concentrations 50, and 100 mg /kg b.w of Boron administered orally to the pregnant mice at the days 7th till 17th of gestation. * significant at $P < 0.05$, ** significant at $P < 0.01$, *** significant at $P < 0.001$, n = not significant in comparison to control.

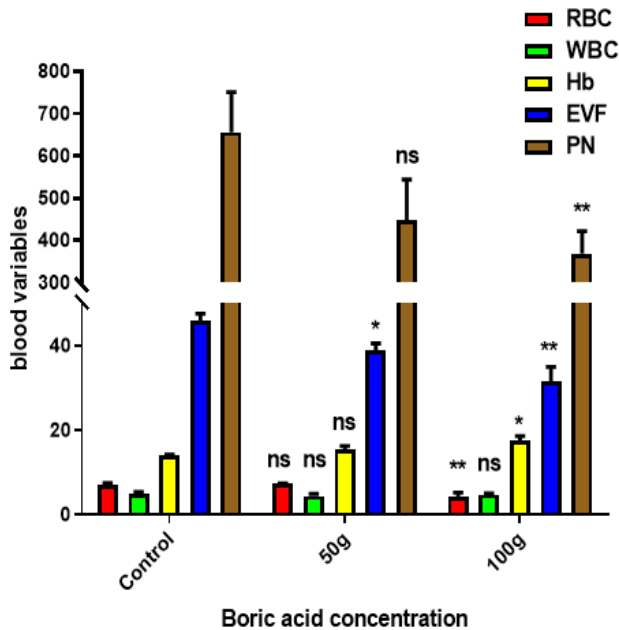


Figure 13: Display maternal blood hematological changes (average \pm SD) following the administration of two concentrations 50, and 100 mg /kg b.w of Boron administered orally to the pregnant mice from the day 7th till the 17th day of gestation. * significant at $P < 0.05$, ** significant at $P < 0.01$, *** significant at $P < 0.001$, n = not significant in comparison to control.

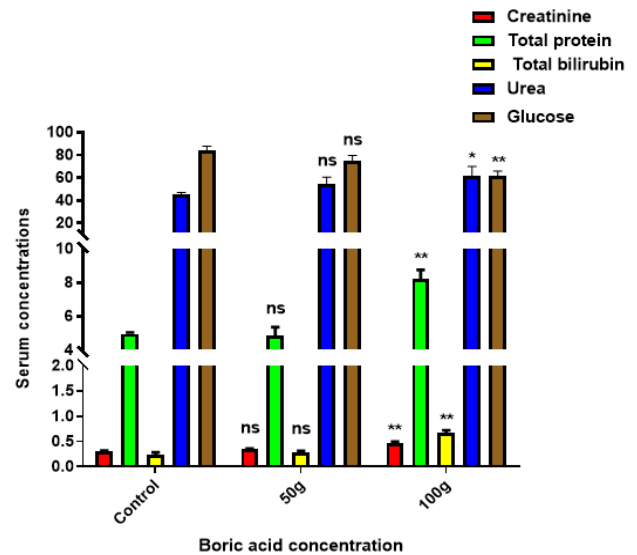


Figure 15: Show maternal blood serum levels of creatinine, blood urea, total protein, total bilirubin, and glucose (average \pm SD) following the administration of two concentrations 50, and 100 mg /kg b.w of Boron administered orally to the pregnant mice at the days 7th till 17th of gestation. * significant at $P < 0.05$, ** significant at $P < 0.01$, *** significant at $P < 0.001$, n = not significant in comparison to control.

Furthermore, group 2 revealed a non - significant changes in the triglyceride amount while, group 3 confirmed a strong significant improvement in its amount compared with the control. The results also showed a very strong significant improvement ($P < 0.001$) in the amount of both HDL and LDL of both groups 2, 3 compared with the control group, (Figure 16).

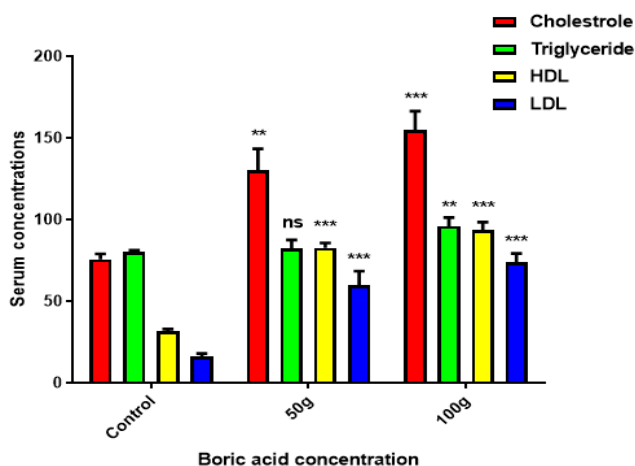


Figure 16: display maternal blood serum levels of the cholesterol, triglycerides, HDL, and LDL (average \pm SD) following the administration of two concentrations 50, and 100 mg/kg b.w of Boron administered orally to the pregnant mice at the days 7th till 17th of gestation. * significant at $P < 0.05$, ** significant at $P < 0.01$, *** significant at $P < 0.001$, n = not significant in comparison to control.

Discussion

In the current research, treating pregnant mice with the selected doses of boric acid caused a loss of appetite, tremors, excitation, and isolation of the mice in one corner of the cage. These signs are indicative of intoxication and they are similar to those reported by (24) after the administration of some analgesic and necrotic substances to pregnant mice.

Among lesions encountered in pregnant mice given, the 50 or 100 mg/kg of b.w. boric acid orally was hyperplasia and hyperkeratosis of the gastric mucosa, hyperplasia of lymphoid nodules in the wall of the ileum, vascular degeneration, necrosis of hepatocytes, glomerulonephritis, and hematopoiesis in mice by other workers (24-27).

Other lesions that occur in the present study may be due to that boron impaired protein synthesis by promoting phosphorylation of eLF2a in a gen kinase-dependent manner (28).

The harmful effect of boron can occur through inducing general amino acid control of protein production (29).

The occurrence of different lesions in different organs of pregnant mice in the current study may be due to that the boron alters the cell membrane functions, stability, and

composition that affect the response to hormone action and transmembrane movement of regulatory anions (30), or maybe because of the negative effect of boron that affects a number of some biological processes by inhibiting certain enzymes involved in these reactions (31).

Lesions in organs of embryos from mice were given 50 or 100 mg/kg b.w. included congestion of the central vein and mononuclear cell infiltration (hepatitis), pulmonary congestion and emphysema, glomerulonephritis, an increase in the size of the lateral ventricle of the head, and also similar to those of others (25-27).

The results of the current research may due to the dose of boron and the period of exposure. Or may due to that boric acid affect the integrity of major organs including the liver, kidneys, and lung and induces structural dysfunction (32).

The sequences revealed that there was a meaningful reduction in the pregnant mouse's body mass, motherly liver weight, and a strong a meaningful improvement in the weight of kidney of group 3. While, group 2 presented a non-meaningful changes in the weight of the liver, and kidney.

Furthermore, the weight of the brain revealed a non-meaningful change in both experimental groups. The current results confirmed a meaningful reduction in the weight of the spleen and lung of group 3, but group 2 presented a non-significant change in their weight.

The current findings were comparable to the outcomes of the authors (1,33), but they were in contrast with the outcomes of (34) who indicated that overconsumption of boron supplementation causes extra body weight in some animals.

The current results revealed a strong meaningful and a very strong meaningful ($P < 0.001$) reduction in the weight of fetuses of both experimental groups, respectively. The current findings were comparable to the results of (4), who cleared that the boron had an embryotoxic effect on the rodents' fetal weight, which was reduced by 33 % when treating them with a high dose of boron during pregnancy.

The current results were similar to the findings of (35), who indicated the toxic impact of boron on the testis and ovaries of both sexes of humans and animals.

The reduction in the body weight in the current study may due to that boron compound alters the hormonal and lipid metabolism of pregnant mice, which in turn raises the rate of fat burning in the animals, and thus causes weight loss.

As well as, boron is a complex trace mineral that can impact the absorption or use of a variety of substances implicated in biological functions, like calcium, copper, magnesium, nitrogen, sugar, triglycerides, free oxygen as well as contraceptives (36).

The increase in the weight of the liver and kidney in the current study may due to that the level of boron in blood and organs increases relative to the daily dosage, especially in pregnant animals. or may due to that the boron affects the homeostatic condition of renal cellular membranes, which in turn cause toxin accumulation in the selected organs (37).

The current findings showed a meaningful improvement in Hb concentration, a highly meaningful reduction in the count of PN, RBCs, and EVF respectively. WBCs count was almost in the normal range of group 3. While the previous blood components in group 2 were less affected by boron compared to group 3.

The current findings were somewhat similar to the findings of (38-41), whereas all previous authors recorded a significant reduction in the hematological parameters in mice, rats, and fish, respectively after boric acid administration. The current results were in contrast with the findings of (42).

The current findings may be due to that the high doses of boron inhibit the hemopoiesis and exhibit obvious toxicity activity in the blood or perhaps it is due to the red blood cell degradation and loss of its formation process which was approved by reducing MCHC measures (39).

Recent findings indicate that the liver enzymes in group 3 had already risen substantially, although the amount of those enzymes in group 2 had been lower. The findings of the current study were similar to the outcomes of the authors (1). While they were in contrast with the results of (43).

The rise in serum enzymes in the current study suggests a disruption in the function of the liver cells and their enzymes. This impaired liver function caused its enzymes to be released into the blood system (39).

The current findings revealed a meaningful improvement in the level of urea, and a strong meaningful improvement in the creatinine, total protein, total bilirubin amount in group 3 meaningful improvement in glucose amount. While there were non-significant changes in all previous variables of group 2. The previous findings were in contrast with the findings of (39).

The findings of the present study also demonstrated that there was indeed a substantial increase in noxious lipids in testing groups 2 and 3. As well as, group 3 was more affected compared to group 2. The current findings were in agreement with the outcomes of the authors (1,37,44).

Conclusions

The findings of the current study concluded that boric acid was at a concentration of 50 or 100 mg/kg b.w. orally given had a toxic effect on both pregnant mice and their embryos. As well as, High concentrations of boric acid could alter the antioxidant levels in the blood of pregnant mice in a way that causes severe damage to the organs of both mothers and their fetuses. Furthermore, mortality and clinical signs of toxicity in pregnant mice were observed at different times during the experiment period.

Acknowledgments

The researcher is quite thankful to the University of Mosul, the College of Education for Pure Science, Biology

Department for their contribution, whom greatly enhanced the quality of the study.

References

1. Aysan E, Sahin F, Teki D, Yalvac ME, Emre SH, Karaca C, Muslumanoglu M. Body weight reducing effect of oral boric acid intake. *Int J Med Sci.* 2011;8(8):653-658. DOI: [10.7150/ijms.8.653](https://doi.org/10.7150/ijms.8.653)
2. See AS, Abu BS, Fatimah AB, Nor AY, Ahmed SA, Lee YH. Risk and health effect of boric acid. *Am J Appl Sci.*2010;7(5):620-627. [\[available at\]](#)
3. Öguzkan SB, Turkey H, Karagul B, Cakir U, Ugras HI. In vitro cytogenetic and genotoxic effects of newly synthesized boron ionic liquids. *Bio & Biotech Equi.* 2019;33(1):253-257. DOI: [10.1080/13102818.2018.1552195](https://doi.org/10.1080/13102818.2018.1552195)
4. Heindel JJ, Price CJ, Schwetz, BA The developmental toxicity of boric acid in mice, rats, rabbits. *Environ Health Perspect.* 1994;102(7):107-112. DOI: [10.1289/ehp.94102s7107](https://doi.org/10.1289/ehp.94102s7107)
5. Duydu Y, Basaran N, Ustindundag A, Aydin S, Underger U, Ataman O Y, Aydos K, Duker Y, Ickstadt K, Waltrip BS, Golka K, Bolt HM. Is boric acid toxic to reproduction in humans? Assessment of the animal reproductive toxicity data and epidemiological study results. *Curr Drug Deliv.* 2016;13(3):324-329. DOI: [10.2174/15672666151029101514](https://doi.org/10.2174/15672666151029101514)
6. Gülsoy N, Yavas C, Mutlu O. Genotoxic effects of boric acid and borax in zebrafish, *Danio rerio* using alkaline comet assay. *Excli J.* 2015;14:890-899. DOI: [10.17179/excli2015-404](https://doi.org/10.17179/excli2015-404)
7. Beyer KH, Bergfield WF, Berndt WO, Boutwell R K, Carlton W W, Hoffman D K, Schroeter Al. Find a report on the safety assessment of sodium borate and boric acid. *J Am Coll Toxicol.* 1983;2:87-125. DOI: [10.3109/10915818309142004](https://doi.org/10.3109/10915818309142004)
8. Siegel E, Wason S. Boric acid toxicity. *Pediatr Clin North Am.* 1986;33(2):363-7. DOI: [10.1016/s0031-3955\(16\)35006-4](https://doi.org/10.1016/s0031-3955(16)35006-4)
9. Di Renzo F, Cappelletti G, Breccia ML, Giavini E, Menegola, E. Boric acid inhibits embryonic histone deacetylases: a suggested mechanism to explain boric acid-related teratogenicity. *Toxicol Appl Pharmacol.* 2007;220(2):178-185. DOI: [10.1016/j.taap.2007.01.001](https://doi.org/10.1016/j.taap.2007.01.001)
10. Showing J, Cuevas P. Teratogenic effects of boric acid upon the chick. macroscopic results. *Teratol.* 1975;12:334-338. DOI: <https://doi.org/10.2307/3431972>
11. Shapared TH. Catalog of teratogenic agents. 5th ed. Baltimore: Johns Hopkins University Press; 1986.
12. Lanoue L, Taubeneck MW, Muniz J, Hanna LA, Strong PL, Murray JF, Nielsen FH, Hunt CD, Keen CL. Assessing the effect of low boron diets on embryonic and fetal development in rodents using in vitro and in vivo model systems. *Biol Trace Element Res.* 1998;66(1-3):271-298. DOI: [10.1007/BF02783143](https://doi.org/10.1007/BF02783143)
13. Dieter MP. Toxicity and carcinogenicity studies of boric acid in male and female B6C3F1 mice. *Environ. Health Perspect.* 1994;102(7):93-7. DOI: [10.1289/ehp.94102s793](https://doi.org/10.1289/ehp.94102s793)
14. Weir RJ, Fisher RS. Toxicologic studies on borax and boric acid. *Toxicol Appl Pharmacol.*1972;23(3):351-364. DOI: [10.1016/0041-008x\(72\)90037-3](https://doi.org/10.1016/0041-008x(72)90037-3)
15. Fukuda R, Hirose M, Mori I, Chatani F, Morishima H, Miyahara H. Collaborative work to evaluate toxicity on male reproductive organs by repeated dose studies in rats 24). Testicular toxicity of boric acid after 2 and 4week administration periods. *J Toxicol Sci.*2000;25:233-239. DOI: [10.2131/jts.25.specialissue.195](https://doi.org/10.2131/jts.25.specialissue.195)
16. Salah BA, Histopathological effect of fluoxetine drug on the brain of pregnant mice and their embryos. *Iraqi J Vet Sci.* 2020;34(1):71-76. DOI: [10.33899/ijvs.2019.125467.1006](https://doi.org/10.33899/ijvs.2019.125467.1006)
17. Demirci UB, Miele P and Yot PG. Boron-Based (Nano-)Materials: Fundamentals and Applications. *Crystals.* 2016;6:118. DOI: [10.3390/cryst6090118](https://doi.org/10.3390/cryst6090118)
18. Santimone II, Di Castelnuovo A, De Curtis A, Spinelli M, Cugino D, Gianfagna F, Zito F, Donati MB, Cerletti C, de Gaetano G, Iacoviello L, MOLI-SANI Project Investigators. White blood cell count, sex and age are major determinants of heterogeneity of platelet indices in an adult general population: results from the MOLI-SANI project. *Haematol.* 2011;96(8):1180-8. DOI: [10.3324/haematol.2011.043042](https://doi.org/10.3324/haematol.2011.043042)

19. Poomcokark J, Neatpisarnvai, C. Red blood cells extraction, counting. 3rd ed. New York: International Press Engineering; 2008. 199-203 p.
20. Dacie JV, Lewis SM. Practical Haematology. 8th ed. Edinburgh: Churchill Livingstone; 1995.
21. Mirza RH, Sattar A. Hematological parameters in exotic cows during gestation and lactation under subtropical conditions. Pakistan Vet J. 2009;29(3):129-132. [[available at](#)]
22. Anukam C, Osazuwa OE, Osadolor, BH, Rew W, Bruce AW, Reid G. Yogurt containing probiotic *Lactobacillus rhamnosus* GR-1 and *L. reuteri* RC-14 helps resolve moderate diarrhea and increases CD4 count in HIV/AIDS patients. J Clin Gastroenterol. 2008;42(3):239-43. DOI: [10.1097/MCG.0b013e31802c7465](#)
23. Suvarna KS, Layton C, Bancroft JD. Bancroft's theory and practice of histological techniques. 7th ed. Oxford: Churchill Livingstone Elsevier; 2013. 654 p.
24. Al-Sultan RG. Pathologic and teratogenic changes resulting from experimental administration of some analgesic and narcotic substances in mice and their embryo [Ph.D. dissertation]. Mosul: College of Education for Pure Sciences, University of Mosul; 2017.
25. Bakirdere S, Orenay S and Korkmaz M. Effect of boron on human health. The Open Mineral Processing J. 2010;3:54-59. DOI: [10.2174/1874841401003010054](#)
26. Hu Q, Li S, Qiao E, Tang Z, Jin E, Jin G, Gu Y. Effects of boron on structure and antioxidative activities of spleen in rats. Biol Trace Element Res. 2014;158:73-80. DOI: [10.1007/s12011-014-9899-5](#)
27. Nielsen FH. Historical and recent aspects of boron in human and animal health. Boron. 2017;2(3):153-160. [[available at](#)]
28. Nishi H, Shaytan A, Panchenko AR. Physicochemical mechanisms of protein regulation by phosphorylation. Front Genet. 2014;5:270. DOI: [10.3389/fgene.2014.00270](#)
29. Tanaka Y, Yamaguchi A, Fujikawa T, Sakuma K, Morita I, Ishii K. Expression of mRNA for specific fibroblast growth factors associates with that of the myogenic markers MyoD and proliferating cell nuclear antigen in regenerating and overloaded rat plantaris muscle. Acta Physiol. 2008;194 (2):149-159. DOI: [10.1111/j.1748-1716.2008.01866.x](#)
30. Mohora M, Boghianu L, Muscurel C, Carmen D, Dumitrache C. Effect of boric acid on redox status in the rat liver. Rom J Biophys. 2020;12 (3-4):77-82. [[available at](#)]
31. Devirian TA, Stella LV. The physiological effect of dietary boron. Crit Rev Food Sci Nutr. 2003;43 (2):219-231. DOI: [10.1080/10408690390826491](#)
32. Basoglu A, Baspinar N, Ozturk SA, Akalin PP. Effects of boron administration on hepatic steatosis, hematological and biochemical profiles in obese rabbits. Trace Elements Electrolytes. 2010;27(4):23-30. DOI: [10.5414/TEP27225](#)
33. Hunt CD, Nielsen FH. Interaction between boron and cholecalciferol in the chick. Aust Acad Sci. 1981. DOI: [10.1007/978-3-642-68269-8_152](#)
34. Bai Y, Hunt CD. Absorption and distribution of boron in rats following a single oral administration of boron. Proc North Dakota Acad Sci. 1996;50:53. [[available at](#)]
35. Bolt H, Basarn N, Duydu Y. Effect of boron compounds on human reproduction. Arch Toxicol. 2020;94:717-724.
36. Nilsen FH *et al.* Effect of dietary boron on mineral, oestrogen, testosterone metabolism in postmenopausal women. FASEB J. 1987;1:394-397. DOI: [10.1007/s00204-020-02700-x](#)
37. Bustos OE, Olivares C. Boron as testicular toxicant in mice (*Mus domesticus*). Inter J Morphol. 2012;30(3):1106-1114. DOI: [10.4067/S0717-95022012000300057](#)
38. Feng B, Li X, Li S, Wang J. Effect of drinking boron on blood composition in rats. J Hyg Res. 2009;38(4):485-8. [[available at](#)]
39. Nair P, Vora N, Purandhar K, Kamle V and Seshadri S. Hydroalcoholic extracts of *Ecliptalpa* as a reversal agent in boric acid induced male reproductive toxicity. Zool Poloniae. 2012;57(1-4):21-46. DOI: [10.2478/v10049-012-0002-5](#)
40. Pataik L, Patra AK. Haematopoietic alterations induced by carbaryl in *Clarias batrachus*. J Appl Sci Environ Management. 2006;10(3):5-7. DOI: [10.4314/jasem.v10i3.17305](#)
41. Keklik E, Keklik M, Bakkaloglu U, Yuruk M, Coksevirm B. The effect of borax on hematological parameters and immunoglobulin values in rats. West Indian Med J. 2016;12(1):1-10. DOI: [10.7727/wimj.2016.359](#)
42. Cengiz M. Hematoprotective effect of boron on cyclophosphamide toxicity in rats. Cell Mol Biol. 2018;64(5):62. DOI: [10.14715/cmb/2018.64.5.10](#)
43. Kurtoglu V, Kurtoglu F, Akalin PP. The effects of various levels of boron supplementation on live weight, plasma lipid peroxidation, several biochemical and tissue antioxidant parameters of male mice: Effects of boron on performance, antioxidant and some m, Yetabolits of mice. J Trace Elem Med Biol. 2018;49:146-150. DOI: [10.1016/j.jtemb](#)
44. Ali S, Diwakar G, Pawa S, Siddiqui MR, Jain SK, Abdulla M. Attenuation by boron supplementation of the biochemical changes associated with thioacetamide-induced hepatic lesions. J Trace Elem Exper Med. 2002;15(1):47-55. DOI: [10.1016/S0925-4439\(01\)00030-8](#)

تأثير البورون على بعض أعضاء الفئران BALB/c الحوامل

بيداء عبد العزيز صالح

قسم علوم الحياة، كلية التربية للعلوم الصرفة، جامعة الموصل، الموصل، العراق

الخلاصة

أجري البحث الحالي للتعرف على تأثير حمض البوريك على النسج المختلفة للأجنة والأمهات الحامل من الفئران البيض وتأثيره على الكيمياء الحيوية لبلازما الأم، مكونات الدم ووزن جسم الأم والجنين، فضلا عن وزن بعض أعضاء الأم المختارة مثل الكبد، الكلى، الرئة، المخ والطحال. جرعت الفئران الحوامل فمويا بحمض البوريك بتركيز 50، 100 ملغم/غم من وزن الجسم خلال فترة الحمل. أظهرت الفحوص الكيموحيوية لمصل الأم ارتفاعا كبيرا في مستوى إنزيمات الكبد، اليوريا، الكرياتينين، البروتين الكلي، البيليروبين الكلي، الكلوكونز، الكوليسترول، الدهون الثلاثية، الدهون البروتينية واطنة الكثافة، الدهون البروتينية مرتفعة الكثافة عند التركيز 100 ملغم / كغم. فضلا عن انه كان هناك تغيير كبير في نسب مكونات الدم عند التركيز 100 ملغم / كغم. لوحظ عند التركيز 50 ملغم/كغم العديد من التغيرات النسيجية المرضية في الأعضاء المختارة من جسم الأمهات الحامل وأجزاء من جسم الجنين وكذلك لوحظ زيادة الأفات النسيجية عند الجرعة 100 ملغم / كغم وعلاوة على ذلك، تسبب البورون في انخفاض الوزن في جسم الأم، والأجنة، والكبد، ولكنه تسبب في زيادة وزن الكلى عند التركيز 100 ملغم/كغم. نستنتج من ذلك أن تعرض الفئران الحامل لتراكيز عالية من حمض البوريك يغير في بنية ووظيفة أعضاء الأم والأجنة عن طريق إحداث الإجهاد التأكسدي، مسببا تأثيرات مرضية خلال الحمل.