



## Comparative study on the effect of cadmium and hydrocortisone treatment on the brain of rats experimentally infected with *Toxoplasma gondii*

K.H. Al-Mallah<sup>1</sup> , S.S. Aghwan<sup>2</sup>  and Q.T. Al-Obaidi<sup>3</sup> 

<sup>1</sup>Department of Pathology and Poultry Diseases, <sup>2</sup>Department of Microbiology, <sup>3</sup>Department of Preventive Medicine, College of Veterinary Medicine, University of Mosul, Mosul, Iraq

### Article information

#### Article history:

Received September 22, 2020  
Accepted January 23, 2021  
Available online October 1, 2021

#### Keywords:

*Toxoplasma gondii*  
Cadmium chloride  
Hydrocortisone  
Rats

#### Correspondence:

K.H. Al-Mallah  
[karamyahya74@uomosul.edu.iq](mailto:karamyahya74@uomosul.edu.iq)

### Abstract

This study was dedicated to detecting the effects of cadmium chloride and of cortisone on experimental infection with *Toxoplasma gondii* in rats through studying brain tissue. Twenty-four adult albino male rats were used, divided into four groups, comprising: untreated control as group 1, group 2: infected with intraperitoneal injection of *Toxoplasma gondii* 80 tissue cysts per animal, group 3: infected with *Toxoplasma gondii* and treated with intraperitoneal injection of cadmium chloride 1.5 mg/kg once a week, group 4: infected with *Toxoplasma gondii* and treated with intramuscular injection of hydrocortisone in a dose 0.5 mg/kg once a week. After 30 days of treatment for all groups, the animals were sacrificed, and the gross and histopathological examinations were performed on the brains of the rats. The results revealed the presence of changes in the infected groups including appearance of toxoplasma tissue cysts in the grey matter, with mild to moderate perineuronal and periaxonal edema. There were further changes observed in infected groups which treated with cadmium chloride including perineuronal satellitosis, perineuronal edema and demyelination in neuronal axons, otherwise the infected groups treated with cortisone did not show any noticeable difference from the group of infection only. It is concluded that cadmium increase the intensity of occurrence of lesions induced by *Toxoplasma gondii* in the brain tissue of the rats, considering that all noticeable lesions ranged from mild to moderate in severity, and the differences between groups may be related to the nature of the pathogen used.

DOI: [10.33899/ijvs.2021.128436.1575](https://doi.org/10.33899/ijvs.2021.128436.1575), ©Authors, 2021, College of Veterinary Medicine, University of Mosul.  
This is an open access article under the CC BY 4.0 license (<http://creativecommons.org/licenses/by/4.0/>).

### Introduction

Toxoplasmosis is zoonotic parasitic disease (1,2) can be considered as one of the most universally distributed infectious diseases (3). The infection is caused by *Toxoplasma gondii*, which is a protozoal parasite from the order: Sporozoa, family: Sarcocystidae, genus: *Toxoplasma* (4). This parasite can invade several mammalian tissues (5,6), as well as avian tissues like in local poultry industry (7) *Toxoplasma* tissue cysts can develop in lungs, liver and kidneys but is most commonly noticed in nervous and muscular tissues, including brain, eyes, skeletal

muscles, and heart (8,9). The lesions induced by *Toxoplasma* infection are typically accompanied by inflammatory response, especially the necrosis in the infected tissues generating clinical signs such as anemia, headache, fever, and muscle pain as well as long-term complications resulting from specific cells destruction in brain, eyes, lungs and heart (10). The cadmium is one of the heavy metals of industrial importance, but it is also a dangerous pollutant in environment which the exposure to it leading to certain toxic effects to many tissues, especially the brain (11,12). The serious toxic effect of cadmium on plants and animals is caused by its ability to inactivate the intramembranous ionic

exchange, thus affecting their permeability (13), and as a result cadmium has a direct harmful effect on the liver and kidneys and may result in acute renal failure (14). It is also reported that cadmium chloride consumption affects the endocrine functions with adverse impact on the histological view of each thyroid and adrenal glands of rats (15). The cortisone drugs are glucocorticoids, which are steroidal compounds with a hormonal effect used clinically to suppress inflammations and exaggerated immune responses by stopping the release of inflammatory mediators (16). The goal of the study is to compare the pattern of *Toxoplasma* infection in the brain of rats, alone, and in combination with cadmium chloride exposure and under effect of cortisone drug to monitor the effects through histopathological point of view.

## Materials and methods

### Animals and housing

Twenty-four adult albino male rats aged from 2.5 to 3 months and weighing between 200 - 250 gm, were used in this experiment. They were obtained from the animal house of the college of Veterinary Medicine after receiving the approval of the Ethical Committee for the experiment. The animals were kept in standard plastic cages of 12\*25\*10 cm, with steel buckle cover, and were freely supplied with food and water and housed within 22±25°C and 12-12 light-dark cycle. Those animals were randomly distributed between four groups with six animals for each group.

### The isolation of *Toxoplasma gondii*

*Toxoplasma gondii* was diagnosed by examining the impression smears made from placentas of the aborted ewes (17). The positive samples for toxoplasmosis were digested by pepsin as described by (18).

The fluid extracted from infected placenta was inoculated in albino mice intraperitoneally, typical tissue cysts were found in the brain of the inoculated mice who sacrificed and the suspension was made from infected brains by homogenisation and washing with phosphate buffered saline three times, this suspension containing the brain tissue cysts was inoculated in the peritoneal cavity of the rats of experiment.

### The experiment and manipulation

The first group was the control group, which was not subjected to any treatment for 30 days; the second group was infected with 80 *Toxoplasma gondii* tissue cyst for animal as an infective dose by intraperitoneal injection once, on day one of the experiment.

The third group was infected and treated with cadmium chloride 1.5 mg/kg by intraperitoneal injection once a week. The fourth group was also infected and treated with hydrocortisone 0.5 mg/kg once a week for the period of the experiment.

## Gross and histopathological examination

The animals were sacrificed, dissected and the gross pathological changes were recorded; then samples were taken from the brain and directly preserved in 10% neutral buffered formalin. Trimming was performed followed by dehydration using gradual concentrations of ethyl alcohol, cleared with xylol, embedded with paraffin wax at 57°C, set in paraffin blocks and sectioned to 4-6 micrometer sections and stained with hematoxylin and eosin (19-21), and examined under light microscope Kruss, Germany and photographed using digital camera, Sony, Japan.

## Results

Histopathological examination revealed the existence of pathological changes in brain tissue at the three treated groups compared with control group. The toxoplasma infected group showed toxoplasma tissue cyst in brain tissue, mostly in the cerebral medulla surrounded by mild microgliosis, perineuronal and periaxonal edema (Figure 1). In the infected and cadmium chloride-treated group, the same lesions mentioned above were observed with perineuronal satellitosis, Hyperaemic arterioles and capillaries, perineuronal edema and mild microglial cells proliferation with increase of degenerative and necrotic neurons surrounded by microglial cells (Figure 2). The infected group with cortisone treatment showed the same lesions as the infected group with noticeable toxoplasma tissue cyst and cerebral cortex and medulla with microgliosis, perineuronal and periaxonal edema (Figure 3).

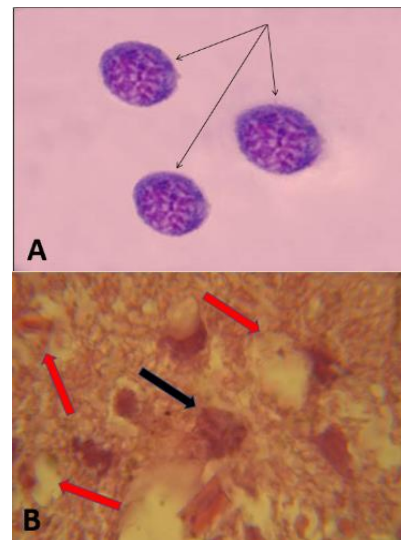


Figure 1: A: Microscopic image of tissue cysts in impression smears of the brain of rat (Black arrows). Giemsa stain, magnification 1000 X. B: Section of the brain medulla of the rat from the group infected with *Toxoplasma gondii* showing *Toxoplasma* tissue cyst (Black arrow) with mild periaxonal edema (Red arrows). H&E stain. Magnification 780 X.

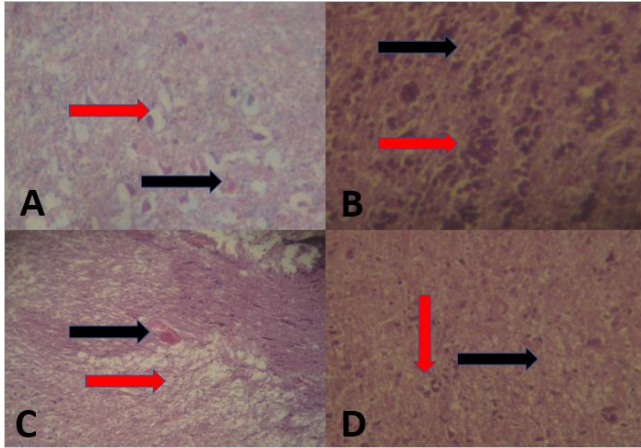


Figure 2: A: Section of brain cortex of rat infected with *Toxoplasma gondii* and treated with cadmium chloride showing congestion of capillaries (Black arrow) with mild peri axonal edema (Red arrow) Magnification 780 X. B: Section of brain Medulla of rat infected with *Toxoplasma gondii* and treated with cadmium showing neuronal demyelination (Black arrow) Perineuronal microgliosis (Red arrow). 730 X. C: Section of brain medulla of rat infected with *Toxoplasma gondii* and treated with cadmium showing capillary congestion (Black arrow), Perineuronal edema (Red arrow). Magnification 115X. D: Section of brain medulla of rat infected with *Toxoplasma gondii* and treated with cadmium showing demyelination and vacuolation in myelin sheaths (Black arrow), microgliosis (Red arrow). Magnification 145 X. Staining H&E for all images.

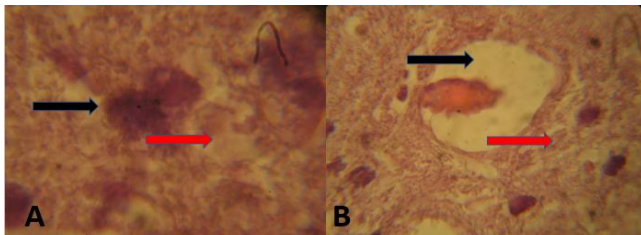


Figure 3: A: Section in brain cortex section of rat infected with *Toxoplasma gondii* and treated with cortisone showing toxoplasma tissue cyst (Black arrow) with mild peri axonal edema (Red arrow). Magnification 780 X. B: Section of brain medulla of rat infected with *Toxoplasma gondii* and treated with cortisone showing vasogenic edema (Black arrow) with mild demyelination in myelin sheaths (Red arrow). 730 X. Staining H&E for all images.

## Discussion

The *Toxoplasma gondii* infected group revealed histopathological changes in brain tissue represented by the presence of tissue cyst at cortex and medulla of cerebrum and medulla oblongata. Similar results were obtained by Al-Khalidy *et al.* (22) in Al-Diwaniyah province/ Iraq, who

noticed the calcified *Toxoplasma* tissue cysts in brain of affected cats. This study also demonstrated pathological changes as mild focal microgliosis, perineuronal and periaxonal edema, agreeing with Al-Saidya and Al-Kennany (23), who recorded these lesions after experimental infection with local isolates of *Toxoplasma gondii* in local cats and they also reported encephalitis in more advanced stages.

Our results also were supported by the findings of Al-Khanaq and Jasim (24), who stated that intraperitoneal inoculation of *Toxoplasma gondii* in albino male rats resulted in the development of perineuronal edema, demyelination, microgliosis. besides, pathological changes were noticed in rats' brains of cadmium-controlled group compared with control, including perineuronal microgliosis and astrocytosis, hyperemic capillaries, and mild to moderate perineuronal and periaxonal edema.

There was also increase in number of apoptotic neurons surrounded by microglial cells, while similar results were reported by Wang and Du (25), who showed that prolonged exposure to cadmium generated accumulative toxic effects in liver, kidneys, central and peripheral nervous systems resulting from precipitation of cadmium and increased permeability of blood brain barriers.

It was stated by Manton and Cook (26) that the mechanism of neurotoxicity with heavy metals is not completely understood but the anatomical and physiological nature of choroid plexus makes it a target for xenobiotics like cadmium and lead that accumulates more intensively than in cerebrospinal fluid or cerebral cortex.

Observations by Kaoud and Mekawy (27) supported the behavioral effects of cadmium reflecting nervous effects as dose-dependence increases in non-social activity and decreases the social activity in rats, including nose to genital, nose to nose contacts and frequency of fighting. Disabled cerebral functions by neurotoxicity were confirmed by histopathological and neurochemical analysis.

Yang and Fan (11) stated that severity of histological changes in brain in cadmium toxicity depends on the dose by noticing more advanced changes at medium and high doses than noticed in low dose of cadmium.

The sever changes were separation of gray matter in cerebral cortex, severe hyperemia, infiltration of eosinophils, vacuolar demyelination and increased number of apoptotic neurons.

The same researchers described ultrastructural changes including polar aggregation of heterogenous chromatin, incomplete or fused nuclear membrane, Perinuclear areas expansion, abnormal folding in mitochondrial membranes and decreased synaptic cleft areas, so they concluded that cadmium causes microscopical and ultrastructural changes in infant mice cerebral cortex.

Similar results were obtained by Afifi and Embaby (28) through giving rats 5 mg /Kg B.W of cadmium. The cerebral cortex revealed severe degenerative changes in pyramidal and granular cells and ultrastructural changes including rough endoplasmic reticulum and Golgi apparatus

expansion, mitochondrial swelling and Polar orientation of nuclear chromatin besides demyelination in neuronal axons and vacuolation of neuropil, and they noticed less severe changes when animals were treated with ascorbic acid, giving indication of the protective rule of the antioxidants against cadmium neurotoxicity.

It was stated by Borges *et al.* (29) that cadmium increases lipid peroxidation and levels of reactive oxygen species in neural plates.

This was supported by Yuan *et al.* (30) who explained that incidence of neuronal apoptosis was connected to ROS production because of disturbances in calcium metabolism and disruption of mitochondrial membranes activity, resulting in activation of caspas-3, caspas-9, and PARP concluding that apoptosis being activated through mitochondrial -caspase signaling pathway and this may explain the histopathological changes in our study.

## Conclusion

Cadmium intense the occurrence of lesions induced by *Toxoplasma gondii* in the brain tissue of the rats, considering that all noticeable lesions ranged from mild to moderate in severity, and the variance between groups may be related to the nature of the pathogens.

## Acknowledgements

We would like to convey our thanks to the College of Veterinary Medicine, University of Mosul, and to the workers in the Animal House for their support.

## Conflicts of interest

The authors declare no conflict of interests with regard to the manuscript.

## References

1. Mikael FB, Al-Saeed AT. Molecular detection and seroprevalence of Toxoplasmosis in free range local chickens (*Gallus domesticus*) in Duhok province, Iraq. *Iraqi J Vet Sci.* 2020;34(2):247-252. DOI: [10.33899/ijvs.2019.125885.1173](https://doi.org/10.33899/ijvs.2019.125885.1173)
2. Sakban FM, A'aiz N.N. Investigate the *Toxoplasma gondii* infection in the consumed beef in Al-Diwaniyah province. *Iraqi J Vet Sci.* 2020;34(2):95-99. DOI: [10.33899/ijvs.2020.164336](https://doi.org/10.33899/ijvs.2020.164336)
3. Kim H, Kim Y, Kang S, Lee H, Rhie H, Ahn H, Lee S. Prevalence of *Toxoplasma gondii* in stray cats of Gyeonggi-do, Korea. *Korean J Parasitol.* 2008;46(3):199-201. DOI: [10.3347/kjp.2008.46.3.199](https://doi.org/10.3347/kjp.2008.46.3.199)
4. Taylor MA, Coop RL, Well RL. *Veterinary parasitology.* 4<sup>th</sup> ed. Chichester: Wiley Blackwell; 2016. 144-145 p.
5. Hill D, Dubey JP. *Toxoplasma gondii*, transmission, diagnosis and prevention. *Clin Microbiol Infect.* 2002;8(10):634-640. DOI: [10.1046/j.1469-0691.2002.00485.x](https://doi.org/10.1046/j.1469-0691.2002.00485.x)
6. Montoya JG, Remington JS. Management of *Toxoplasma gondii* infection during pregnancy. *Lin Infect Dis.* 2008;47(4):554-566. DOI: [10.1086/590149](https://doi.org/10.1086/590149)
7. Mikael FB, Al-Saeed AT. Molecular detection and seroprevalence of toxoplasmosis in free range local chickens (*Gallus domesticus*) in Duhok province, Iraq. *Iraqi J Vet Sci.* 2020;34(2):247-252. DOI: [10.33899/ijvs.2019.125885.1173](https://doi.org/10.33899/ijvs.2019.125885.1173)
8. Abu-Dalbou M, Ababneh M, Giadinis N, Lafis L. Ovine and caprine toxoplasmosis (*Toxoplasma gondii*). *IJVST.* 2010;2(2):61-76. [\[available here\]](#)
9. Montoya JG, Leisenfeld O. Toxoplasmosis. *Lancet.* 2004;363:1965-1976. DOI: [10.1016/S0140-6736\(04\)16412-X](https://doi.org/10.1016/S0140-6736(04)16412-X)
10. Weiss LM, Dubey JP. Toxoplasmosis: A history of clinical observations. *Int J Parasitol.* 2009;39(8):895-901. DOI: [10.1016/j.ijpara.2009.02.004](https://doi.org/10.1016/j.ijpara.2009.02.004)
11. Yang XF, Fan GY. Effect of cadmium exposure on the histopathology of cerebral cortex in juvenile mice. *Biol Trace Elem Res.* 2015;165(2):167-172. [\[available here\]](#)
12. Jaafar RS. Bioremediation of lead and cadmium and the strive role of *Pediococcus pentosaceus* probiotic *Iraqi J Vet Sci.* 2020;34(1):51-57 DOI: [10.33899/ijvs.2019.125581.1092](https://doi.org/10.33899/ijvs.2019.125581.1092)
13. Rees TJ. The toxicology of mate reproduction [master's thesis]. Port Smith: Port Smith University; 993. 186 p.
14. Sabolic I, Linbojevic M, Herkkramberger CM, Brown D. Cadmium - metallothionine endocytosis of brush border transports in rat renal proximal tubules. *Renal Physiol.* 2002;283:1389-1402. DOI: [10.1152/ajprenal.00066.2002](https://doi.org/10.1152/ajprenal.00066.2002)
15. Al-Derawi KH. Effects of cadmium chloride on some endocrine glands (thyroid and adrenal) in male rats (*Rattus norvegicus*). *Iraqi J Vet Sci.* 2018;32(2):211-217. DOI: [10.33899/ijvs.2019.153851](https://doi.org/10.33899/ijvs.2019.153851)
16. Health line. Cortisone, oral tablet. University of Illinois. 2018. [\[available at\]](#)
17. Soulsby EL. *Helminths, arthropods, and protozoa of domesticated animals.* 7<sup>th</sup> ed. London: Bailliere; 1986. 680 p.
18. Dubai JP, Thalliez MD. Persistence of *Toxoplasma gondii* tissue cysts in edible tissues of cattle fed *Toxoplasma gondii* Oocysts. *Am J Vet Res.* 1993;54(2):270-273. [\[available here\]](#)
19. Luna LG. *Manual of histologic staining methods of the armed forces institute of pathology.* 3<sup>rd</sup> ed. New York: McGraw-Hill book company; 1968. 1-71 p.
20. Attarbashee RK, Abu-Raghif A. Comparative treatment of induced ulcerative colitis in male rat model by using cinnarizine and sulfasalazine. *Iraqi J Vet Sci.* 2020;34(2):465-472. DOI: [10.33899/ijvs.2019.126170.1254](https://doi.org/10.33899/ijvs.2019.126170.1254)
21. Ibrahim SM, Handool KO, Abdul AA, Abu J, Yusof SM, Ibrahim M, Yusof LM. Histological evaluation of the possible role of Na<sup>+</sup>/ H<sup>+</sup> entipporter and anion exchanger in endochondral ossification activities of secondary bone healing in rats. *Iraqi J Vet Sci.* 2020;34(2):465-472. DOI: [10.33899/ijvs.2019.125832.1165](https://doi.org/10.33899/ijvs.2019.125832.1165)
22. Alkhalidy KH, Alekealy KA, Almialy HM. Histopathological study of some internal organs in cats infected with *Toxoplasma gondii*. *Al-Qadesyia J Vet Sci.* 2014;13(2):11-15. DOI: [10.13140/RG.2.2.11928.03840](https://doi.org/10.13140/RG.2.2.11928.03840)
23. Al-Saidya AM, Al-Kennany ER. Pathological and histochemical study on cats and mice experimentally infected with *Toxoplasma gondii*. *Iraqi J Vet Sci.* 2006;20(2):249-263. DOI: [10.33899/ijvs.2006.45821](https://doi.org/10.33899/ijvs.2006.45821)
24. Al-Khanaq MN, Jasim GA. Study of histopathological changes in white male rats experimentally infected by *Toxoplasma gondii*. *Al-Qadesyia J Vet Sci.* 2015;14(2):6-11. [\[available here\]](#)
25. Wang B, Du Y. Cadmium and its neurotoxic effects. *Oxidat Med Cellul Longevity.* 2013;898034:1-12. DOI: [10.1155/2013/898034](https://doi.org/10.1155/2013/898034)
26. Manton WI, Cook JD. High accuracy (stable isotope solution) measurements of lead in serum and cerebrospinal fluid. *Brit J Indust Med.* 1984;41(3):313-319. [\[available here\]](#)
27. Kaoud HA, Mekawy MM. Effect of cadmium pollution on neuro morphology and function of brain in mice offspring. *Nat Sci.* 2011;9(4):28-35. [\[available here\]](#)
28. Afifi OK, Embaby AS. Histological study on the protective role of ascorbic acid on cadmium induced cerebral cortical neurotoxicity in adult male albino rats. *Journal of microscopy and ultrastructure.* 2016;4(1):36-45. DOI: [10.1016/j.jm.2015.10.001](https://doi.org/10.1016/j.jm.2015.10.001)
29. Borges VC, Santos FW, Rocha JB, Nogueira CW. Heavy metals modulate glutamatergic system in human platelets. *Neurochem Res.* 2007;32(6):953-958. DOI: [10.1007/s11064-006-9231-7](https://doi.org/10.1007/s11064-006-9231-7)
30. Yuan CY, Jiang XH, Xu XH. Cadmium-induced apoptosis in primary rat cerebral cortical neurons culture is mediated by a calcium signaling pathway. *PLoS One.* 2013;8:1-4. Doi: [10.1371/journal.pone.0064330](https://doi.org/10.1371/journal.pone.0064330)

ومعاملة بكلوريد الكاديوم بحقنه في الخلب بجرعة ١,٥ ملغم/كغم مرة واحدة في الأسبوع، ومجموعة مخمجه بطفيلي المقوسات ومعاملة بعقار الهيدروكورتيزون بحقنه في العضل بجرعة ٠,٥ ملغم/كغم مرة واحدة في الأسبوع. بعد ٣٠ يوماً من المعاملة لكل مجاميع التجربة تمت التضحية بالحيوانات وإجراء الفحص المرضي العياني والنسجي على ادمغه الجرذان. أظهرت النتائج وجود تغيرات في نسيج الدماغ للمجموعة المحقونة بطفيلي المقوسات الكوندية حيث لوحظت الأكياس النسجية للطفيلي في اللب الدماغي مع وجود وذمة طفيفة حول المحاور العصبية، بينما كانت هناك تغيرات إضافية للمجموعة المعاملة بكلوريد الكاديوم تمثلت بتجمع الخلايا النجمية حول الخلايا العصبية مع وجود الوذمة حول الخلايا العصبية وإزالة النخاعين في المحاور العصبية، بينما لم تظهر المجموعة المخمجه والمعاملة بالكورتيزون اختلافاً عن المجموعة المخمجه بالطفيلي فقط. لقد تم استنتاج أن إضافة الكاديوم يزيد من شدة التغيرات المرضية التي يحدثها طفيلي المقوسة الكوندية في حين لا يؤثر إعطاء عقار الكورتيزون على شدة الإصابة للفترة المستخدمة للتجربة. وان التغيرات المرضية الملاحظة كانت من طفيفة إلى متوسطة الشدة. وان اختلاف التغير في الصورة النسجية قد يعود للخصوصية الامراضية لكل من العاملون.

## دراسة مقارنة لتأثير المعاملة بكل من الكاديوم والهيدروكورتيزون في أدمغة الجرذان المخمجة تجريبياً بالمقوسات الكوندية

كرم هاشم الملاح<sup>١</sup>، سري سالم أغوان<sup>٢</sup> وقيس طالب العبيدي<sup>٣</sup>

<sup>١</sup>فرع الأمراض وأمراض الدواجن، <sup>٢</sup>فرع الأحياء المجهرية، <sup>٣</sup>فرع الطب الباطني والوقائي، كلية الطب البيطري، جامعة الموصل، الموصل، العراق

### الخلاصة

لمعرفة تأثير كل من كلوريد الكاديوم والكورتيزون على الخمج التجريبي بطفيلي المقوسات الكوندية من خلال دراسة نسيج الدماغ في الجرذان تم تصميم الدراسة الحالية. استخدم فيها ٢٤ من ذكور الجرذان البيضاء البالغة، قسمت إلى ٤ مجاميع، مجموعة سيطرة غير معاملة، مجموعة الخمج بطفيلي المقوسات الكوندية أعطت الخمج بحقن ٨٠ كيس نسجي في الخلب لكل حيوان، ومجموعة مخمجه بطفيلي المقوسات