



Histopathological alterations of male and female reproductive systems induced by alloxan in rats

H. Kh. Ismail 

Department of Pathology and Poultry diseases, College of Veterinary Medicine, University of Mosul, Mosul, Iraq

Article information

Article history:

Received September 1, 2019

Accepted October 21, 2019

Available online September 7, 2020

Keywords:

Histopathology

Alloxan

Ovaries

Testis

Epididymis

Correspondence:

H. Kh. Ismail

hana_khismail@yahoo.com

Abstract

The objective of this study is to determine the histological effects experimentally induced by injection of alloxan 100 mg/kg B.w. on the histopathological structure of reproductive organs of male and female albino rats. The results showed that treatment with alloxan cause alteration in testis include irregular shape and size of seminiferous tubules, irregular division of spermatid cells, degeneration and necrosis of Sertoli cells and paucity of sperms in the lumen of tubules. While histological examination of epididymis showed the lumen of it free from sperms, thickening of muscular layer and interstitial tissue between the epididymis canal. The histological alteration of female reproductive organs includes disturbances in development of primary follicles of ovaries, hemorrhage in the interstitial tissue as well as atrophy in the uterine glands with hyperplasia of the epithelial cells of uterus. The conclusion of this study showed that alloxan cause histological alteration in reproductive organs of male and female rats.

DOI: 10.33899/ijvs.2020.126626.1351, ©2020, College of Veterinary Medicine, University of Mosul.

This is an open access article under the CC BY 4.0 license (<http://creativecommons.org/licenses/by/4.0/>).

Introduction

Oxidative stress is a status results from the imbalance between the oxidative agents and the antioxidant system leading to production of free radicals, which have a role inducing harmful effects on living tissues (1). Alloxan used to cause type I diabetes mellitus (2) it considers as a cause of free radicals' production especially reactive oxygen species (ROS) like superoxide anion radicals which transformed into hydrogen peroxide (3). Numerous studies have demonstrated the role of oxidative stress in many pathological conditions (4) including male and female reproductive abnormalities which characterized by infertility, in ability to fertilize and effects the functions of sperms which decrease in sexual behavior (5). Also, female reproductive system affected by oxidative stress via genital mutability during and after reproductive period, as well as it affects the functional process starting from the maturity of oocyte to the ovulation, implantation of blastocytes and lysis of corpus luteum (5). Alloxan cause increase the blood glucose, this leads to

oxidative stress which cause structural and functional reproductive impairment, finally contribute infertilities (6).

Material and methods

Animals

Twenty adult male and female (females separated from) albino rats 200-250 g. The animals obtained from house of laboratory animal in Veterinary Medicine College, University of Mosul. The animals were kept in plastic cages and maintained under laboratory controlled. The rats had free water and food.

Grouping of experiments

Rats were divided into four groups included diabetic and normal (control group). The first and second groups 5 male and 5 females considered as control. The third and fourth groups 5 male and 5 females are diabetic groups.

Induction of diabetic mellitus

Diabetes was induced in the male and female albino rats by single subcutaneous injection with the dose 100mg /kg BW of alloxan according to previous study (7). The rat fasted 12 hours before and after alloxan injection.

Rats were allowed to drink 5% glucose solution over night to prevent hypoglycemia (8,9).

The alloxan treated rats were confirmed the accuracy of diabetes by examining the urine using tap detector once every three days for month for glucose urea to ensure that the rats do not return to normal state. Following a month of treatment with alloxan, all animals were euthanized with diethyl ether.

Removing of testes and epididymis of male rats, ovaries and uterus of female rats was done immediately then fixed in 10% neutral buffer formalin for 72 hours before starting the process of histological slides.

After fixation, dehydration in a series of increasing alcohol concentration and embedded in paraffin wax was used. The section of 5 microns thickness was stained by hematoxylin and eosin and examined by light microscope (10).

Result

Histopathological findings induced diabetes by alloxan after month cause histological changes in the testes characterized by irregular shape and size of seminiferous tubules, irregular division of germ cells, with degeneration and necrosis of Sertoli cells, paucity of sperms into the lumen of tubules comparing with control group (Figure 1).

The histopathological examination of epididymis of diabetic rats showed thickening of muscular layer and interstitial tissue between the epididymis canal, the lumen of epididymis free from sperms, degeneration and necrosis of epithelial cells lining the epididymis canal also observed, while the control group showed the normal architecture of epididymis (Figure 2).

Moreover, different histological section of ovaries from the female control group indicate well development of ovarian follicles, normal blood vessels and normal stromal cells, while the ovarian section of female rats treated with alloxan showed histopathological changes include disturbance in the development of ovarian follicles, reduction in ovarian follicle number with congestion of blood vessels and vacuolar degeneration of granulosa cell layer, also numerous empty cystic follicles, with decrease in oogenesis and depletion of corpus luteum and atretic follicles also observed. The uterine tissue sections from female control group showed common uterine histology, while uterine sections of female rats treated with alloxan showed atrophy of uterine glands, thickening of muscular layer, myometrium, congestion of blood vessels with infiltration of inflammatory cells (Figure 3).

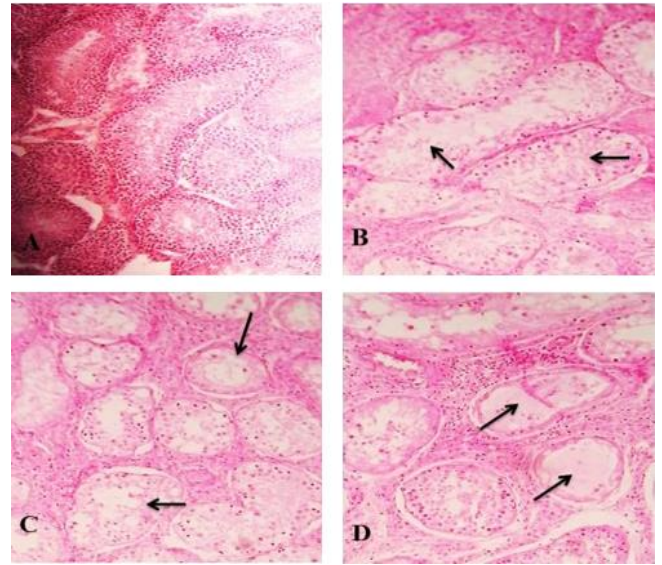


Figure 1: Micrograph of rat Testis, treated with alloxan. (A) control group showed normal architecture. (B) irregular shape and size of seminiferous tubules, irregular division of germ cells (arrow). (C) degeneration and necrosis of Sertoli cells (arrow). (D) paucity of sperms in the lumen of tubules (arrow). H&E, 100x.

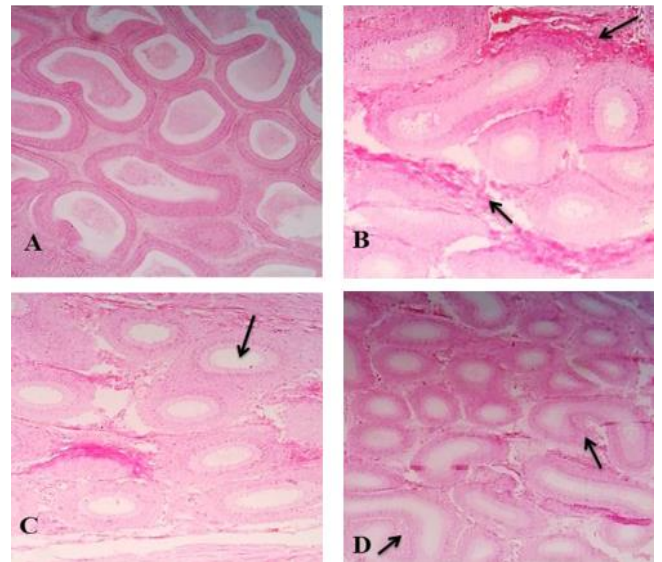


Figure 2: Micrograph of rat epididymis, treated with alloxan. (A) control group showed normal architecture. (B) thickening of muscular layer and interstitial tissue between the epididymis canal (arrow). (C) the lumen of epididymis free from sperms (arrow). (D) degeneration and necrosis of epithelial cells lining the epididymis canal (arrow). H&E, 40x.

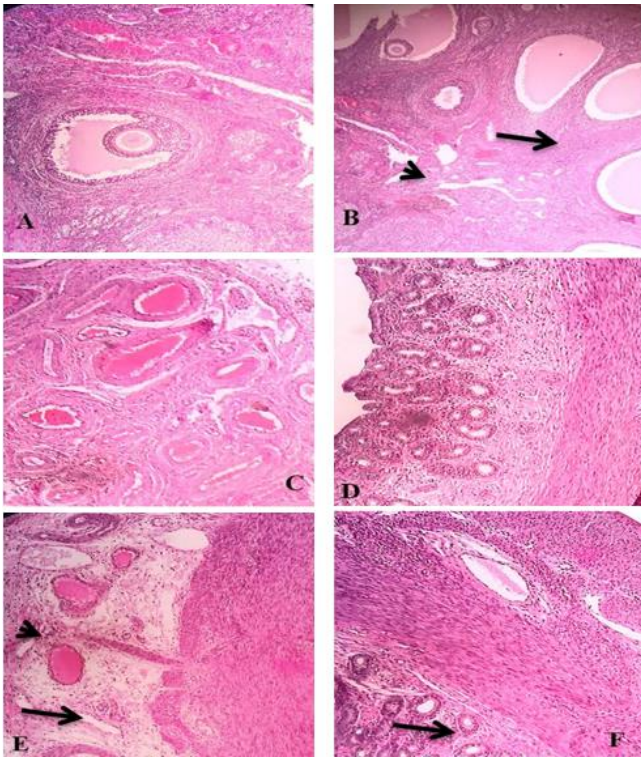


Figure 3: Micrograph of rat ovaries and uterus, treated with alloxan. (A) control group showed normal architecture of ovary. (B) disturbance in the development of ovarian follicles (arrowhead), with congestion of blood vessels (arrow) and Hyper distention of multiple antral follicles. (C) ovarian pulp with congested veins. (D) control group showed normal architecture of uterus. (E) atrophy of uterine glands (arrow) with congestion of blood vessels (arrowhead). (F) thickening of myometrium with infiltration of chronic inflammatory cells. H&E, 100x.

Discussion

Diabetes mellitus is a metabolic disease which characterized by hyperglycemia which induced oxidative stress (11). This will cause alteration of sperm function and sperm damage then decrease fertility (5). This occur due to stimulation detriment blood testes barrier (BTB) changes which induce alteration of testis that cause disrupting the metabolic action between cellular content of BTB with the consequences on sperm quality and fertility (12).

Hyperglycemia induce oxidative stress this associated with failure of testis function to dysfunction because the testicular tissue and spermatocytes are susceptible to free radical's damage due to high level of poly unsaturated fatty acid, with low oxygen tension and with lack of antioxidant defense mechanism (13,14). This will cause alteration in the histological structure of both seminiferous tubules and

epididymis in diabetic animals, this result agrees with the results reported by (15). Hyperglycemia has adverse effect on the density and motility of the sperm as a result of alteration in the production of energy and free radical's management (15). Diabetes also cause reduce the concentration of testosterone, androgen binding protein, sialic acid in the epididymis tissue, this will have effect on the secretory activity and the capacity of epididymal epithelium which lead to defective sperm maturation (16). These results of our study agree with results of researchers (17). Also, hyperglycemia has harmful effects on female reproductive function (18,19) and affect the development of blastocytes (20).

Hyperglycemia induced histopathological and morphological alteration of ovaries and uterus (21). These resulting in reproductive sterility and gonad atrophy and cause disturbances in primary follicles development, in agreement with results (22) that found hyperglycemia cause disturbances in the ovarian follicles development, also agreement with researchers (23,24). The vascular changes in the uterus are due to the level of glucose, the hyperglycemia which occur due to hypoinsulinemia, these results reported by (25). Hyperglycemia cause endocrine disorder that leads to multi system dysfunction (26). The main reproductive problems include disturbances in folliculogenesis and ovulation which result in low fertility.

Conclusion

This study concluded that the induction of diabetes mellitus by using of alloxan cause severe effect in the male and female reproductive organs.

Acknowledgement

The author would like to express thanks to College of Veterinary Medicine, University of Mosul to support current study.

Conflict of Interest

The authors declare that no conflict of interest exists.

References

1. Betteridge DJ. What is oxidative stress? *Metabolism*. 2000;49(1):3-8. Doi: [10.1016/s0026-0495\(00\)80077-3](https://doi.org/10.1016/s0026-0495(00)80077-3)
2. Wilson GL, Patton NJ, McCord JM, Mullins DW, Mossman BT. Mechanisms of streptozotocin- and alloxan-induced damage in rat B cells. *Diabetol*. 1984;27(6):587-91. Doi: [10.1007/bf00276973](https://doi.org/10.1007/bf00276973)
3. Agarwal A, Prabakaran SA, Said TM. Prevention of oxidative stress injury to sperm. *J Androl*. 2005;26(6):654-60. Doi: [10.2164/016](https://doi.org/10.2164/016)
4. Ghilissi Z, Atheymen R, Boujbiha MA, Sahnoun Z, Makni AF, Zeghal K, El Feki A, Hakim A. Antioxidant and androgenic effects of dietary ginger on reproductive function of male diabetic rats. *Int J Food Sci Nutr*. 2013;64(8):974-8. Doi: [10.3109/09637486.2013.812618](https://doi.org/10.3109/09637486.2013.812618)

5. Wagner H, Cheng JW, Ko EY. Role of reactive oxygen species in male infertility: An updated review of literature. Arab J Urol. 2018;16(1):35-43. Doi: [10.1016/j.aju.2017.11.001](https://doi.org/10.1016/j.aju.2017.11.001)
6. Zohra G, Khaled H, Mongi S, Zouheir S, Khaled MZ, Abdelfattah E, Ahmed H. Effect of *Nigella sativa* seeds on reproductive system of male. Afr J Pharm Pharmacol. 2012;6(20):1444-1450. Doi: [10.581/819](https://doi.org/10.581/819)
7. Steger RW, Rabe MB. The effect of diabetes mellitus on endocrine and reproductive function. Proc Soc Exp Biol Med. 1997;214(1):1-11. Doi: [10.3181/00379727-214-44064](https://doi.org/10.3181/00379727-214-44064)
8. Katsumata K, Katsumata Y. The potentiating effect of the simultaneous administration of tolbutamide, glibenclamide, and gliclazide on the development of alloxan-induced diabetes in rats. Horm Metab Res. 1990;22(1):51-2. Doi: [10.1055/s-2007-1004848](https://doi.org/10.1055/s-2007-1004848)
9. Mohammed IH, Kaky ES. Effect of *Prosopis farcta* extracts on some complications (hematology and lipid profiles) associated with alloxan induced diabetic rats. Iraqi J Vet Sci. 2020;34(1):45-50. Doi: [10.33899/ijvs.2019.125574.1089](https://doi.org/10.33899/ijvs.2019.125574.1089)
10. Suvarna K, Layton CH, Bancroft J. Bancroft's theory and practice of histological techniques. 8th ed. New York: Elsevier Press; 2018. 1-30 p. Doi: [10.1016/b978-0-443-10279-0.50010-5](https://doi.org/10.1016/b978-0-443-10279-0.50010-5)
11. Koichi S, Taketo O. Inhibitory effect of glutathione on the generation of hydroxyl radicals in the reaction system of glutathione alloxan. Chem pharm Bull. 1991;39(3):737-742. Doi: [10.1248/cpb.39.737](https://doi.org/10.1248/cpb.39.737)
12. Amaral S, Moreno AJ, Santos MS, Seica R, Ramalho SJ. Effects of hyperglycemia on sperm and testicular cells of Goto-Kakizaki and streptozotocin-treated rat models for diabetes. Theriogenol. 2006;66(9):2056-67. Doi: [10.1016/2006.06.006](https://doi.org/10.1016/2006.06.006)
13. Singh S, Malini T, Rengarajan S, Balasubramanian K. Impact of experimental diabetes and insulin replacement on epididymal secretory products and sperm maturation in albino rats. J Cell Biochem. 2009;108(5):1094-101. Doi: [10.1002/jcb.22337](https://doi.org/10.1002/jcb.22337)
14. Garris DR, Garris BL. Diabetes (db/db) mutation-induced ovarian involution: Progressive hypercytolipidemia. Exp Biol Med. 2003;228(9):1040-50. Doi: [10.1177/153537020322800909](https://doi.org/10.1177/153537020322800909)
15. Garris DR, Garris BL. Diabetes (db/db) mutation-induced female reproductive tract hypercytolipidemia: Estrogenic restoration of utero-ovarian indices. Reprod Toxicol. 2004;18(5):641-51. Doi: [10.1016/j.reprotox.2004.04.007](https://doi.org/10.1016/j.reprotox.2004.04.007)
16. Chang AS, Dale AN, Moley KH. Maternal diabetes adversely affects preovulatory oocyte maturation, development, and granulosa cell apoptosis. Endocrinol. 2005;146(5):2445-53. Doi: [10.1210/2004-1472](https://doi.org/10.1210/2004-1472)
17. Ballester J, Munoz MC, Dominguez J, Palomo MJ, Rivera M, Rigau T, Guinovart JJ, Rodríguez JE. Tungstate administration improves the sexual and reproductive function in female rats with streptozotocin-induced diabetes. Hum Reprod. 2007;22(8):2128-35. Doi: [10.1093/68](https://doi.org/10.1093/68)
18. Agarwal A, Aponte MA, Premkumar BJ, Shaman A, Gupta S. The effects of oxidative stress on female reproduction: a review. Reprod Biol Endocrinol. 2012;29:10:49. Doi: [10.1186/1477-7827-10-49](https://doi.org/10.1186/1477-7827-10-49)
19. Devine PJ, Perreault SD, Luderer U. Roles of reactive oxygen species and antioxidants in ovarian toxicity. Biol Reprod. 2012;86(2):27. Doi: [10.1095/biolreprod.111.095224](https://doi.org/10.1095/biolreprod.111.095224)
20. Agarwal A, Virk G, Ong C, du Plessis SS. Effect of oxidative stress on male reproduction. World J Mens Health. 2014;32(1):1-17. Doi: [10.5534/wjmh.2014.32.1.1](https://doi.org/10.5534/wjmh.2014.32.1.1)
21. Jassem AY, Ismaiel HK, Jassem HM. Effect of aqueous extract of green tea on sexual efficiency in adult male rats treated with alloxan. Iraqi J Vet Sci. 2008;22(2):75-82. Doi: [10.33899/ijvs.2008.5723](https://doi.org/10.33899/ijvs.2008.5723)
22. Agarwal A, Allamaneni SS. Role of free radicals in female reproductive diseases and assisted reproduction. Reprod Biomed. 2004;9(3):338-47. Doi: [10.1016/s1472-6483\(10\)62151-7](https://doi.org/10.1016/s1472-6483(10)62151-7)
23. Cyr DG, Gregory M. Effects of octylphenol on male reproductive tissues, epididymal sperm motility, and testicular gene expression. Toxicol Letters. 2006;164:S172. Doi: [10.1016/j.toxlet.2006.07.016](https://doi.org/10.1016/j.toxlet.2006.07.016)
24. Al-Sa'aidi J A and Al-Charack A H. Ovarian morphometric evolution in two consecutive estrous cycles of female rats treated with steroid-free bovine follicular fluid antiserum. Iraqi J Vet Sci. 2020;34(2):265-271. doi: [10.33899/ijvs.2019.125923.1186](https://doi.org/10.33899/ijvs.2019.125923.1186)
25. Nayki U, Onk D, Balci G, Nayki C, Onk A, Gunay M. The effects of diabetes mellitus on ovarian injury and reserve: An experimental study. Gynecol Obstet Invest. 2015;81:424-429. Doi: [10.1159/000442287](https://doi.org/10.1159/000442287)
26. Codner E, Merino PM, Tena SM. Female reproduction and type 1 diabetes: From mechanisms to clinical findings. Hum Reprod. 2012;18(5):568-585. Doi: [10.1093/humupd/dms024](https://doi.org/10.1093/humupd/dms024)

التغيرات النسجية لتأثير الألوكسان على الجهاز التناسلي في ذكور وإناث الجرذان

هناء خليل إسماعيل

فرع الأمراض وأمراض الدواجن، كلية الطب البيطري، جامعة الموصل، الموصل، العراق

الخلاصة

هدفت الدراسة الحالية للتعرف على التأثيرات النسجية المستحدثة تجريبياً بواسطة حقن الألوكسان بجرعة 100 ملغم/كغم من وزن الجسم على التركيب النسجي للأعضاء التناسلية في ذكور وإناث الجرذان البيض. أوضحت النتائج بان المعاملة بالالوكسان أدت الى ظهور تغيرات نسجية في خصى الجرذان تمثلت باضطراب في أشكال وأحجام النبيبات المنوية مع اضطراب في انقسامات الخلايا المولدة للنطف وتتكس ونخر في خلايا سرتولي مع قلة في النطف في تجاويف النبيبات المنوية. فيما أظهر الفحص النسجي للبربخ وجود تغيرات نسجية تمثلت بخلو تجاويف القنوات البربخية من النطف مع تتخن في الطبقة العضلية والنسيج الخلالي بين القنوات البربخية. أما فيما يتعلق بالجهاز التناسلي الأنثوي فتمثلت التغيرات النسجية للمبايض بوجود اضطراب في تطور الجريبات الأولية مع وجود النزف في النسيج الخلالي، وأظهر الفحص النسجي للرحم ضمور للغدد الرحمية مع فرط تنسج الطبقة الظهارية للرحم. استنتجت الدراسة الحالية بان الألوكسان سبب تغيرات مرضية نسجية على كل من الجهاز التناسلي الذكري والأنثوي.