

Histological evaluation of the possible role of Na⁺/ H⁺ antiporter and anion exchanger in endochondral ossification activities of secondary bone healing in rats

S.M. Ibrahim^{1,6,*}, K.O. Handool¹, Thana'a M Ibrahim³, A.A. Abdul^{1,7}, J. Abu², S.M. Yusof⁴, M. Ibrahim⁵, L.M. Yusof¹

¹Department of Companion Animal Medicine and Surgery, ²Department of Veterinary Clinical Studies, ³Al-Sader General Hospital, Baghdad Al-Russafa Health Directorate, Baghdad, Iraq ⁴Department of Veterinary Pathology and Microbiology, ⁵Department of Preclinical Sciences, Faculty of Veterinary Medicine, Universiti Putra Malaysia, Serdang, UPM 43400, ⁶Department of Surgery and Theriogenology, College of Veterinary Medicine, University of Mosul, Mosul, Iraq, ⁷Department of Veterinary Surgery and Radiology, Usmanu Danfodiyo University, Sokoto, Nigeria, *Corresponding Author, Email: *Sahar2011973@yahoo.com, handoolk_k59_o@yahoo.com, jalila@upm.edu.my, mdsabri@upm.edu.my, mehdiebrahimii@gmail.com, myloqman@gmail.com

(Received July 7, 2019; Accepted September 3, 2019; Available online 12 May 2020)

Abstract

In secondary fracture healing, callus proliferate, undergo hypertrophy and the extracellular matrix becomes calcified. This step to some extent, recapitulates the embryological bone development with a combination of cellular proliferation and differentiation, increasing cellular volume and matrix deposition. The causes of the chondrocytes volume increase in secondary bone healing are poorly known, but cell membrane transporters perhaps could be implicated. We hypothesize that NHE-1 and AE-2 are among plasma membrane transporters that have a role in cellular differentiation and regulation of endochondral ossification for secondary bone fracture healing. Study of closed tibia fracture healing in 2 groups of 25 of 8-weeks-old Sprague-Dawley rats were undertaken and histological evaluation were made at 5 different time points at 1, 2, 3, 4, and 6 weeks after induction of the fracture. Histological evaluation of proliferative and hypertrophic chondrocyte zone area showed a significant difference in week 1 compared to other weeks. Immunohistochemistry study revealed a significant high level of labeling intensity of NHE-1 at the first four weeks. While labeling intensity of AE-2 showed moderate reaction at 1 and 2 weeks, that increased and reached the highest level at 3 and 4 weeks. These results suggested that NHE-1 and AE-2 had role in the endochondral ossification of secondary bone healing.

Keywords: Histology, NHE-1, AE-2, Secondary bone healing

DOI: [10.33899/ijvs.2019.125832.1165](https://doi.org/10.33899/ijvs.2019.125832.1165), ©2020, College of Veterinary Medicine, University of Mosul.

This is an open access article under the CC BY 4.0 license (<http://creativecommons.org/licenses/by/4.0/>).

التقييم النسيجي للدور المحتمل لمضاد الأيونات الصوديوم/الهيدروجين ومبادل الأيونات الشارد في أنشطة التعظم داخل الغضروف في التئام العظم الثانوي في الجرذان

سحر محمد إبراهيم^{١,٦*}، كريم عبيس هندول^١، ثناء محمد إبراهيم^٣، أبو بكر ادامو^{٥,٧}، جلييلة أبو^٢، صبري محمد يوسف^٤، مهدي إبراهيمي^٥، لقمان محمد يوسف^٤

^١ قسم الطب والجراحة الحيوانية المصاحبة، ^٢ قسم الدراسات السريرية، ^٣ قسم الأمراض والاحياء المجهرية، ^٤ مستشفى الصدر العام، دائرة صحة الرصافة، بغداد، العراق، ^٥ قسم الدراسات ما قبل السريرية، جامعة بوترا ماليزيا، سيردانغ، سيلانجور دارول إحسان، ماليزيا، ^٦ فرع الجراحة وعلم تناسل الحيوان جامعة الموصل، كلية الطب البيطري، الموصل، العراق، ^٧ قسم الجراحة والاشعة، جامعة عثمانو دان فوديو، سوكتو، نيجيريا

الخلاصة

خلال مرحلة التئام الكسور الثانوي، يتكون نسيج عظمي ويتكاثر ليصبح النسيج متعظما في الشبكة خارج الخلايا. يتكاثر الدشيد، ويخضع للتضخم ويتكلس النسيج خارج الخلايا. هذه الخطوة إلى حد ما، تلخص تطور العظام الجنينية بمرافقة التكاثر والتميز الخلوي،

الزيادة في الحجم الخلوي وترسب المادة البينية. أسباب زيادة حجم خلايا الغضروف في التئام العظام الثانوي غير معروفة جيداً، ولكن ربما يمكن أن تكون ناقلات غشاء الخلية لها دور. نحن نفترض أن كلا من مضاد الأيونات الصوديوم/الهيدروجين ومبادل الأنيون الشارد هما من بين ناقلات غشاء البلازما التي لها دور في التمايز الخلوي وتنظيم التعظم داخل الغضروف في التئام الكسر الثانوي. أجريت الدراسة على التئام كسر عظم القصبية المغلق المستحدث في مجموعتين في ٢٥ من جردان سيراغ داوولي البالغة من العمر ٨ أسابيع وتم إجراء التقييم النسيجي في ٥ فترات زمنية مختلفة ١ و ٢ و ٣ و ٤ و ٦ أسبوع بعد الكسر. أظهر التقييم النسيجي لمنطقة النطاق الغضروفي التكتاري والضخامي الفارق الكبير في الأسبوع ١ مقارنة مع الأسابيع الأخرى. وكشفت الدراسة الكيمائية النسجية المناعية مستوى وشدة كثافة عالية لمضاد الأيونات الصوديوم/الهيدروجين في الأسابيع الأربعة الأولى. في حين أظهرت نتائج الكيمياء النسجية المناعية لمبادل الأنيون الشارد رد فعل معتدل في الأسبوعين ١ و ٢، والتي ازدادت ووصلت إلى أعلى مستوى لها في الأسبوعين ٣ و ٤. هذه النتيجة تشير إلى الدور المحتمل لكل من مضاد الأيونات الصوديوم/الهيدروجين ومبادل الأنيون الشارد في التعظم داخل الغضروف للتئام الكسر الثانوي.

Introduction

Large bone defects and nonunion present the most challenging therapeutic issue to the surgeon that is often associated with significant morbidity. These defects are demanding and expensive to both the health care sector and society (1). Therefore, basic understanding in cellular bone healing mechanisms is always fundamental in developing and providing therapeutic modalities in order to maximize the process of healing and shorten the recovery period. Bones undergo development process through two main mechanisms intramembranous bone formation and endochondral bone formation (2). Bone repair adopts the similar mechanism as endochondral bone formation but the specific mechanism of repair is determined by the biomechanical environment provided (2-4). Endochondral bone ossification happens at the growth plate prior its skeletal maturity; that consist of a thin layer of perpendicular columnar chondrocytes responsible for new bone formation during longitudinal skeletal growth (5,6). The controlled rise in the size of chondrocyte and the intracellular environment regulation e.g. ion content, pH_i permit the best cellular metabolism, and it must be closely controlled via the hypertrophic process mostly by the action of the membrane transporters of the chondrocyte membrane. It is highly expected that there is a significant role of transporters which adjust the movement of Na⁺ and anions e.g., HCO⁻ across the cellular membrane as these are recognized to be crucial for the regulation of cell volume and pH_i in a wide range of cell types (6,7). The most common type of fracture healing is secondary bone fracture healing, it is improved by micromotion, and the procedure of bone fracture healing summarizes as bone development and can be reflected a form of tissue restoration (8). Endochondral ossification phenomena are the procedure of indirect bone development in which bone is made throughout a cartilage intermediate. Fracture callus of the cartilaginous portion results from the chondrogenic distinction of periosteal progenitor cells (9). In order for bone renewal in progress, the initial soft cartilaginous callus

that formed needs to be absorbed and replaced via a hard-bony callus. This phase of bone fracture healing, to some extent, runs through the embryonic bone development with a mixture of chondrocytes differentiation and proliferation, swelling chondrocytes volume, then increasing matrix deposition (10). The joining between bone development and bone regeneration has been further strengthened through a topical understanding of the role of transport proteins in the chondrocyte plasma membrane, especially the NHE-1 and AE-2 in endochondral ossification of secondary bone healing. Inhibited NHE in isolated chondrocytes was similar to the specific NHE-1 inhibitor HOE694, supporting an indication that NHE-1 is the essential isoform in chondrocytes (11). The adding of IGF-1 to chondrocytes motivates Na⁺/H⁺ exchanger-1 (12). The expression, regulation and activity of transporters in the plasma cell membrane must be implicated in coordinating the complex procedure of bone growth linear throughout driving and supporting chondrocyte proliferation, hypertrophy and apoptosis that are vital phases in lengthening of bone (5). Tattersall *et al.* (13) showed that NHE-1 is the transporter protein major isoform in chondrocytes. Decrease in the size of hypertrophic chondrocyte can cause decrease in the rate of longitudinal bone growth. Increase in expression levels of NHE-1 protein and its stimulation can induce vascular smooth muscle cell hypertrophy (14), smooth muscle cells of the pulmonary artery (15) and ventricular myocytes (16). Pharmacological inhibition of NHE-1 immediate short interfering RNA (siRNA) inhibited hypertrophy and proliferation chondrocytes (15). The inhibitory result of 5-(N-ethyl-N-isopropyl) -Amiloride (EIPA) on growth of bone is due to a decrease in chondrocytes volume and this cause delay of the chondrocytes differentiation and proliferation (11). Diisothiocyanatostilbene-2,2'-disulfonic acid disodium salt hydrate (DIDS) and EIPA reduced the size of the hypertrophic chondrocytes zone in growth plate chondrocyte hypertrophy and bone lengthening in bone rudiments of Sprague-Dawley seven days old rats through inhibition AE-2 and NHE-1 respectively (6).

Despite the crucial roles that Na⁺/H⁺ exchanger (NHE-1) and Anion exchanger (AE-2) play in plasma membranes of cells, there were no studies according to author knowledge have been attempted to evaluate the possible involvement of NHE-1 and AE-2 in secondary fracture healing in rat tibial fracture. Therefore, the present study was conducted to evaluate the role of NHE-1 and AE-2 plasma membrane transporters in chondrocytes differentiation and regulation of endochondral ossification of secondary bone fracture healing in the rat tibia.

Materials and methods

Animals

A total of twenty-five, female Sprague-Dawley rats of 8 weeks old with average weight 187 ± 10 g old, were acquired from animal house of the University Putra Malaysia and acclimatized for one week before the start of the experiment. All procedures performed in these studies were approved by the University Institutional Animal Care and Use Committee (UPM/IACUC/AUP-R028/2015) and in accordance with the ethical standards and animal utilization protocols. The animals were divided randomly into 5 experimental groups according to time of euthanasia at 1, 2, 3, 4, and 6 weeks.

After acclimatization of rats, fracture was induced on the left tibia of each animal as described below, and the contralateral limb was used as the control. The samples were collected from both fractures induced limb and non-fractured limb. Five animals were sacrificed at each time point using a high anesthetic dose of pentobarbital drug at 20 mg/kg via intraperitoneal injection. Samples were collected for histological, immunohistochemistry examination and data for analysis at the different time points following euthanasia.

Surgical procedure to create closed tibial fracture model.

The rats were fasted for 12 hours prior to surgical operation. All surgical procedures were achieved under general anesthesia using a premixed combination of Xylazine 200 mg/ml (ILium Xylazil-100, Troy Laboratories PTY Limit, Australia) and Ketamine Hydrochloride 100 mg/ml (Narketan[®]-10, Troy Laboratories PTY Limit, Australia) (17). Combination of Xylazine 5 mg/kg, Ketamine HCL 40 mg/kg, was prepared with a pre-sterilized bottle and injected intramuscularly to each rat. Xylocaine 2% 20 mg/ml, (Xylocaine[®] 2%, AstraZeneca, UK) was also injected subcutaneously for local analgesia. Routine surgical aseptic skin preparation was performed on the surgical site (lower hind limb, tibial region). A Craniolateral skin incision 4mm was made on the left knee joint using a #15 scalpel blade, (BIBraun, Germany). The tibial plateau was bear with a stainless-steel sharp probe

introduced physically through the tibial plateau cranial to the attachment of the anterior cruciate ligament and between the anterior horns of both menisci to define the region of intramedullary pin entrance. A 23 G 11/2", needle (BIBraun, B. Braun Medical AG CH-6021 Emmenbruke, Germany) was introduced at the distal end of tibia till it met resistance (Figure 1). Following the complete insertion of intramedullary pin through the tibial bone, the more extra proximal needle end was cut flush by bone cutter. The incision line was sutured with simple interrupted non-absorbable 4/0 nylon suture (Ethilon*, Ethilon. LLC.). Then, a closed fracture (3.13-3.64mm) in the whole midshaft rat tibia was induced using modified technique of Grieff (18) and Otto *et al.* (19) (Figure 1). To achieve this, three-point-bending pliers (Schippers Export BV; The Netherlands), which were created from standard earmarks pliers was used.

Inspection of the skin of the fractured limb was done for any gross injury caused by the pliers' jaws. The fracture was considered stable and left open without any additional post-operative external bandaging or splint as it was a closed-type fracture with intramedullary pin pre-fixed into the fractured bone. The animals were individually kept in cages to permit free ambulation post-surgery. A dose of 5 mg/kg Tramadol Hydrochloride (Analab Injection, LTD) was administered subcutaneously for post-operative analgesia once daily for 3 consecutive days.

Histological evaluation

Following the euthanasia, the tibiae were collected, fixed in 10% formaldehyde solution for at least 24 hours, decalcified in 10% formic acid for four days with daily changing of formic acid, processed for paraffin embedding, sectioned at 5 μ m thickness, and stained using hematoxylin and eosin (H&E) staining for both proliferative chondrocyte zone (PCZ) and hypertrophic chondrocyte zone (HCZ) evaluation.

Evaluation of immunohistochemistry (IHC) was done by using immunoperoxidase staining (ImmunoCruzTM rabbit ABC Staining System: sc-2018. USA) kit- for (NHE-1) and (AE-2) proteins. Microscopic evaluation of the intensity of protein reaction was made at randomly selected four fields at the fracture site. At least, 25 cells, we examined in any field of region of interest (ROI). Both tissue and cellular localization of NHE-1 and AE-2 in fracture secondary bone healing was semi-quantitatively determined using the scoring technique of no reaction = 0 (0%), weak reaction = 1 (<30%), mild reaction = 2 (30-60%), and strong = 3 (>60%) (20).

Immunostaining for NHE-1 and AE-2 in the fracture callus was performed using an avidin-biotin peroxidase detection system. The primary antibodies were NHE-1 and AE-2 rabbit polyclonal IgG NHE-1 and AE-2 respectively.

The primary antibody was diluted in 1:400. The sections were counterstained with hematoxylin.

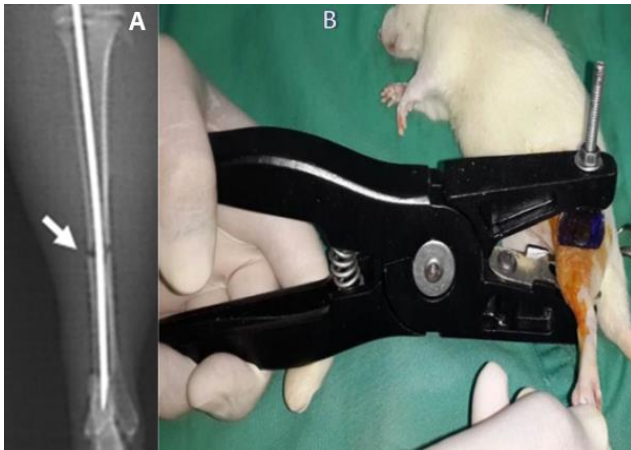


Figure 1: The photograph shows the application of the device to create tibial fracture in a rat using the modified three-point bending pliers.

ABC immunoperoxidase staining protocol using immunoCruz™ kit

Routine tissue sections were deparaffinized for five minutes each in xylene, 100% ethanol, and 70% ethanol. Deionized water was used for washing. Next sections were cover with target antigen retrieval solution (10 mM sodium citrate buffer), pH 6.0, heated at 95°C for fifteen minutes, then allowed to cool for twenty minutes. Washing in deionized water. The slides were incubated for 5-10 minutes at 0.5% H₂O₂ in PBS. Slides were washed two times in PBS. The sections were incubated for 1 hour in 1.5% blocking serum in PBS. Sections were incubated overnight at 4°C or 1 hour at 37°C using primary antibody then washed 3 times in PBS for five minutes each. Sections were incubated at 37°C by biotinylated secondary antibody for thirty to sixty minutes, washed with PBS for five minutes each. Sections were incubated by AB enzyme reagent for thirty minutes, then washed with PBS for five minutes each. Incubation of sections with peroxidase substrate for thirty seconds to ten minutes (6 minutes for skin tissue and 7 minutes for bones), washing sections in deionized water. Counter stain of sections with hematoxylin, then noticed through light microscope (21).

Statistical analysis

Data generated were organized and the means and standard error deviation (SEM) were computed. Kruskal-Wallis Test was used to analyze the data. SPSS Software version 20.0 (Armonk, NY: IBM Corp) and SAS version 9.2 were used for the data analysis.

Results

Proliferative chondrocyte zone at secondary fracture healing site

Histological sections showed PCZ percentage area was at a high level in week one $63.64 \pm 9.31\%$ after the fracture. The presence of multiple circular to menisci series of chondrocytes with a dense nucleus accompanied by inflammatory and osteoprogenitor cells- represented the phases of cell division in PCZ- during secondary bone healing (Figure 2 and 3). The PCZ then decreased gradually in the following weeks 2, 3 and 4, which were, $37.75 \pm 4.48\%$, $30.33 \pm 5.91\%$, and $22.83 \pm 7.31\%$ respectively. No PCZ area was observed at week 6.

The statistical analysis showed significant changes of the PCZ percentage area in week 1 compared to other weeks ($P < 0.01$, Wilcoxon /Kruskal-Wallis Tests) (Figure 4). The absence of the PCZ area in week 6 indicated stability of the bone fracture fragments achieved with cancellous and lamellar tissue have already formed in place.

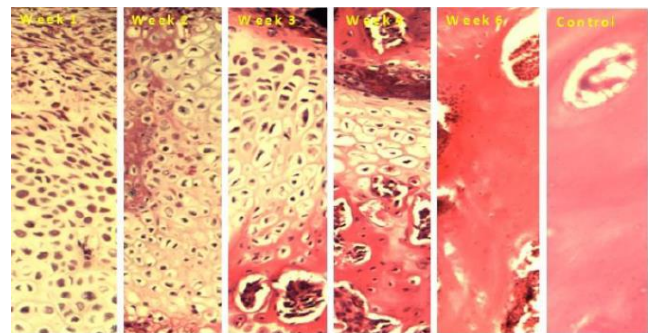


Figure 2: Histological sections of the fracture site for week 1, 2, 3, 4 and 6 post-operative and control or normal bone showing proliferation and hypertrophic chondrocyte zones in week 1, 2, 3, and 4 and bone formation in week 6 and control section.

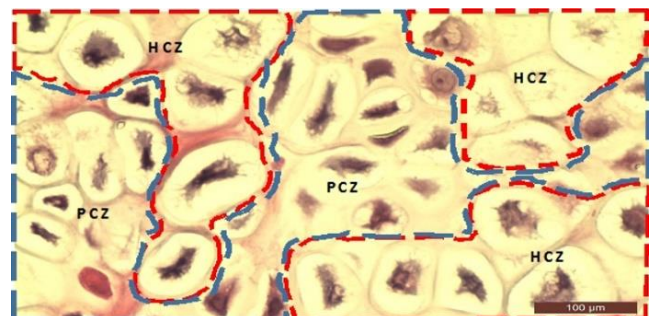


Figure 3: Histological section of proliferation and hypertrophic chondrocyte zones. Showing freehand break line of PCZ (blue break line) and hypertrophic zone chondrocytes (HCZ) (red freehand break line). H&E, 40x.

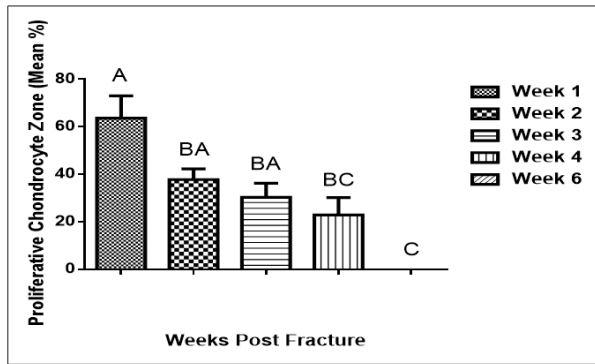


Figure 4: Graph in columns with scale bars of proliferative chondrocyte zone. Showing percentage area of all week's post-operative for tibial bone fracture healing. Error bars denotes the standard error means \pm SE. Shows significant differences in week six compared to other weeks (Kruskal-Wallis Tests).

Hypertrophic chondrocyte zone at secondary fracture healing site

Histological examination showed HCZ area started at moderate level in week 1, subsequently increased in week 2 and touched the highest level in week 3. However, it started to decline slightly in week 4 and was absent at week 6, $36.36 \pm 7.70\%$, $62.25 \pm 4.48\%$, $69.67 \pm 5.91\%$ and $57.17 \pm 5.97\%$ respectively. The statistical analysis revealed a significant increase of HCZ ($P < 0.02$) in week 3 as compared to other weeks with the means (Figure 5). The absence of HCZ in week 6 indicated the stability of the fracture fragments achieved at this stage and marked the beginning of the phase of bone remodeling.

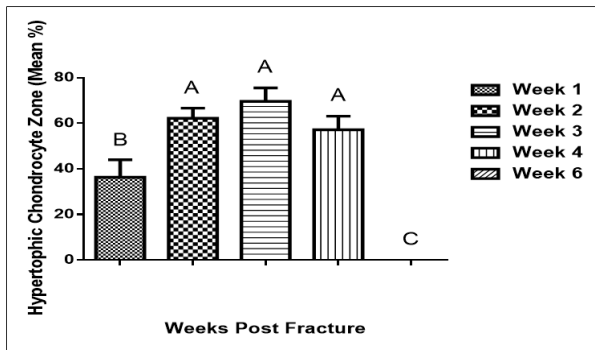


Figure 5: Chart in columns with scale bars of hypertrophic chondrocyte zone. Showing percentage area within the first six weeks following surgery of rat tibial bone fracture healing. Error bars denote the standard error means \pm SE. Shows significant differences in all week compared to week six (Kruskal-Wallis Tests).

Sodium hydrogen exchanger-1 (NHE-1): labeling intensity

Immunoperoxidase staining showed strong intensity reaction of plasma membrane at week 1, 2, 3 and 4, which subsequently decreased to reach the minimum range in week six with mean (Figure 6).

There were significant differences in cellular chondrocyte intensity reaction of NHE-1 protein ($P < 0.02$) from week one to week 6 (Figure 7).

Anion exchanger-2 (AE-2) labeling intensity

Immunoperoxidase staining showed mild labeling intensity reaction in week 1 and 2, strong intensity in week 3 and 4, and declined to the lowest range in week 6. Data for statistical analysis showed significant changes from week one to week 6 ($P < 0.02$) (Figures 8 and 9).

Statistical analysis for comparison of the data between NHE-1 and AE-2 protein intensity reactions was also performed. There were no significant differences between NHE-1 and AE-2 intensity level in each week (Figure 10).

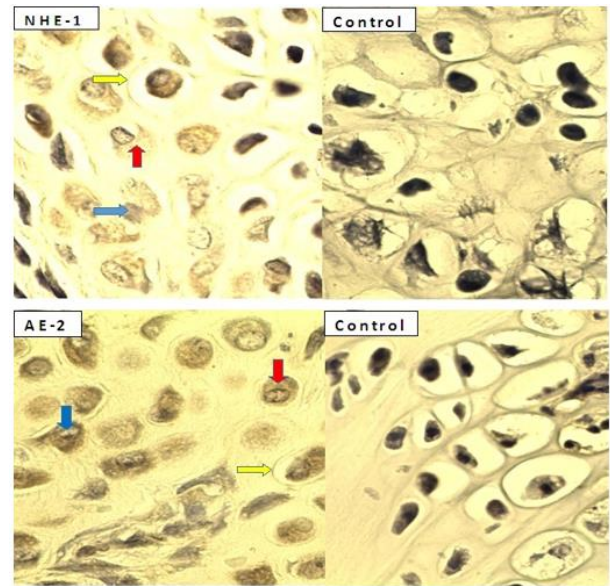


Figure 6: Histomicrograph of immunoperoxidase staining in the chondrocytes for NHE-1 and AE-2 shows positive labeling reaction for NHE-1 and AE-2 as shown by brown color staining in the plasma membrane for cytoplasm (red arrow), nucleus (blue arrow) and plasma cell membrane (yellow arrow). Immunoperoxidase staining for NHE-1 and AE-2 with primary antibody omitted (control) shows no distribution of reaction in chondrocytes plasma cell membrane, cytoplasm, nucleus localization and in the surrounding stromal tissue of the field (X40).

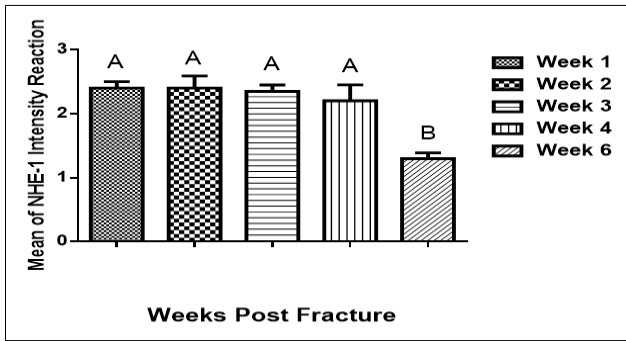


Figure 7: Chart in curve with scale bars of mean \pm SE for NHE-1 reaction distribution six weeks after surgery. A indicates significant differences with strong protein density reaction at the first four weeks compared to week six and B indicates weak protein density reaction at week 6 post-surgery compared to other weeks.

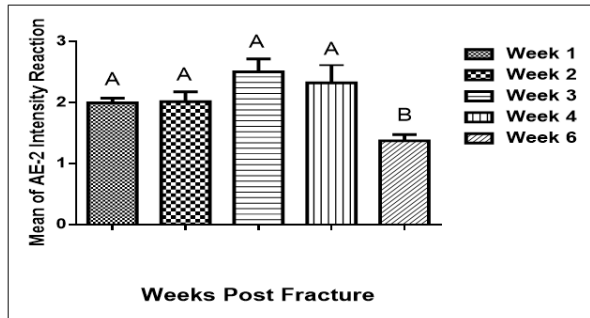


Figure 8: Chart in curve with scale bars of mean \pm SE of AE-2 reaction distribution six weeks after fracture. A indicates significant difference with high protein density reaction at the first four weeks compared to week six and B indicates weak protein density reaction in week 6 compared to other weeks.

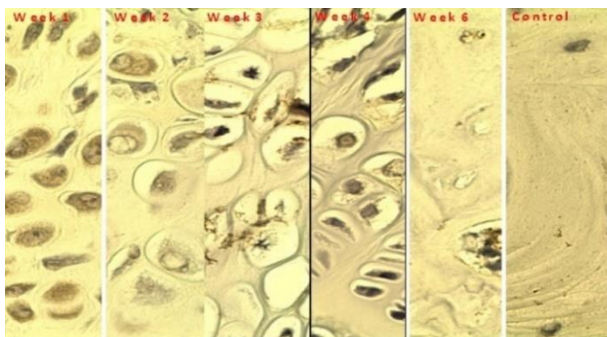


Figure 9: Immunohistochemistry intensity reaction associated with localization of transport proteins in chondrocytes of rat tibiae fracture site for all week and control.

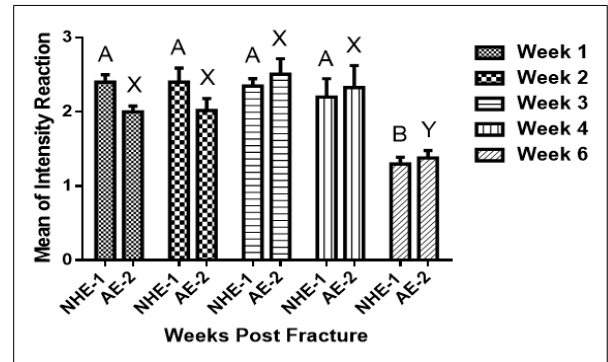


Figure 10: Immunohistochemistry intensity reaction associated with localization of NHE-1 and AE-2 in chondrocytes of rat tibiae fracture site. Chondrocyte-associated levels of NHE-1 and AE-2 re-plotted together from Figure 6 and 8 for comparison.

Discussion

Bone is a complex living tissue that continually undergoes physical changes and adapting to the mechanical load and functions placed upon it. Tissue healing in fracture bone is an amazing process because, different from healing of soft tissue that leads to scar tissue formation, the final result of normal bone healing is the renewal of the anatomy of the bone and entire return to normal function (22,23). Strong foundation in the knowledge of bone tissue healing biology allows the clinician to understand the disease process and clinically manage the problem in better ways and optimize the outcomes (24,25).

Secondary fracture healing, as in normal longitudinal bone growth results in formation of bone mediated by cellular proliferation and differentiation of chondrocytes, their cellular volume increase and consequently the matrix deposition. The causes of the chondrocytes volume increase in the osteochondral ossification process are poorly known, but cell membrane transporters such as NHE-1 and AE-2 could be implicated.

The present immunoperoxidase study of NHE-1 in chondrocytes of rat tibial fracture healing tissue showed strong intensity of NHE-1 immunostaining at weeks 1, 2, 3 and 4 which then declined gradually, reaching the minimum scores at week 6. The almost similar trend, was shown by the AE-2 expression along the period of fracture healing. This result was also in agreement with the previous study in growth plate that showed AE-2 levels to be relatively low in the proliferative chondrocytes zone of the growth plate however, reaching a higher scores in the early hypertrophic chondrocytes zone, prior to its rapid decline in the late hypertrophic growth zone of the chondrocytes (6).

The rapid proliferation of chondrocytes at an earlier phase of fracture healing as shown in this study could

require higher regulatory activities of the pH, cell volume and extracellular osmotic pressure, and these could be fulfilled by NHE-1 and AE-2 activities (17,26-28). It has also been shown in this study that the increase in the proliferative chondrocytes zone was immediately followed by the increase in the hypertrophic chondrocyte zone during the fracture-healing period. Increase area of hypertrophic chondrocytes zones could be around five and three-fold of the chondrocyte volume and surface area (24). Therefore, the role of NHE-1 in regulating intracellular pH and cell volume becomes relatively more significant. It was not clear how significance the increase in the hypertrophic zone areas can speed up the bone healing, but it mediates the subsequent bone ossification at the fracture site (2). As the cellular composition continuously changes throughout the bone healing and remodeling period, the NHE-1 could actively regulate the pH dynamic changes intra and extracellular and the maintenance of mineral homeostasis (29).

For instance, extracellular acidification is essential for bone resorption (27) during the phase of bone remodeling. While NHE-1 expression was observed to be relatively high from week 1 through week 4, AE-2 was observed to be moderately expressed at weeks 1 and 2 and increased at the highest level at week 3 and 4 before finally declined at week 6. This observation was in conjunction with the gradual decrease in the proliferative chondrocyte zones and increase of hypertrophic zones at week 3 to 4. It is interesting to assume the role of both NHE-1 and AE-2 are most pronounced when the chondrocytes reach its maximum volume and surface area depicted with the increase in the hypertrophic zone area in this study. In another word, the optimal function of both transporters seems to be during the peak periods of the fracture-healing period.

The fact that the immunostaining declined at week 6 for both NHE-1 and AE-2 indicates that they are relatively essential during fracture healing process; however, their roles are somehow insignificant in healed or normal intact bone tissue.

Conclusions

This study showed the evidence of significant changes in proliferative and hypertrophic chondrocyte zone area at the fracture site during the early phase of secondary bone healing. At the same time, the immunostaining showed the presence of relatively high level of NHE-1 and AE-2 during the first 4 weeks of bone healing and later declined at 6th week. It could be said that that NHE-1 and AE-2 possibly have roles in the endochondral ossification of secondary bone healing. Future studies should be focused to investigate the effect of the fracture healing in vivo when

the animals are treated with specific inhibitors of the transporters.

Acknowledgments

The authors are very grateful to the Faculty of Veterinary Medicine University of Baghdad and Al-Qadisiya, Iraq for the sponsorship in this research works through the postgraduate scholarship and the government of Malaysia for the FRGS grant funding (FRGS/1/2012/SGO5/UPM/02/9).

References

1. Fayaz HC, Giannoudis PV, Vrahas MS, Moran C, Pape HC, Krettek C, Jupiter JB. The role of stem cells in fracture healing and nonunion. *Int J Orthop.* 2011;35(11):1587-1597. doi: 10.1007/s00264-011-1338-z
2. Shapiro F. Bone development and its relation to fracture repair. The role of mesenchymal osteoblasts and surface osteoblasts. *Eur Cell Mater.* 2008;15:53-76. doi: 10.22203/eCM.v015a05
3. Kim HJ, Liu X, Wang J, Chen X, Zhang H, Kim SH, Cui J, Li R, Zhang W, Kong Y, Zhang J, Shui W, Lamplot J, Rogers MR, Zhao C, Wang N, Rajan P, Tomal J, Statz J, Wu N, Luu HH, Haydon RC, He T. Wnt signaling in bone formation and its therapeutic potential for bone diseases. *Ther Adv Musculoskel Dis.* 2013;5(1):13-31. doi: 10.1177/1759720X12466608
4. Sathyendra V, Darowish M. Basic science of bone healing. *Hand clinics.* 2013;29(4):473-81. doi: 10.1016/j.hcl.2013.08.002
5. Bush PG, Pritchard M, Loqman MY, Damron TA, Hall AC. A key role for membrane transporter NKCC1 in mediating chondrocyte volume increase in the mammalian growth plate. *J. Bone Miner. Res.* 2010; 25(7):1594-603. doi: 10.1002/jbmr.47
6. Loqman MY, Bush PG, Farquharson C, Hall AC. Suppression of mammalian bone growth by membrane transport inhibitors. *J Cell Biochem.* 2013;114(3):658-68. doi: 10.1002/jcb.24408
7. Hoffmann EK, Lambert IH, Pedersen SF. Physiology of cell volume regulation in vertebrates. *Phys Rev.* 2009;89:193-277. doi: 10.1152/physrev.00037.2007
8. Gerstenfeld LC, Alkhiary YM, Krall EA, Nicholls FH, Stapleton SN, Fitch JL, Bauer M, Kayal R, Graves DT, Jepsen KJ, Einhorn TA. Three-dimensional reconstruction of fracture callus morphogenesis. *J Histochem Cytochem.* 2006; 54(11):1215-28. doi: 10.1369/jhc.6A6959.2006
9. Hankenso KD, Zmmmerman G, Marcucio R. Biological perspectives of delayed fracture healing. *Injury.* 2014;45(2):S8-S15. doi: 10.1016/j.injury.2014.04.003
10. Marsell R, Einhorn TA. The biology of fracture healing. *Injury.* 2011;42(6):551-5. doi: 10.1016/j.injury.2011.03.031
11. Gibson JS, McCartney D, Sumpter J, Fairfax TPA, Milner PI, Edwards HL, Wilkins RJ. Rapid effects of hypoxia on H⁺ homeostasis in articular chondrocytes. *Pflugers Arch Eur J Physiol.* 2009;458:1085-1092. doi: 10.1007/s00424-009-0695-6
12. Tattersall AL, Wilkins RJ. Modulation of Na⁺/H⁺ exchange isoforms NHE1 and NHE3 by insulin-like growth factor-1 in isolated bovine articular chondrocytes. *J Orthop Surg Res.* 2008;26:1428-1433. doi: 10.1002/jor.20617
13. Tattersall AL, Meredith D, Furla P, Shen MR, Ellory JC, Wilkins RJ. Molecular and functional identification of the Na⁺/H⁺ exchange isoforms NHE1 and NHE3 in isolated bovine articular chondrocytes. *Cell Physiol Biochem.* 2003;13(4):215-222. doi: 10.1159/000072424
14. Hannan KM, Little PJ. Mechanisms regulating the vascular smooth muscle Na⁺/H⁺ exchanger (NHE-1) in diabetes. *Revue Canadienne de Biochimie et Biologie.* 1998;76(5):751-759. doi: 10.1139/o98-093

15. Yu L, Hales CA. Silencing of sodium-hydrogen exchanger 1 attenuates the proliferation, hypertrophy, and migration of pulmonary artery smooth muscle cells via E2F1. *Am J Respir Cell Mol Biol.* 2011;45(5):923-930. doi: 10.1165/rcmb.2011-0032OC
16. Fliegel L. Regulation of the Na⁺/H⁺ exchanger in the healthy and diseased myocardium. *Expert Opin Ther Targets.* 2009; 13(1):55-68. doi: 10.1517/14728220802600707
17. McKelvey D, Hollingshead KW. *Veterinary anesthesia and analgesia.* 3rd ed. New York: Mosby; 2004. 315-349 p.
18. Greiff J. A method for the production of an undisplaced reproducible tibial fracture in the rat. *Injury.* 1978;9(4):278-81. doi: 10.1016/S0020-1383(77)80044-2
19. Otto TE, Patka PM, Haarman HJTM. Closed fracture healing: A rat model. *Eur Surg Res.* 1995;27(4):277-84. doi: 10.1159/000129410
20. Fedchenko N, Reifenrath J. Different approaches for interpretation and reporting of immunohistochemistry analysis results in the bone tissue. *Diagn Pathol.* 2014;9(1):221. doi: 10.1186/s13000-014-0221-9
21. Ramos J. Technical aspects of immunohistochemistry. *Vet Pathol.* 2005;42(4):405-426.
22. Sfeir C, Ho L, Doll BA, Azari K, Hollinger JO. Bone regeneration and repair. In: Sfeir C, Ho L, Doll BA, Azari K, Hollinger JO. *Fracture Repair.* New Jersey: Humana Press; 2005. 21-44 p. doi: 10.1385/1-59259-863-3:021.
23. Abed ER, Eesa MJ, Thanoon MG. Effects of platelets rich fibrin and bone marrow on the healing of distal radial fracture in local dogs: Comparative study. *IJVS.* 2019;33(2):419-25. doi: 10.33899/ijvs.2019.163169
24. Amini S, Veilleux D, Villemure I. Three-dimensional in situ zonal morphology of viable growth plate chondrocytes: A confocal microscopy study. *J Orthop Res.* 2011;29(5):710-717. doi: 10.1002/jor.21294
25. Marsh DR, Li G. The biology of fracture healing: Optimizing outcome. *Br Med Bull.* 1999;55(4):856-869. doi: 10.1258/0007142991902673
26. Putney LK, Denker SP, Barber DL. The changing face of the Na⁺/H⁺ exchanger, NHE1: Structure, regulation, and cellular actions. *Ann Rev Pharmacol.* 2002;42:527-552. doi: 10.1146/annurev.pharmtox.42.092001.143801
27. Jansen ID, Mardones P, Lecanda F, de Vries TJ, Recalde S, Hoeben KA, Bronckers AL. AE-2a, b-Deficient mice exhibit osteopetrosis of long bones but not of calvaria. *FASEB.* 2009;23(10):3470-81. doi: 10.1096/fj.08-122598
28. Masereel B, Pochet L, Laeckmann D. An overview of inhibitors of Na⁺/H⁺ exchanger. *Eur J Med Chem.* 2003;38(6):547-554. doi: 10.1016/S0223-5234(03)00100-4.
29. Sagalovsky S. Bone remodeling: cellular-molecular biology and cytokine RANK- RANKL-Osteoprotegerin (OPG) system and growth factors. *Crimean J Exp Clin Med.* 2013;3(1-2):36-44. doi: 616-001.5:616.71-003.93.