

## Detection of microfilaria infection in horses in Mosul city

E. G. Suleiman<sup>1</sup>, S. S. Aghwan<sup>1</sup> and O. M. Al- Iraqi<sup>2</sup>

<sup>1</sup>Department of Microbiology, <sup>2</sup>Department of Internal and Preventive Medicine, College of Veterinary Medicine, University of Mosul, Mosul, Iraq

### Abstract

The study was performed on 78 horses in Mosul city were examined from April 2007 to September 2009 for the detection of microfilaria in the blood Twenty five clinically normal animals served as control. The percentage of the infection with microfilaria of *Setaria spp* was 30.76% they were sheathed, measuring 204-228  $\mu\text{m}$  within a mean of 218.4  $\mu\text{m}$  in length and 4.5-4.8  $\mu\text{m}$  within a mean of 4.62  $\mu\text{m}$  in width. A high percentage of infection was reported in females (54.28%) with significant differences from that of males. No significant differences were noticed between the healthy and these showing some clinical sings or between these treated with ivermectin or non treated. Haematological changes indicated decrease in level of hemoglobin concentration packed cell volume whereas there was significant increase ( $P \leq 0.05$ ) in total leukocytes count, anemia was macrocytic hypochromic type.

**Keywords:** Microfilaria; *Setaria spp*; Ivermectin; Equine.

Available online at <http://www.vetmedmosul.org/ijvs>

### تحديد الخمج باليرقات الخيطية الدقيقة في الخيول في مدينة الموصل

إيمان غانم سليمان<sup>1</sup> ، سرى سالم اغوان<sup>1</sup> ، أسامة موفق العراقي<sup>2</sup>

<sup>1</sup> فرع الأحياء المجهرية، <sup>2</sup> فرع الطب الباطني والوقائي، كلية الطب البيطري، جامعة الموصل، الموصل، العراق

### الخلاصة

أجريت الدراسة الحالية على 78 حيوانا من الخيول للفترة من نيسان 2007 - أيلول 2009 للكشف عن اليرقات الخيطية الدقيقة في الدم تم فحص الحيوانات سريريا واختير 25 حيوانا سويا سريريا لاعتمادهم كمجموعة سيطرة. بلغت نسبة الخمج الكلية باليرقات الخيطية الدقيقة والتي قد تعود لجنس *Setaria* 30.76% وامتازت هذه اليرقات بوجود الغمد وبطول ترواح ما بين 204-228 مايكرون وبمعدل 218.4 مايكرون وبعرض 4.5-4.8 مايكرون وبمعدل 4.62 مايكرون، تم تسجيل نسبة خمج مرتفعة في إناث الخيول وبلغت 54.28% مع وجود فرق معنوي في نسبة الخمج بين الإناث والذكور. أشارت نتائج الدراسة إلى عدم وجود فرق معنوي في نسبة الخمج بين الحيوانات السليمة سريريا والحيوانات التي عانت من بعض الأعراض السريرية كالضعف العام وفقدان الشهية والأعراض التنفسية إضافة إلى عدم وجود فرق معنوي بين الحيوانات غير المعالجة والمعالجة بالايفرمكتين بينت نتائج الدراسة ان الخمج باليرقات الخيطية الدقيقة كان له تأثير على بعض المعايير الدموية اذ لوحظ انخفاض معنوي في تركيز خضاب الدم وحجم خلايا الدم المرصوفة كما سجلت زيادة معنوية ( $P \leq 0.05$ ) في العدد الكلي لخلايا الدم البيضاء وكان فقر الدم من النوع ذي الكريات الكبيرة الحجم قليلة الصباغ.

### Introduction

Filarioid nematodes are known to occur among domestic animals all over the world (1). In equines, there are many species of nematodes in order: Spirurida, Superfamily: Filaroidae, Family, Filariidae, Onchocerhidae and these families include many genera and species that infect equines like: *Onchocerca cervicalis*,

*O. gutturosa*, *O. reticulata*, *Setaria equina* and *Parafilaria multipapillosa* (2,3), generally, species of *Onchocerca* are medium-sized filarioides which usually inhabit subcutaneous tissues ligaments and aponeuroses of large mammals whereas species of *Setaria* are found in the abdominal cavities of artiodactyls, the filariids (*Parafilaria* and *Stenphanofilaria*) are small to medium-sized subcutaneous parasites of certain mammals. All filarioid

nematodes produce larvae (microfilariae, mf) in the skin (*Onchocerca spp.*, *Parafilaria spp.*, and *Stenphanofilaria spp.*) or blood circulation (*Setaria spp.*) of the host where they are available to the haematophagus insects which operate as intermediate hosts and active vectors for the parasites (1,4).

In their normal definitive host most species of Filarioid nematode, are often very well adapted and they are well tolerated (5). The studies are reported that high percentage of infection with microfilariae in horses in different word (6-8). Horses are commonly infected with *Setaria spp.* in Asia, Europe and America (9-11).

Cutaneous Onchocercosis is common on horses in the United State of America. In fact many surveys carried out there showed that about 20-100% of horses are carried *Onchocerca microfilariae* (12). The species *Setaria equina* is a common parasite of equines in all parts of the world, the infection rate may be high and up to 50% of horses may be infected in endemic areas (13). In Iraq Yousif *et al.*, (14) diagnosed for the first time presence of microfilaria in horses in Mosul city and the species of nematode related to the genus *Setaria equina*, also two species of microfilariae were observed in blood of horses in Mosul city, one of them was identified to be *Setaria equina* (15). The aim of this study was to determine the prevalence of microfilariae in horses in Mosul city.

#### Materials and methods

A total of 78 horses from both sexes and of 3-10 years of age were examined in Teaching Veterinary Hospital (College of Veterinary Medicine, University of Mosul and from other regions in Mosul city during the period from April 2007 to September 2009 for the detection of microfilariae infection from 78 horses clinically normal horses (n =25) were served as a control Blood samples were taken from these animals and from those (78) horses showed different clinical sings (weakness depression and variable appetite). From the 78 horses 65 were not treated with ivermectin while the remaining 13 were with history of ivermectin treatment (0.2mg /kg orally) Blood samples were collected from jugular vein in EDTA tubes, Knott's technique described by (16) was used for detection of microfilaria. The diagnosis of microfilariae based on morphometric study Species of microfilaria were identified according to (5,13). Hematological examination was done by using (Automatic Full Digital Cell Counter Beckman USA) to get the total red blood cells, hemoglobin concentration (Hb), packed cell volume (PCV), mean corpuscular volume (MCV), mean corpuscular hemoglobin concentration (MCHC) and total leukocytes (17). Statistical analysis was performed by using chi- square and t-test (18).

#### Results

The number of positive samples was 24 with a total percentage of 30.76%. From Table (1) it is evident that there were a significant  $P < 0.05$  differences in percentage of infection between males (11.62%) and females (54.28%). In Table (2) microfilariae diagnosed in 20 blood samples which were collected from healthy animals with a percentage of 28.57% while the percentage of infection with microfilariae in animals showed some clinical sings such as weakness, respiratory sings depression and variable appetite was 50% no significant differences were noticed between healthy and those showing some clinical sings. In Table (3) there was no significant difference between treated and non treated horses with ivermectin and 27.69% of non treated horses were positive for microfilariae while 46.15% of treated horses were positive for microfilariae. The hematological picture elucidated in Table (4) reveals that there was a significant ( $P \leq 0.05$ ) reduction in HB PCV MCHC, with significant ( $P \leq 0.05$ ) increase MCH and total WBCs in infected horses compared with control.

Table 1: The percentage of infection with microfilariae according to sex.

Sex of animals	No. of the examined animals	No. of the positive animals	%
Males	43	5	11.62 a
Females	35	19	54.28 b
Total	78	24	30.76

Groups with different letters have significant differences of  $P \leq 0.01$ .

Table 2: Percentage of Microfilariae infection in horses showed some clinical sings and horses clinically normal.

Groups of horses	No. of the examined horses	No. of the positive horses	% of infection
Horses clinically normal	70	20	28.57 a
Horses with some clinical sings	8	4	50 a
Total	78	24	30.76

Groups with same letters have non-significant differences at  $P \geq 0.01$ .

Examination of blood by Knott's technique revealed the presence of microfilariae which may be related to species of *Setaria equina* and the identified of microfilariae based on

morphological characteristics and the site of infection Microfilariae ranged between 204-228  $\mu\text{m}$  within a mean of 218.4  $\mu\text{m}$  and the width ranged between 4.5-4.8  $\mu\text{m}$  within a mean of 4.62  $\mu\text{m}$ , and these microfilariae are sheathed and the number of microfilariae which were presence in blood film ranged between 1-2 larvae (Fig. 1).

Table 3: Percentage of Microfilariae infection between treated and non treated horses.

Groups of horses	No. of the examined horses	No. of the positive horses	%
Non treated horses	65	18	27.69 a
Treated horses	13	6	46.15 a
Total	78	24	30.76

Groups with same letters have non-significant differences at  $P \geq 0.01$ .

Table 4: Blood parameters of infected group with microfilariae and control group.

Parameters	Control	Infected
	Mean $\pm$ S.E.	Mean $\pm$ S.E.
RBC x 10 <sup>6</sup> microliter	7.44 $\pm$ 0.72	7.34 $\pm$ 0.31
Hbg/100 ml	13.27 $\pm$ 1.79	12.44 $\pm$ 1.57*
PCV %	35.53 $\pm$ 3.78	33.00 $\pm$ 5.21*
MCV %	16.64 $\pm$ 1.39	17.96 $\pm$ 1.07*
MCHC g/100 ml	10.67 $\pm$ 2.14	10.04 $\pm$ 2.75*
WBC x 10 <sup>3</sup> microliter	51.38 $\pm$ 1.37	51.96 $\pm$ 1.49*

\*  $P \leq 0.05$ .

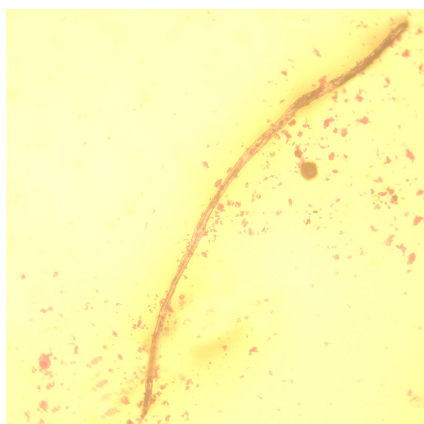


Fig. 1: Microfilaria of *Setaria spp* in blood of horse by knott's technique 40X by using digital camera.

## Discussion

In this study, the total percentage of infection with microfilariae in blood samples of horses was 30.76% the species of microfilariae which were diagnosed may be mf of *Setaria equina* these results were agreement with a study which performed in Mosul city by (15) who referred the presence mf in 10 out of 50 blood sample of horses and mf of *Setaria equina* diagnosed in 5 horses In other studies carried out in different parts of the world indicated that the high prevalence of microfilariae in horses in Asia, Europe and America (9-11), also (13) showed that the infection rate with *Setaria equina* may be high and up to 50% of horses may be infected in endemic area, while in a study done in Finland demonstrated through the examination of blood and skin that the horses and sheep may be free from Filaroid nematodes (5).

The high rate of infection with microfilariae appeared in females (54.28%) with a significant difference between males and females, was in agreement with (6,19,20) while (7) referred that the infection was more common in older horses and occurred in both sexes equally. From the Table 2 there was no significant difference in the percentage of infection between animals apparently healthy and animals showed some different clinical sings Infections with helminthes often cause chronic disease with a wide spectrum of clinical manifestations, ranging from a symptomatic to severe pathology (21). Radositis *et al.*, (22) showed a high incidence of *S. equina* infestation has been observed in horses in Europe and although no clinical illness was observed there was evidence of recent peritonitis at slaughter.

*Setaria equina* is found in the peritoneal cavity and sometimes in the scrotum, it has also been recorded from the pleural cavity lungs and eyes of the horses, with no clinical sings when worms in their normal sites, but when nervous tissues involved there is locomotor disturbances of the hind limbs and if the parasites are high in the spinal canal there may be paraplegia (13, 23) Abu-Elmagd and Ahmed (24) showed that the *Setaria equina* could affect on donkey eye with serious lesions such as continuous lacrimation and ulcerative dermatitis.

There was no significant differences between animals non-treated with ivermectin and animals had history of treatment with ivermectin the percentage of infection with microfilariae in treated animals was 46.15% and the blood of these animals examined after 7-14 days post treatment Eub-Elmagd *et al.*, (25) revealed that the treatment with ivermectin (Ivomc-MSD) by the injection 1.0 ml/50 kg B.W of one dose subcutaneously gave good results after 7days post treatment This drug was effective on adults and microfilaria of *S.equina* in horses suffering from the enlarged scrotum the efficacy of ivermectin was

demonstrated through disappearance of those clinical signs and microfilaria

Hematological parameters showed relatively significant decrease in the level of hemoglobin and packed cell volume in infected horses as compared to control groups these results were agreement studies carried out on cattle and dogs by others (26-29) and this might be due to rapid disintegration of erythrocytes causing hemolysis (27). Anemia was macrocytic hypochromic type due to significant increase in the mean corpuscular volume and reduction in the mean corpuscular hemoglobin concentration. Sharma and Pachauri (30) revealed that the filarial worms meet their nutrients requirement from the host tissues and fluids and in situ transfer of nutrients from the host tissues to the body of parasites causes various deficiency symptoms including anemia depending on the worm load of the host. The significant increase in WBC was agreement with (26-29) in cattle and dogs and (29) showed that the rise in the total leukocytes count (TLC) was indicative of chronic parasitemia and the rise in the eosinophil count was coupled with the microfilariaemia which indicated body response of defense mechanism through the parasitological action of eosinophil, the degree of lymphocytosis occurred depend upon the intensity of parasitemia.

About all of these results, the differences in the prevalence of the infection could be attributed to many factors such as the number of blood samples examined, seasons of the study (the prevalence is higher in warmer countries, where there is long seasonal activity of the mosquito vectors), animal factors (sex, age, breed, etc.), farm management and the time of blood taken because the microfilaria characterized by having the diurnal or nocturnal periodicity and the number of microfilariae are present in greatest numbers in capillary blood between 8 and 12 pm at lower temperatures and at higher barometric pressures, all of those factors would probably increase the chances of spread by insect vectors (13,19,20,22,23).

## References

1. Anderson RC. Nematoda Parasites of vertebrates, their development and transmission. The superfamily filarioidea. New York : CAB International; 2000 p.467-529.
2. Kassai T. Veterinary helminthology. 1<sup>st</sup> ed. Great Britain, Bath Press, Somerset; 1999 p.119-133.
3. Drudge JH, Lyons ET. Internal parasites of equids with Emphasis on treatment and control USA. Hoechst- Russell Agri Vet Company;1989.p.15-17.
4. Kolte SS, Satarker RN, Mane PM. Microfilaria concomitant with metastasis deposits of adenocarcinoma in lymph node fine needle aspiration cytology : A chance finding. J Cytol [Serial online] 2010 Available from : <http://www.ycytol.org/text.asp>.
5. Solisma M, Laaksonen S, Nylund M, Pitkanen E, Airakorpi R, Oksanen A. Filarioid nematodes in cattle, sheep and horses in Finland Acta Vet Scand. 2008 ; 50(1): 20-50.
6. Collins RC. Onchocerciasis of horses in South Eastern Louisiana. J Parasitol. 1973 ; 59(59): 1016-1920.
7. Staunard AA and Cello RM. *Onchocerca cervicalis* infection in horses from western United States. Am J Vet Res. 1975 ; 36(11): 1029-1031.
8. Lloyd S and Soulsby E. Survey for infection with *Onchocerca cervicalis* in horses in Eastern United States. Am J Vet Res. 1978 ; 39(1): 1962-1969.
9. Siddiqui AA, Sharma SP, Kumar M. Prevalence of *Setaria* infection in buffaloes and horses. Indian J Anim Sci. 1994 ; 66: 243-245.
10. Buchwalder R, Schuster R. Finding *Setaria equina* in horses (abstract). Angew Parasitol. 1989; 30: 127-130. (PubMed).
11. Coleman SU, Klei TR, French DD. Prevalence (Nematode : Onchocercidae) in Southeastern Louisiana horses. J Parasitol. 1985 ; 71: 512-513.
12. Lyons ET, Swerczek TW, Tolliver SC, Bair HD, Drudge JH, Ennis LE. Prevalence of selected species of internal parasites in equids at necropsy in central Kentucky (1995-1999). Vet Parasitol. 2000 ; 92: 51-62.
13. Soulsby E. Helminths, arthropods and protozoa of domesticated animals. 7<sup>th</sup> ed. Philadelphia, Bailliere Tindall, London; 1986. p.306-317.
14. Yousif YA, Hayattee ZG, Saleen AN, Joshi HC. Haemato-biochemical changes in microfilariae affected horses under field condition. J Vet Parasit. 1990 ; 4: 55-58.
15. Alousi TI, Arslan SH, Zangana IK. Study of some parasitic infections in horses in Mosul region. Iraqi J Vet Sci. 1994; 2(2): 85-91.
16. Hendrix CM. Diagnostic Veterinary Parasitology. 2<sup>nd</sup> ed. Mosby Inc. United States of America; 1998 p. 269-271.
17. Meyer DJ and Harvy JW. Veterinary Laboratory Medicine. 2<sup>nd</sup> ed. W.B. Saunders Co ; 1998 p.157-199.
18. Bruning LJ, Kintz BL. Computational handbook statistics, 2<sup>nd</sup> ed. Scott Foresman and Company, England;1977. p. 233-237.
19. Butty ET. Diagnostic study of microfilariae in blood samples of cattle in Mosul city- Iraq. Iraqi J Vet Sci. 2006; 20(2): 219-224.
20. Ottley ML, Moorhouse DE. Equine Onchocerciasis. Aust Vet J. 1978; 54(11): 545, 2 ref.
21. Maizels RM, Balic AN, Gomez-Escobar MN, Taylor MD, Allen JE. Helminths parasites-masters of regulation. Immunol Rev. 2004 ; 201: 89-116.
22. Blood DC, Radosits. Veterinary medicine. A textbook of the diseases of cattle sheep, pigs, goats and horses. 7<sup>th</sup> ed. Baillier, Tindall ; 1989.p.1065-1066.
23. Urquhart GM, Armour J, Duncan JL, Dunn AM, Jennings FW. Veterinary parasitology 2<sup>nd</sup> ed. Blackwell Science, Oxford; 2003 P.93.
24. Abu-Elmagd MM Ahmed ZG. The occurrence of *Setaria equina* in donkeys eyes and their treatment. Assiut Vet Med J. 1994 ; 31 (62): 86-90.
25. Abu-Elmagd MM, Ahmed ZG, Michael SA. Treatment of *Setaria equina* infestation with ivermectin (22, 23-Dimydroavermectin B) under the Egyptian environmental conditions. Assiut Vet Med J. 1990; 23(45): 75-79.
26. Mukhopadhyay S, Dash AP, Ravindran B. *Setaria digitata* microfilariae in mastomys couchs : an animal model for chemotherapeutic and immunobiological studies Parasitol. 1996 ; 113:323-330.
27. Sharma MC,Chinmay J. Serum mineral and haematobiochemical profile of microfilariae infected cattle in India :Its effects on production and therapy. Asian Aust J Anim Sci 2002;15(3):357-365.
28. Singh KS,Mukhopadhyay SK, Ganguly S Niyoyi D,Thiayaseelan G, Ali I. Hematological and biochemical studies of Stephanofilaria dermatitis in infected cattle of West Bengal India Res Vet Sci 2011;91(2):194-195.
29. Goggin JM,Biller DS,Rost CM, De Bey BM Ludlow CL. Ultra sonographic identification of *Dirofilaria immitis* in the aorta and liver of a dog Am J Vet Med Asso.1997;210(11):1635-1637.
30. Sharma MC and Pachauri SP Blood cellular and biochemical studies in canine dirofilariasis Vet Res Comm.1982;5: 394-300.