

The first unequivocal report of *Encephalitozoon cuniculi* in rabbits and *Encephalitozoon intestinalis* in cattle in Mosul city-Iraq

S.S. Al-Mahmood^{1*} and H.I. Al-Sadi²

¹Department of Pathology and Poultry Diseases, College of Veterinary Medicine, ²Department of Oral and Maxillofacial Surgery, College of Dentistry, University of Mosul, Mosul, Iraq, *E-mail: saevan981@yahoo.com

(Received May 28, 2014; Accepted June 7, 2014)

Abstract

The aim of present study was to report spontaneous *Encephalitozoon cuniculi* (*E. cuniculi*) infection in rabbits and *Encephalitozoon intestinalis* (*E. intestinalis*) infection in cattle in Mosul city - Iraq. Fecal samples were collected randomly from 142 rabbits and 115 cattle during the period from June, 2012 to June, 2013. Thin smears were prepared from the fecal samples and stained with different fecal stains, as well as the indirect immunofluorescent antibody technique. Infected rabbits were necropsied and pathology of the infection was described. The result showed that microsporidiosis was detected in 41 (26.9%) rabbits and in 12 (10.4%) cattle. *E. cuniculi* spores were identified in 31 out of the 41 rabbits (73.2%) and *E. intestinalis* in 7 out of the 12 cattle (58.3%). Infected rabbits showed vasculitis and granulomatous encephalitis, chronic interstitial nephritis, granulomatous hepatitis and cholangitis, vasculitis and non – suppurative pneumonia, infiltration of mononuclear cells in most layers of the intestines, and hyperplasia of lymphoid tissues. *E. cuniculi* spores were seen in the liver, kidneys and lungs. This study considered the first one that report microsporidiosis (*E. cuniculi*, *E. intestinalis*) in Mosul city - Iraq.

Keywords: Unequivocal, *Encephalitozoon cuniculi*, rabbits, *E. intestinalis*, cattle, Mosul city, Iraq

Available online at <http://www.vetmedmosul.org/ijvs>

أول تسجيل مؤكد للإصابة بداء الأبواغ الدقيقة في الأرانب والأبقار في مدينة الموصل-العراق

سيفان سعد فاضل المحمود^١ و حافظ إبراهيم محمود السعدي^٢

^١ فرع الأمراض وأمراض الدواجن، كلية الطب البيطري، ^٢ فرع جراحة الفم والوجه والفكين، كلية طب الأسنان، جامعة الموصل، الموصل، العراق

الخلاصة

كان الهدف من الدراسة الحالية تسجيل الإصابة الطبيعية بـ *Encephalitozoon cuniculi* في الأرانب و *Encephalitozoon intestinalis* في الأبقار في العراق. جمعت ١٤٢ عينة براز من الأرانب و ١٥٥ عينة براز من الأبقار خلال المدة من حزيران ٢٠١٢ إلى حزيران ٢٠١٣. عملت مسحات خفيفة من عينات البراز ولونت بملونات البراز المختلفة، فضلا عن تقنية الأجسام المضادة المناعية غير المباشرة، بالإضافة إلى قتل الأرانب المصابة وتسجيل الأفات العيانية والمجهريّة الظاهرة عليها. بينت النتائج أن الإصابة بداء الأبواغ الدقيقة وصلت إلى ٤١ (٢٦,٩٪) في الأرانب و ١٢ (١٠,٤٪) في الأبقار. تم التعرف على أبواغ *E. cuniculi* في ٣١ من أصل ٤١ عينة براز الأرانب (٧٣,٢٪) وأبواغ *E. intestinalis* في ٧ من أصل ١٢ عينة براز الأبقار (٥٨,٣٪)، كما أظهرت الأرانب المصابة طبيعياً بأبواغ *E. cuniculi* التهاب الأوعية الدموية، التهاب الدماغ الحبيبي، التهاب الكلية الخلالي المزمن، التهاب الكبد الحبيبي، التهاب الأوعية الصفراوية، التهاب الأوعية الدموية، التهاب الرئة غير القيحي، ارتشاح من الخلايا الالتهابية أحادية النواة في معظم طبقات الأمعاء، مع فرط تنسج الأنسجة اللمفاوية، كما تم ملاحظة أبواغ *E. cuniculi* في الكبد والكلى والرتنين. نستنتج من هذه الدراسة أن داء الأبواغ الدقيقة مرض شائع في الأرانب والأبقار في العراق كما أن الإصابة بالجنس *E. cuniculi* كان أكثر شيوعاً في الأرانب، والجنس *E. intestinalis* كان أكثر شيوعاً في الأبقار، وتعد هذه الدراسة أول إشارة وتسجيل لتواجد داء الأبواغ الدقيقة بشكل عام والجنسين *E. cuniculi* و *E. intestinalis* بشكل خاص في العراق، كما أنها تعد أول دراسة تصف الأفات المرضية للإصابة الطبيعية بـ *E. cuniculi* في الأرانب في العراق.

Introduction

Microsporidia are obligate intracellular microorganisms that infect a wide range of vertebrate and invertebrate hosts (1). They have been traditionally considered as protozoa but they were recently reclassified as fungi (2-4). Approximately 143 genera and more than 1,200 species are known, and at least 14 species are known to infect humans being (5). Spores are the infecting form of microsporidia, and in humans interhuman, water – borne, food – borne, transplacental, sexual, and vector routes of transmission have been described (6). *Encephalitozoon cuniculi* and *E. intestinalis* are the most wide spread microsporidia species in animals and humans and is the cause of a disease known as encephalitozoonosis (7). The zoonotic potential of *Encephalitozoon spp.* has been confirmed and microsporidia became of considerable interest of human and veterinary medicine (8). Natural variety of hosts including small and large animals and their lists were given by (9) and (10). Despite the zoonotic and scientific importance of microsporidiosis, the disease has never been studied in humans and animals in Iraq. Therefore, the aim of the present study was to report the occurrence of *E. cuniculi* in rabbits and *E. intestinalis* in cattle with emphasis on pathology of natural infection in rabbits in Mosul city/ Iraq.

Materials and methods

Fecal samples

152 rabbits fecal samples (collected randomly from local markets of Mosul city) and 115 cattle fecal samples (collected randomly from cattle bring to Teaching Hospital of College of Veterinary Medicine, University of Mosul) have been collected in period of one year (from June, 2012 to June 2013). Fecal samples were collected directly from the rectum into containers and held at 4°C in large container contained dry ice (CO₂ ice) until further assay. In the laboratory, a preservative (5-10% neutral buffered formalin – sodium acetate and 4% sodium permanganate) were added to feces at the rate of 10 ml of the preservative to each gram of the fecal specimens, and then the mixture was kept in the refrigerator at 4°C till examination (11).

Processing of fecal samples

The fecal samples were sieved through gauze and cotton to get rid of the large objects or sediments, placed in 15 ml test tubes, and centrifuged at 7500 rpm for 40 minutes. Resuspension of the sediment was made using phosphate buffered saline (PBS) and the test tubes were centrifuged at 7500 rpm for 40 minutes. The filtrate was discarded and the sediment (1 ml) from each tube was resuspended in a test tube and thus became ready for examination (12).

Staining of fecal samples for presence of microsporidia

A drop of the precipitate was placed on a glass slide and was spread by a second slide and the smear was left to dry at room temperature. The slides were then dipped in absolute methyl alcohol for fixation and left to dry at room temperature. Smears were stained quick – hot Gram – chromotrope, Weber – green modified trichrome, Ryan – blue modified trichrome (13-15), for microscopic examination.

Detection and morphometric of spores

The criteria used to define microsporidia – positive animals was the presence of one or more pinkish or pinkish – violet ovoid structure with a spore wall and a belt – like stripe, over an examination of at least 100 field (at lens 100x). Measurements of 50 spores per slide were done using optical micrometer as described by (16).

Concentration and purification of microsporidial spores

Collections of microsporidia spores from fecal samples were done according to the method described by (11). Resuspension of the sediment using PBS pH 7.2 was done and smear was prepared using a drop of the solution, and stained with Ryan – blue modified trichrome stain and examined for presence of spores (12).

Indirect immuno-fluorescent antibody technique (IIFA)

Kit manufactured by Bordier Affinity products (SA Chatanerie 2, CH-1023 Crissier, Switzerland) were used to identify *E. cuniculi* in rabbit fecal samples and *E. intestinalis* in cattle fecal. Procedure for this technique was done as mentioned by (17).

Histopathological examination

Rabbits that were positive for presence of *E. cuniculi* spores in their fecal samples were euthanized using chloroform (18). Following gross pathological examination, tissue specimens were collected from internal organs and preserved in 10% formalin for 48 – 72 hours (15). Specimens were processed for staining by the conventional methods, and stained with hematoxylin and eosin (15).

Statistical analysis

Data concerning the measurements of the spores in various experiments were analyzed using statistical software (SPSS), version 16.0 and the values were presented as mean, standard error, and range in micrometers (19).

Results

Prevalence of microsporidial infection in rabbit and cattle in this study is shown in Table (1 and 2). It is clear that the frequency of occurrence of microsporidiosis in

rabbits 41(27%) and cattle 12 (10.4%). Table (3) presents morphometric characteristics of microsporidia in this study by different stains for fecal samples (Figure 1 and 2). The result of indirect immunofluorescent antibody technique

showed that the frequency of occurrence of *E. cuniculi* in rabbits was 31 (27%) (Figure 3A) and *E. intestinalis* in cattle was 7 (10.4%) (Figure 3B).

Table 1: Prevalence of microsporidial spores in rabbits in Mosul city-Iraq

Animals	No. examined	No. positive	% of infection	No. of + <i>E. cuniculi</i>	% of positive <i>E. cuniculi</i>
Rabbits	152	41	27	31	73.2

Table 2: Prevalence of microsporidial spores in cattle in Mosul city-Iraq

Animals	No. examined	No. positive	% of microsporidia	No. of + <i>E. intestinalis</i>	% of positive <i>E. intestinalis</i>
Rabbits	115	12	10.4	7	58.4

Table 3: Measurements of microsporidial spores in rabbits and cattle

Animals	Number of positive cases	Length (μ)		Width (μ)	
		Mean \pm SE	range	Mean \pm SE	Range
Rabbits	41	2.1 \pm 0.04	1.9-2.3	0.9 \pm 0.07	0.7-1.5
Cattle	12	2.2 \pm 0.09	1.9-2.4	0.2 \pm 0.08	1.0-1.4

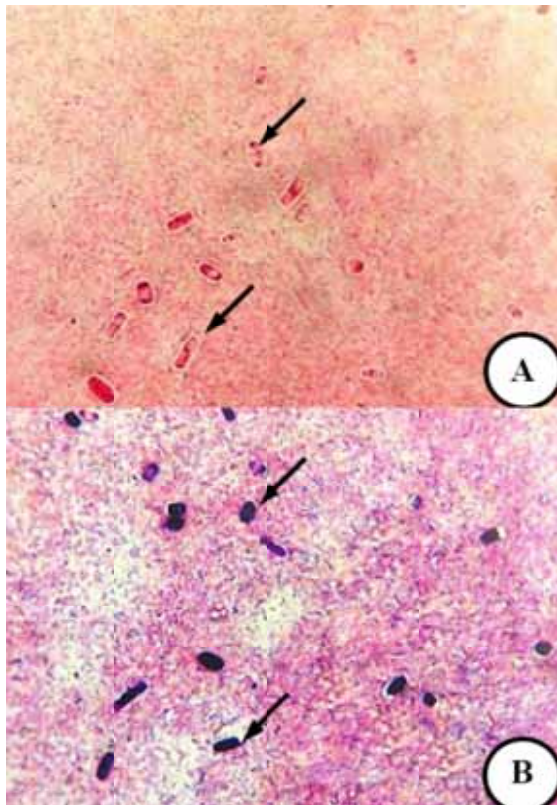


Figure 1: *E. cuniculi* spores in fecal specimen from rabbit with spontaneous microsporidiosis (arrows). [A] Modified chromotrope Ryan blue stain, [B] hot Gram chromotrope stain. X1000.

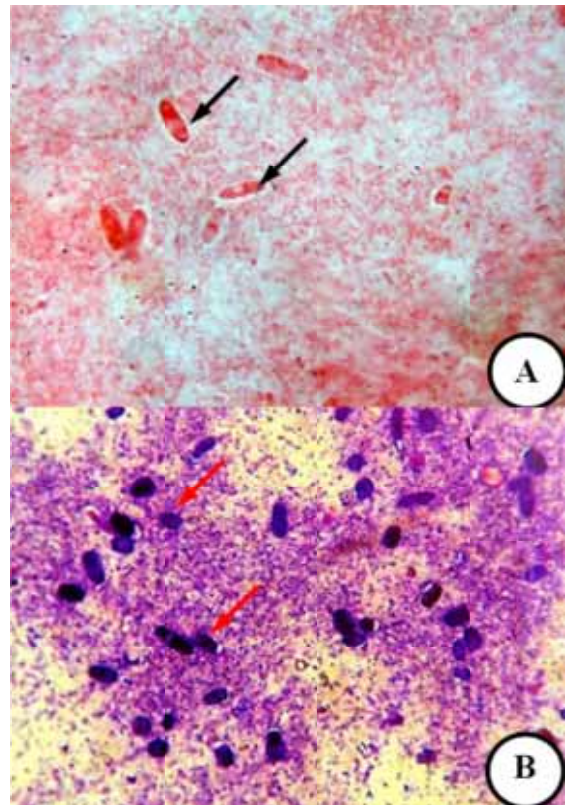


Figure 2: *E. intestinalis* spores in fecal specimen from cattle with spontaneous microsporidiosis (arrows). [A] Modified chromotrope Webergreen stain, [B] hot Gram chromotrope stain. X1000.

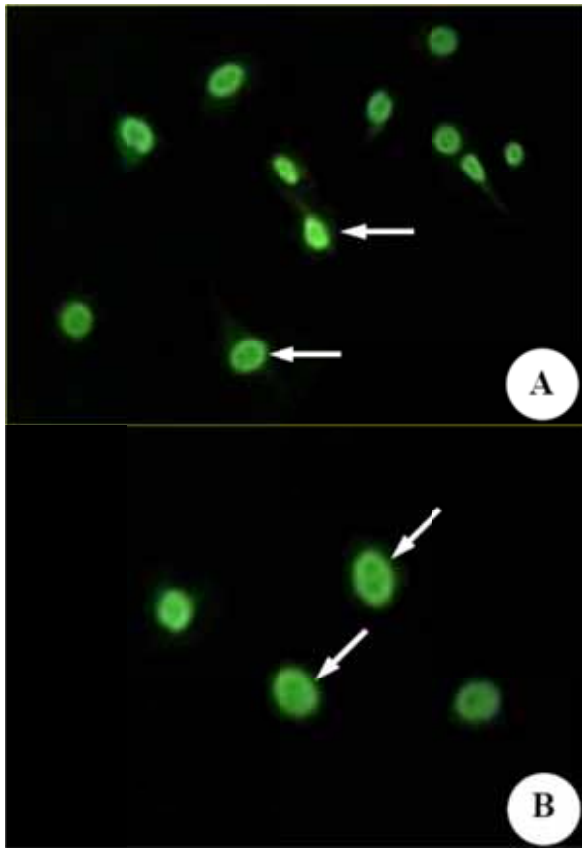


Figure 3: [A] *E. cuniculi* spores from fecal specimen from rabbit with spontaneous microsporidiosis (arrows). [B] *E. intestinalis* spores from fecal specimen from cattle with spontaneous microsporidiosis (arrows). Indirect Immuno Fluorescent Antibody technique, X1000.

Histopathological examination

The result of histopathological examination of naturally infected rabbits by *E. cuniculi* showed gross lesions consisting of congestion of liver, with area of hemorrhage in lungs, with the presence of white nodules of different size and shape (Figure 4).

Microscopically, in brain the lesions consist of perivascular cuffing of inflammatory cells around the affected blood vessels (vasculitis) (Figure 5). Granuloma seen in the brain consisting of plasma cells, lymphocytes, macrophages with glial cell that accumulated as response to tissue injury produced by spores (Figure 6).

In kidney the main histopathological lesions is interstitial nephritis that consist from macrophages and lymphocytes that separated between the renal tubule and in the interstitial tissue of kidney (Figure 7) which can be described as chronic interstitial nephritis.

Liver section showed vacuolar degeneration with heavy infiltration of macrophages, lymphocytes and increase in

Kuffer cells number around the central vein (Figure 8), with present of non suppurative inflammation in portal area represented also by present of macrophages and lymphocytes with cholangitis (Figure 9).

Lung sections showed thickening of small blood vessels and narrowing of their lumen with heavy infiltration of macrophages and lymphocytes in the interstitial tissue between alveoli (Figure 10).

The intestine section showed parasitophorusvacuoles of *E. cuniculi* in the tips of villi with the cytoplasm of enterocytes (Figure 11), with blunted villi and thickening of mucosal layer (Figure 12), with infiltration of inflammatory cells epically macrophages and lymphocytes in all layers of intestine, with hyperplasia of lymphoid tissue (Figure 13).

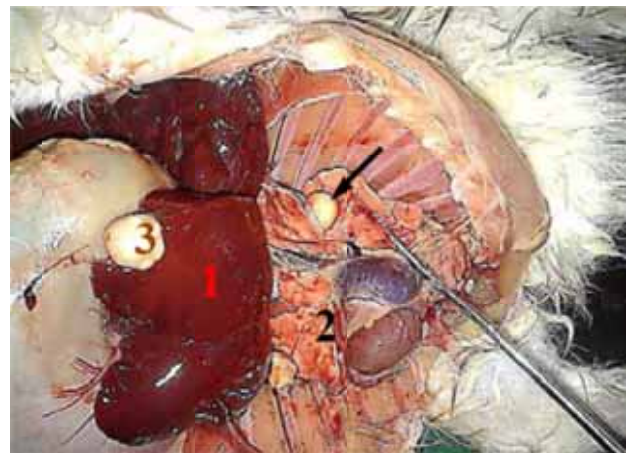


Figure 4: Gross view of rabbit abdomen showed congestion of liver (1), with area of hemorrhage in lung (2), with presence of white nodules with different size and shape in liver (3) and lung (arrow).

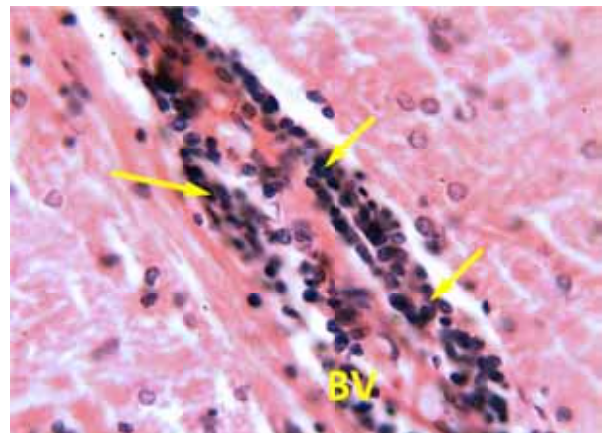


Figure 5: Section of rabbit brain with natural *E. cuniculi* infection showed perivascular cuffing (arrows) of blood vessels (BV). H&E stain, X400.

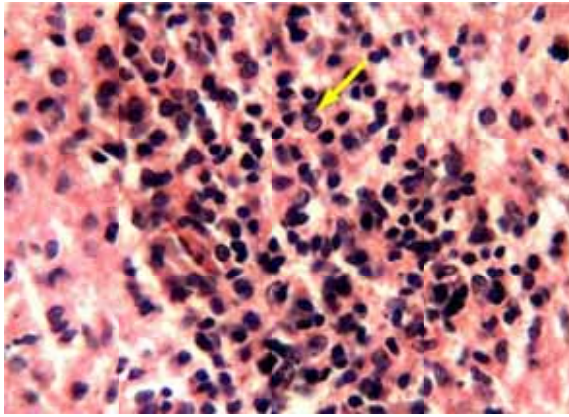


Figure 6: Section of rabbit brain with natural *E. cuniculi* infection showing infiltration of lymphocytes (arrow), plasma cells and glial cells. H&E stain, X400.

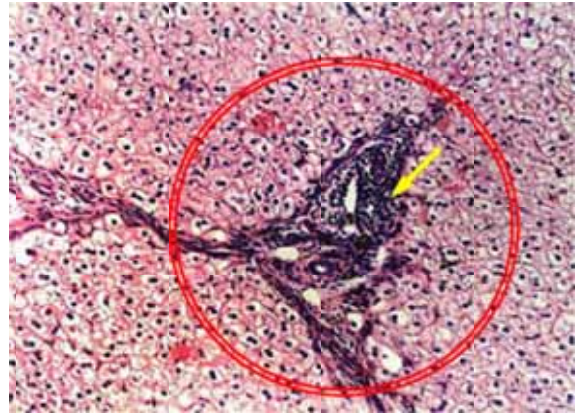


Figure 9: Section of rabbit liver with natural *E. cuniculi* infection showed non – suppurative portal infiltration (circle) and heavy infiltration of mononuclear cells (arrow) around blood vessels in the portal area. H&E stain, X100.

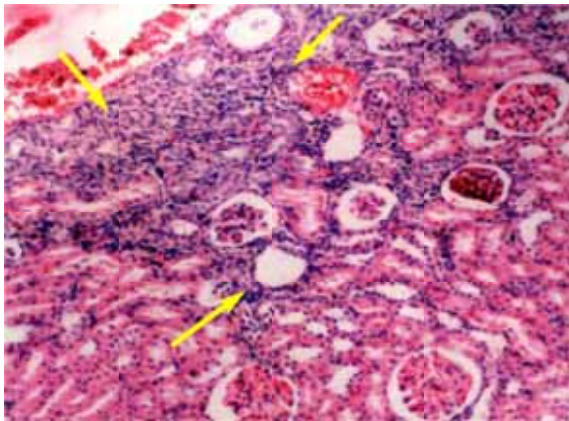


Figure 7: Section of rabbit kidney with natural *E. cuniculi* infection showed chronic interstitial nephritis (arrows). H&E stain, X100.

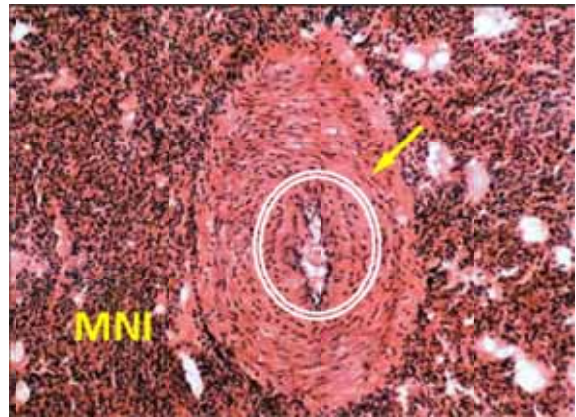


Figure 10: Section of rabbit lung with natural *E. cuniculi* infection showing thickening of the small blood vessels (arrow) and narrowing of lumen (circle) with infiltration of mononuclear (MNI) cell between alveoli. H&E stain, X100.

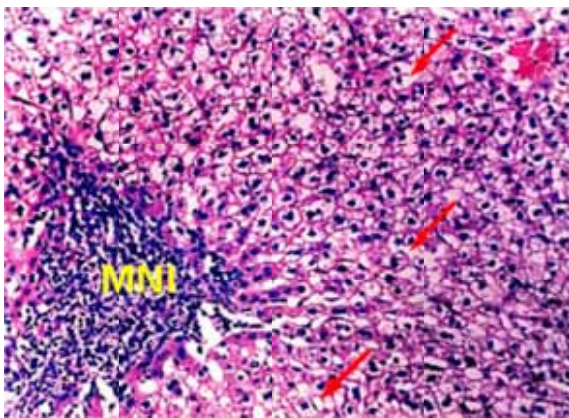


Figure 8: Section of rabbit liver with natural *E. cuniculi* infection showed vacuolar degeneration (arrows) and heavy infiltration of mononuclear cells (MNI). H&E stain, X100.

Discusson

In present study, fecal samples from rabbits and cattle have been collected from Mosul city, in order to identifying presence of microsporidiosis, with emphasis on pathology of natural infection with *E.cuniculi* in rabbits. In Iraq there were no previous studies on microsporidiosis in both human and animals. This paper considered the first one to identify present of both *E. cuniculi* in rabbits and *E. intestinalis* in cattle, and pathology of natural infected rabbits by *E. cuniculi* in Mosul city/ Iraq.

The result of current study reveals that microsporidiosis is common in Mosul city/Iraq, as seen in other countries in region as in Turkey 23%, Iran 21%, Saudi Arabia 10%, and Egypt 12% (31). The highest prevalence of

microsporidiosis was reported in rabbit 27.0%, which agreed with other studies that indicated the highest prevalence of natural infection with microsporidiosis in rabbits (20-22).

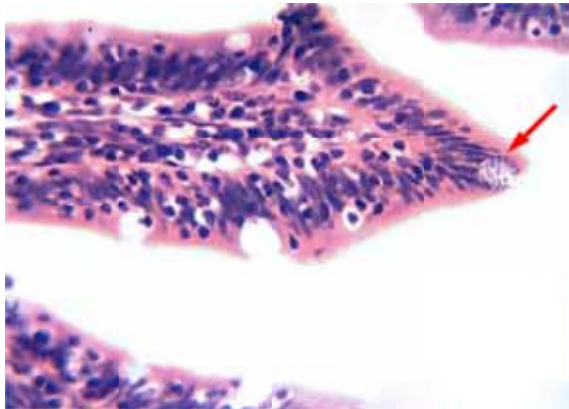


Figure 11: Section of rabbit intestine with natural *E. cuniculi* infection showed presence of parasites within enterocytes mainly at the tips of the villi (arrow). H&E stain, X400.

The result of current study showed that the prevalence of *E. cuniculi* was 73.2%, which agreed by many other reports has been reported the highest prevalence of *E. cuniculi* in rabbits as in Taiwan 67.8% (23), in Czech 68% (24), in United State 61.1% (25), in Italy 67.5% (26), in Japan 63.5% (27) in Austria 70.8 (28). All these high result come from the sensitive technique that used to identified presence of *E. cuniculi* in the fecal samples by using either nested polymerase chain reaction or enzyme linked immunosorbent assay (23,27,28). In addition to that indirect immunofluorescence antibody technique that used by current study, which considered a highly sensitive method that can detected a few number of spores in fecal samples (17).

The result of this study showed that the prevalence of microsporidiosis in cattle was 10.4% and *E. intestinalis* was 58.3%, these result agreed (29) which showed that the prevalence of microsporidiosis was 14.3% in adult and infant cattle, also agreed with other studies that indicated the most common pathogenic microsporidia in cattle is *E. intestinalis* (7,30). Microsporidia has don't exhibited a host specific properties, however all studies agreed with this study, in which the most common microsporidian species in cattle was *E. intestinalis* (31), which can't be explained furthermore (29).

The results of histopathology of naturally infected rabbits by *E. cuniculi* agreed with other studies that described the natural infection in wild and domesticated rabbits infected with *E. cuniculi* (32-34).

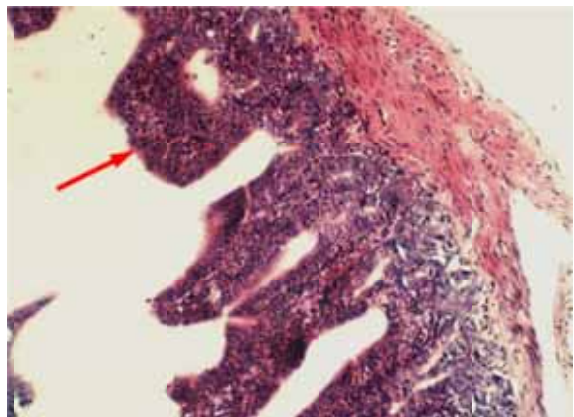


Figure 12: Section of rabbit intestine with natural *E. cuniculi* infection showed included blunt villi (arrow) with thickening of the mucosa. H&E stain, X100.

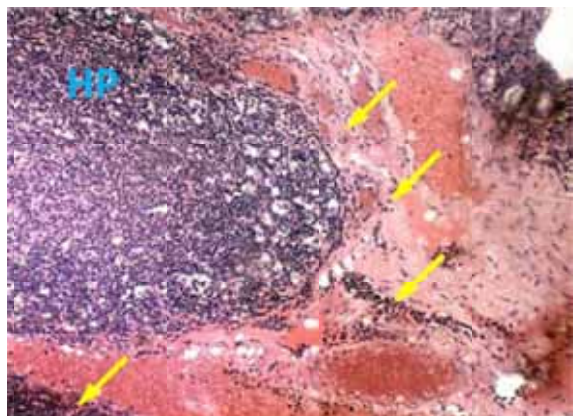


Figure 13: Section of rabbit intestine with natural *E. cuniculi* infection showed infiltrations of inflammatory mononuclear cells in submucosa (arrows), lamina propria and serosa, with hyperplasia of lymphoid tissues (HP). H&E stain, X100.

Lesions are mostly found in brain and internal organs and (35) described that due to the glycans molecules which is type of receptors found on cell surface preferred by microsporidial spores that attached by lecting part present on polar tube of spores to the glycans molecules (35), also the pH, oxygen supplies and metabolism rate play a role in present of these lesions, in which these microorganisms preferred the neutral pH (7-7.2), highly oxygenated tissue with high metabolic rate to be stabilized and produced their life cycle (36).

This wide spread of lesions in the body is due to the infection of macrophages which dissemination the organisms to other location as mentioned by (37). Majority of infiltrated cells in the lesion were mononuclear type cells which come to the area in response to IL-6 and IL-12

produced by injured tissue from the replication of spores as mentioned by (38).

In conclusion, the result of current study showed that natural microsporidiosis is very common in both rabbits and cattle, also natural infection by *E. cuniculi* was more common in rabbits and *E. intestinalis* was mostly reported in cattle in Iraq. In addition to that pathology caused by natural infection with *E. cuniculi* in rabbits in Iraq was typically similar to pathology caused by same pathogens all over the world.

Acknowledgement

This study were have been supported by College of Veterinary medicine, University of Mosul. This article is part of PhD research by the first author and supervised by second author.

References

1. Capella-Gutierrez S, Marcet-Houben M, Gabaldon T. Phylogenomics supports microsporidia as the earliest diverging clade of sequenced fungi. *BMC Biolo.* 2012;10:47-59.
2. Lee SC, Corradi N, Doan S, Dietrich FS, Keeling PJ, Heitman J. Evolution of the sex – related locus and genomic features shared in microsporidia and fungi. *PLOS ONE.* 2010;5(5):10-17.
3. Thomarat F, Vivares CP, Gouy M. Phylogenetic analysis of the complete genome sequence of *Encephalitozoon cuniculi* supports the fungal origin of microsporidia and reveals a high frequency of fast – evolving genes. *J Mol Evol.* 2004;59:780-791.
4. Keeling PJ, Slamovits CH. Simplicity and complexity of microsporidian genomes. *Eukaryotic Cell.* 2004;3(6):1363-1369.
5. Fischer JL. Chemotactic and inflammatory response to and recognition of *Encephalitozoon* spp. of microsporidia. PhD thesis. Faculty of the Louisiana State University and Agricultural and Mechanical Collage, 2008.
6. Anane S, Attouchi H. Microsporidiosis: epidemiology clinical data and therapy. *Gasstroenterologie Clinique Biologique.* 2010;34:450-464.
7. Malcekova B, Halanova M, Sulinoval Z, Molnar L, Ravaszova P, Adam J, Halan M, Valocky I, Baranovic M. Seroprevalence of antibodies to *Encephalitozoon cuniculi* and *Encephalitozoon intestinalis* in humans and animals. *Res Vet Sci.* 2010;89:358-361.
8. Matos O, Lobo ML, Teles A, Antunes F. Is microsporidial infection in animals a potential source for human microsporidiosis? *Southeast Asia J Trop Med Public Health.* 2004;35(Suppl. 1):48-53.
9. Ozkan O, Ozkan AT, Zafer K. *Encephalitozoonosis* in New Zealand rabbits and potential of transmission risk. *Vet Parasitol.* 2011;179:234-237.
10. Didier ES. Microsporidiosis: and emerging and opportunistic infection in humans and animals. *Acta Tropica.* 2005;94:61-76.
11. Garcia LS. *Clinical microbiology procedures handbook.* 2nd ed. California: LSG & Associates, 2007.
12. Garcia LS. Laboratory identification of the microsporidia. *J Clin Microbiol.* 2002;40(6):1982-1901.
13. Weber R, Bryan RT, Qwen RL, Wilcox CM, Gorelkin L, Visvesvara GS. Improved light – microscopical detection of microsporidia spores in stool and duodenal aspirates. *N Engl J Med.* 2002;326(3):161-166.
14. Ryan NJ, Sutherland G, Coughlan K, Globan M, Doultree J, Marshall J, Baird RW, Pedersen J, Dwyer B. A new trichrome – blue stain for detection of microsporidial species in urine stool and nasopharyngeal specimens. *J Clin Microbio.* 2003;31:3264-3269.
15. Suvarna SK, Layton C, Bancroft JD. *Bancroft's theory and practice of histological techniques.* 7th ed. New York: Churchill Livingstone Press, 2013.
16. Reabel S. *Molecular diagnostic methods for detection of Encephalitozoon cuniculi in pet rabbits.* MSc thesis. University of Guelph, Guelph Ontario Canada, 2012.
17. Cisse OA, Ouattara A, Thellier M, Accoceberry I, Biligui S, Minta D, Doumbo O, Desportes-Livage I, Thera MA, Danis M, Darty A. Evaluation of an immunofluorescent-antibody test using monoclonal antibodies directed against *Enterocytozoon bienusi* and *Encephalitozoon intestinalis* for diagnosis of intestinal microsporidiosis in Bamako (Mali). *J Clin Microb.* 2002;40(1):1715-1718.
18. Cooney KA, Chappell JR, Calle RJ, Connally BA. *Veterinary euthanasia techniques: A practical guide.* 1st ed. California: A John Wiley & Sons Ltd. Publication Wiley- Blackwell Press, 2013.
19. Petrie A, Watson P. *Statistics for Veterinary and Animal Science.* 3rd ed. California: A John Wiley & Sons Ltd. Publication Wiley-Blackwell Press, 2013.
20. Kunzel F, Joachim A. *Encephalitozoonosis* in rabbits. *Parasitol Res.* 2010;106:299-309.
21. Harcourt - Brown FM, Holloway HKR. *Encephalitozoon cuniculi* in pet rabbits. *Vet Rec.* 2003;152:427-431.
22. Ebrecht DR, Mueller E. Zoonosis of microsporidia in rabbit. *TierärztlPrax.* 2004;32(K):363-369.
23. Tee YC, Kao JP, Chiu HY, Chang MH, Wang TH, Tung KC, Cheng FP, Wu JT. Serological survey for antibodies to *Encephalitozoon cuniculi* in rabbits in Taiwan. *Vet Parasitol.* 2011;183:68-71.
24. Jeklova E, Jekl V, Kovarcik K, Hauptman K, Koudela B, Neumayerova H, Knotek Z, Faldyna M. Usefulness of detection of specific IgM and IgG antibodies for diagnosis of clinical encephalitozoonosis in pet rabbits. *Vet Parasitol.* 2010;170:143-148.
25. Cray C, Rodriguez M, Fernandez Y. Acute phase protein levels in rabbits with suspected *Encephalitozoon cuniculi* infection. *J Exotic Pet Med.* 2013;22:280-286.
26. Dipineto L, Rinaldi L, Santaniello A, Sensale M, Cuomo A, Calabria M, Menna LF, Fioretti A. Serological survey for antibodies to *Encephalitozoon cuniculi* in pet rabbits in Italy. *Zoo Public Heal.* 2008;55:173-175.
27. Igarashi M, Oohashi E, Dautu G, Ueno A, Kariya T, Furuya K. High seroprevalence of *Encephalitozoon cuniculi* in pet rabbits in Japan. *J Vet Med Sci.* 2008;70:1301-1304.
28. Kunzel F, Gruber A, Tichy A, Edelhofer R, Nell B, Hassan J, Leschnik M, Thalhammer JG, Joachim A. Clinical symptoms and diagnosis of *Encephalitozoonosis* in pet rabbits. *Vet Parasitol.* 2008;51:115-124.
29. Del Coco VF, Cordoba MA, Bilbao G, De Almeida T. First report of *Encephalitozoon intestinalis* from cattle in Argentina. *Vet Parasitol.* 2014;2(6):34-38.
30. Lix X, Fayer R. Infectivity of microsporidian spores exposed to temperature extremes and chemical disinfectants. *J Eukaryotic Microbiol.* 2006;53:77-79.
31. Mathis A, Weber R, Deplazes P. Zoonotic potential of the microsporidia. *Clin Microbiol Rev.* 2005;18(3):423-445.
32. Mancinelli E. *Encephalitozoon cuniculi* infection in domestic rabbits. *Great Western Exotic Veterinarians.* 2011;11(11):23-31.
33. Csokai J, Gruber A, Kunzel F, Tichy A, Joachim A. *Encephalitozoonosis* in pet rabbits (*Oryctolagus cuniculus*): pathohistological findings in animals with latent infection versus clinical manifestation. *Parasitol Res.* 2009;104:629-635.
34. Wasson K, Peper RL. Mammalian microsporidiosis. *Vet Pathol.* 2000;37:113-128.
35. Xu Y, Weiss LM. The microsporidian polar tube: a highly specialized invasion organelle. *Int J Parasitol.* 2005;35(9):941-953.
36. Fasshauer V, Gross U, Bohne W. The parasitophorous vacuole membrane of *Encephalitozoon cuniculi* lacks host cell membrane

- proteins immediately after invasion. *Eukaryotic Cell*. 2005;4(1):221-224.
37. Khan IA, Moretto M, Weiss LM. Immune response to *Encephalitozoon cuniculi* infection. *Microbes Infect*. 2001;3(5):401-405.
38. Williams BAP. Unique Physiology of host – parasite interactions in microsporidia infections. *Cell Microbiol*. 2009;11(11):1551-1560.