

Effect of rosella extract on development of fatty streaks lesions in female rats

E. R. Al-Kennany* and A. I. Al-Khafaf**

*Department of Pathology, College of Veterinary Medicine, ** Department of Biology, College of Education for Girls, University of Mosul, Mosul, Iraq

Email: *er.al-kennany@yahoo.com, ** asrar.iraq@yahoo.com

(Received June 18, 2008; Accepted January 17, 2010)

Abstract

This research was conducted to explore the effect of rosella (*Hibiscus sabdariffa*) on female rats on oxidative stress which induced by 0.5% H₂O₂. Oxidative stress has been investigated via tissue (aorta and heart) malonadyaldehyde (MDA) as indirect lipid peroxidation index. For atherosclerotic lesions follow up light microscopical technique has been applied. The result elucidate significant reduction in lipid profit parameters namely: low density lipoprotein (LDL-c), triglycerides, very low density lipoprotein (vLDL-c), atherogenic index and significant elevation in high density lipoprotein (HDL-c) in few animals treated with H₂O₂ and rosella extract, parallely, this research illustrate reduction in aorta and heart MDA concentration, concomitant with significant rising in glutathione (GSH) level. Histopathologically, this study revealed fatty streaks associated with infiltration of mononuclear inflammatory cells have been detected after 60 days, in animal treated with rosella revealed reduction in lipid vacuoles and proliferation in vascular smooth muscle cells (VSMCs) in media toward intimal layers after 40 days from treatment.

Keywords: Rosella extract; Fatty streaks lesion; Rat.
Available online at <http://www.vetmedmosul.org/ijvs>

**

*

**

*

(*sabdariffa Hibiscus*)

(vLDL-c)

HDL-c

(LDL-c)

% ,
malonadyaldehyde

Introduction

Atherosclerotic lesion can developed by oxidized low density lipoprotein (ox-LDL-c) (1). Multiple biological properties including stimulation of monocyte adhesion (2) enhanced cytotoxicity (3), uptake of oxidized LDL-c by macrophage scavengers receptors leading to the formation of foam cells (4) and altered expression of cytokines and growth factors (5,6). The development of atherosclerotic lesions in hyperlipidemia and H₂O₂ in rabbit, rats, chickens (7-9) can be reduced by antioxidants such as probucol, BHT, vitamin E, C, garlic (7,10).

Recent research has focused on plants contain falvonoids, aseparate group of dietary antioxidants. One recent study showed that red tea (Rosselle) consumption was associated with a reduction of LDL-c oxidation (11). Roselle (*Hibiscus sabdariffa* Linn.) is considered to be available natural substance, the calyx of which has been reported to contain many phyto constituents such as plant acids (hibiscus acid), phytosterol, flavone derivatives ascorbic acid and soluble fibers.

Thus, it has been reported to have a variety of biological affects including diuresis, antihypertension and hypocholesterolemia (12-14).

Antioxidant effect of roselle extracts have been investigated in many experimental modules (15) however, the antioxidant effect of *Hibiscus sabdariffa* linn. on oxidation of LDL-c have been studied. The present study was designed to investigate the roselle effect as antioxidant and antiatherogenic induced by H₂O₂ in female rats.

Materials and methods

Female albino rats (20) weighting between 300-350mg of 3-4 months old were used. The animals were kept in wire cages fed on standard diet and given tap water *ad Libitum*, and housed in a constant temperature (22-25C) environment with 12h. light and 12h. dark cycle. Animals were divided into four group of five rats each. Group 1 received regular rat diet and maintained as a control group; group II rats subjected to experimentally induced oxidative stress by the *ad Libitum* supply of drinking water containing 0.5% H₂O₂ (V/V) [Degussa AG merl Rheinfelden, Belgium] was prepared daily over entire 60 days period of the experiment (60 days), after the end of 60 days of H₂O₂ treatment five animals were selected randomly to serve as the rosella treated group (group III), animal of this group received Rosella (from local market) aqueous extract for 40 days, which prepared according to (11). Group IV received only the regular rat diet and subjected Rosella (red) tea of drinking (2 cups) was prepared daily.

At the end of the experiment period, rats were bled, and plasma samples were analysed after collection of blood samples after an overnight fast for 12-14h. and analysis

performed in fresh heparin-treated plasma. The lipid parameters Tch, TGs, LDL-c, vLDL-c were determined by using a standard enzymatic assay (Bio Mericuk-Marcy-I'Eroile France), wherese LDL-c was calculated by the Friedewald formula:

$$\text{LDL-c} = \text{HDL-c} - \text{TGs}/5$$

Piece of aorta and heart tissue were removed for estimation of MDA by thiobarbituric acid (TBA) test as previously described by (16). GSH concentration of aorta and heart was measured according to (17).

For histopathological study, rats killed by anesthesia, aorta were dissected from the arch to the bifurcation, rinsed with isotonic saline and opened along the intercostal. The opened aortas were flattened on strips of paper with the intimal side up, after adherence to the paper strips, the vessels were fixed face down over night with 10% buffered formation at room temperature.

Fixed aortas were stained with sudan IV as previously described (9) to visualize areas of atherosclerotic plaque.

After fixation of aorta and heart, tissue blocks were routinely embedded in paraffin, and 5-6 sections were cut. Histological sections were stained with haematoxylin and eosin (H and E) (18).

Statistical analysis

Differences among control and treated group were tested using ANOVA followed by Tukey's test. Differences of P<0.05 were considered significant.

Results

Table (1) illustrates the effect of H₂O₂ and/or supplemented red tea on plasma lipid profile parameters. In comparison with control group in group treated with 0.5% H₂O₂ revealed significantly increased Tch, TGs, LDL-c, vLDL-c, and decreased HDL-c. In rats subjected to H₂O₂ and supplemented with Rossela, the lipid profiles indicate a decrease of Tch (157.01±0.21) TGs (44.36±0.21), LDL-c (15.43±0.22), vLDL-c (86.82±0.42) and increases the level of HDL-c (61.36±0.22) as compared with group treated with H₂O₂ only. With drinking red tea, the picture of lipid profiles show an increase in HDL-c and decrease in level of Tch. and LDL-c as compared with control group.

Tissue MDA and GSH level

Tissue (aorta and heart) TBA reactive substances, MDA were significantly increased in rats treated with H₂O₂ as compares with control group (Table 2). Red tea treated resulted significant reduction of lipid peroxidation product induced by H₂O₂. Red tea supplementation kept value of MDA in aorta with in the normal limit, while induced reduction in the heart.

Table (2) also showed tissue (aorta and heart) significant decreased after 60 days of H₂O₂ treatment significant decreased as compared with control group. Red tea supplementation in combination with H₂O₂ showed reduction level of GSH in aorta and heart, while red tea alone kept the aortic GSH with in the normal limits. It induced significant increase in heart GSH as compared with control group.

Pathological lesions

Aortic intimal fatty steaks were detected only after sudan staining and appear as flat or very slightly elevated intimal streaks and spots demarcated sudanophilia. Supplementation of red tea with H₂O₂ treatment showed reduction in fatty streaks that detected in sudan stains.

On microscopical appearance, aortic lesions were seen in group treated with H₂O₂ represented by intimal thickening was seen due to proliferation of collagen, elastin,

spindle-shaped cells and foamy cells (Fig. 1 and 2). The intimal elastic lamellae was fragmented and split into several layers. While in aorta of rats treated with Rosella there was reduction in lipid vacuoles associated with hypertrophy and degeneration in VSMCs concomitant with infiltration of mononuclear inflammatory cells as compared with aortas of rats treated with red tea only, which have no lesion shown (Fig. 3).

Heart

Histological section of heart revealed fatty change edema and hyalinization of myocardial muscle fibers associated with infiltration of inflammatory cells, mainly lymphocytes in rat treated with 0.5% H₂O₂ (Fig. 4).

Moreover, rats treated with red tea and H₂O₂ showed fatty change, edema, concomitant with infiltration of mononuclear inflammatory cells, enlarged of myocytes (Fig. 5).

Table 1: Effect of oral H₂O₂ (0.5%), drinking supplementation with roselle (*Hibiscus sabdariffa*) on lipid parameters of female rats.

Groups	Tch mg/ml	TGs mg/ml	HDL-c	LDL-c	vLDL-c	Atherogenic index
Control	93.62±0.11	60.90±0.21	60.66±2.1	20.78±0.5	12.18±0.5	1.003±
H ₂ O ₂	196.68±0.22	72.81±8.01	52.76±0.42	88.44±0.32	129.36±0.51	3.72±0.21
Roselle treated	90.24±0.21	58.18±0.25	68.18±.25	12.50±0.12	91.55±0.13	1.32±0.15
H ₂ O ₂ +roselle	157.01±0.21	44.36±0.21	61.36±0.22	15.43±0.61	86.82±0.42	2.56±0.22

Value are expressed as means. ± S.D. 5 rats per groups, Tch = Total cholesterol, TGs = Triglycerd. Mean with the same superscript in the same column are not significantly different from other (P<0.05).

Table (2): Effect of oral H₂O₂ (0.75), drinking supplementation rosella (*Hibiscus sabdariffa*) on tissue MDA.

Groups	MDA		GSH	
	Aorta	Heart	Aorta	Heart
Control				
H ₂ O ₂ -treated	383.11±1.63	442.21±7.72	2.87±0.13	1.75±0.01
Roselle-treated	558.3±8.61	721.21±2.11	1.03±1.22	1.02±0.03
H ₂ O ₂ +rosella treated	398.67±1.81	635.22±7.21	2.23±0.56	1.62±0.05

Values are expressed as means ± S.D. of 5 rats per group. Means with same superscript in the same column are not significantly different from others (P<0.05).

Discussion

Oral administration of H₂O₂ to rats for 60 days induced oxidant stress. Moreover, this oxidative stress was accompanied with initiation of atherosclerotic lesion in aorta on gross and light microscope. This result is a greeted with that reported previously by (9,7,19). It has been suggested that oxidative stress produced by injury of the vascular endothelium at early event in the pathogenesis of atherosclerosis.

The results of this experiment revealed that incidence of lipid profile were significantly increased represented by Tch, TGs, LDL-c, vLDL-c and atherogenic index, inparallel

to significant decrease in the level of HDL-c in group treated with H₂O₂, this indicated that H₂O₂ is regardant as one of the reactive oxygen species which has direct effect on the level of plasma chol., TGs and atherogenic lipoproteins. These results suggest that may be due to the fact that there was a dynamic alteration in the process of absorption and exertion of steroid or there was reduction in bowel bile salts. Our results were in agreement with previous studies (7,8,10).

Results in group III (supplementation with Rosella) revealed a significant decrease in Tch., TGs, LDL-c, vLDL-c level as well as atherogenic index, accompanied by a significant increase in HDL-c level as compared with group

II. These results might be due to the fact that Rosella is considered as antioxidants which prevents oxidative modification of LDL-c, through suppression of reactive oxygen species by its content such as flavonoids, poly phenols, Aspartic acid is the most amino acid and vitamin C (20), this findings was in according with that reported by (21).

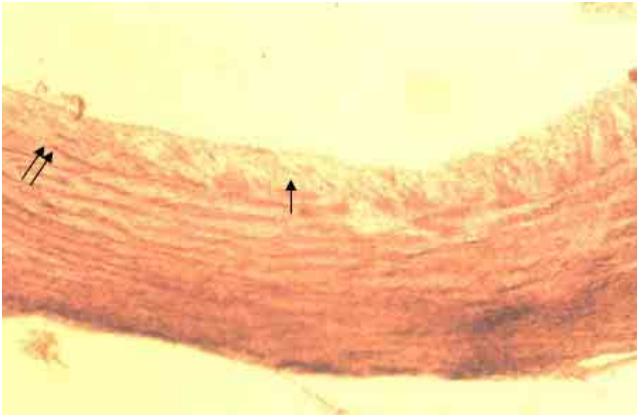


Fig.1: Photomicrograph of thoracic aorta of female rat 60 day, post treatment with 0.5% H₂O₂, Note deposition of lipid vacuole in internal layer (→) and fragmentation of elastic lamellae (⇨) H & E. 400X.

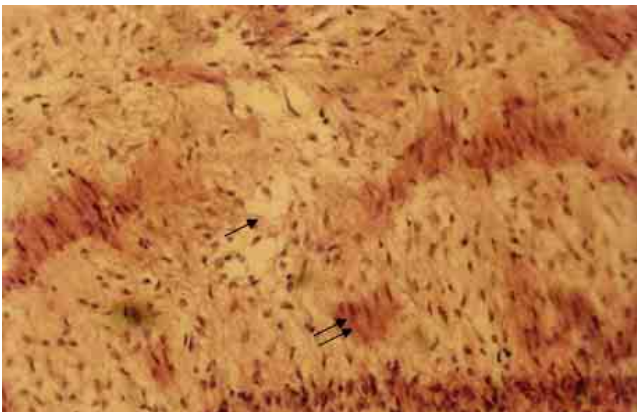


Fig.2: Photomicrograph of thoracic aorta of female rate 60 days post treatment with H₂O₂ 0.5%, revealed foam cells (→), hypertrophy of VSMCs in media layer (⇨), H & E. 400X.

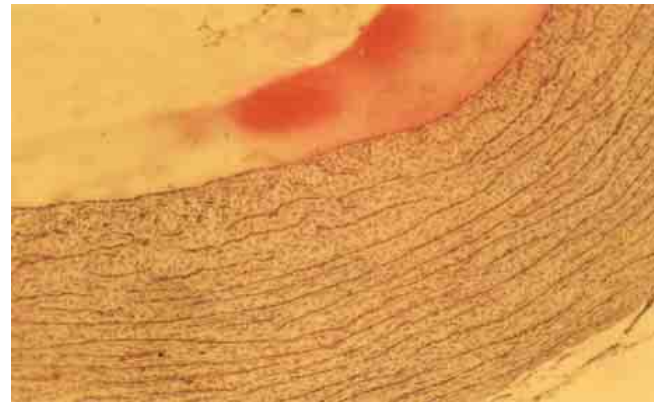


Fig.3: Photomicrograph of thoracic aorta of female rat 40 days post Rosella treatment. Note there were no significant lesions. H&E. 400X.

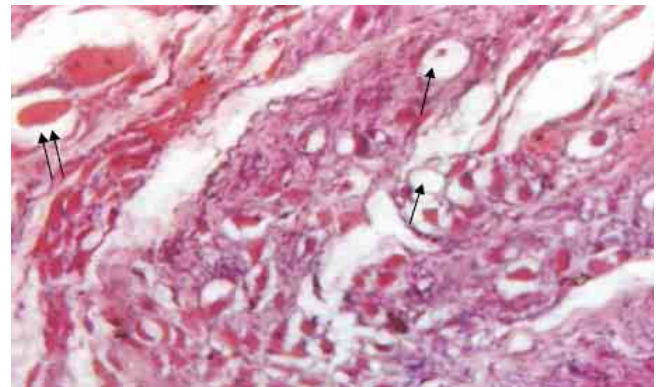


Fig.4: Photomicrograph of female rat heart 40 days post treatment with 0.5% H₂O₂ revealed sever fatty change (→) edema associated with congestion of coronary artery (⇨). H&E. 400X.

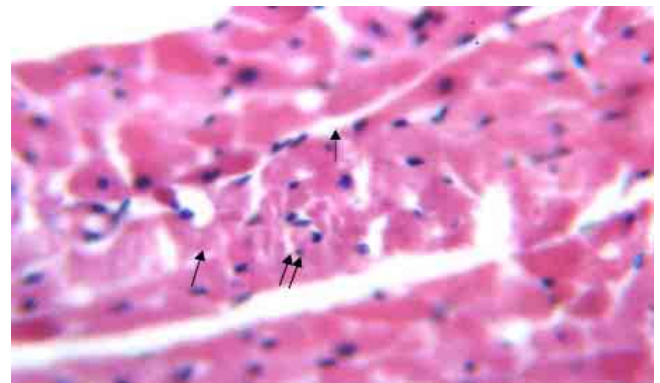


Fig. 5: Photomicrograph heart of female rat treated with 0.5% H₂O₂ and roselle revealed fatty change (→), infiltration of mononuclear inflammatory cells between muscle bundles and edema (⇨). H & E. 200X.

This study showed that Rosella supplementation exerted a significant effect on lipid peroxidation and antioxidant status. However, there was a significant protective effect of Rosella as an antioxidant against H₂O₂-induced atherosclerosis occurs with reduction in MDA and increase level in HDL-c and GSH. Thus, the protective effect of Rosella, also was noticed in histopathological changes, this effect may be commons due to content of vitamin C which have ability to break chain of ROS. According to Hassan *et.al*, (10) that vit. C is a protective enough to effecting intercept oxidants in the aqueous phase before they can attack and cause detectable oxidative damage to lipid as compared to other lipophilic and hydrophilic antioxidant.

Results of histopathological changes in aorta and heart that appear in Figures (1-7) may agreed to injury that occurs in the endothelium of aorta due to action of oxidative stress which is considered as an indication for injury and endothelial dysfunction. In addition, oxidative stress stimulates the generation of growth factors and active vascular substances represented by NO which activated endothelial vascular lesion that enhance mitogenic events and VSMC, proliferation (22).

In general histopathological lesion in rats treated with Rosella reveals reduction in lipid vacuoles in intima and media and increase proliferation of vsmcs, this findings were similar to the results of vit. E (23) due to the fact that Rosella can inhibit the production of ROS and prevent oxidation of LDL-c (11) who speculated the antioxidant effect of Rosella in the protection of LDL-c from oxidative modification in vitro may result from either protocatechi acid or other polyphenolic components in the roselle.

References

- Steinberg D, Parthasarathy S, Carew TE, Khoo JC, Witztum JL. Beyond cholesterol: modifications of low density lipoprotein that increase its atherogenicity. *N Engl J Med*. 1989;320:916-924.
- Berliner JA, Territo MC, Sevianan A, Romin S, Kim JA, Bamshad B, Esterson M, Fogelman AM. Minimally modified LDL stimulates monocyte endothelial interactions. *J Clin Invest*. 1990;85:1260-1266.
- Morel DW, Hessler JR, Chisolm GM. Low density lipoprotein cytotoxicity induced by free radical peroxidation of lipid. *J Lipid Res*. 1983;24:1070-1076.
- Heinecke JW, Baker L, Rosen H, Chait A. Superoxide mediated free radical modification of low density lipoprotein by arterial smooth muscle cells. *J Clin Invest*. 1986;77:757-761.
- Hamilton TA, Ma GP, Chisolm GM. Oxidized low density lipoprotein suppresses the expression of tumor necrosis factor- α mRNA in stimulated murine peritoneal macrophages. *J Immunol*. 1990;144:2343-2350.
- Malden LT, Chait A, Raines EW, Ross R. The influence of oxidatively modified lipoprotein on expression of platelet-derived growth factor by human monocyte-derived macrophages. *J Biol Chem*. 1999;274:13901-13907.
- Al-Kennany ER and Al-Khafaf AI, Role of oxidative stress induced by hydrogen peroxide on initiation and development of atherosclerosis in mature femal rat. *Iraqi J Vet Sci*. 2006;20 (1):139-151.
- Al-Kennany ER and Al-Allaf Esh, The capability of oxidative stress to induce atherosclerosis lesions in Rabbits. *Iraq J. of Vet. Sci*. 2005;19:179-192.
- Al-Kennany ER. A study on the capability of oxidative stress by hydrogen peroxide to induce atheromatous lesions experimentally in chickens. Ph.D. College of Veterinary Medicine, University of Mosul, Mosul, Iraq, 1998.
- Hassan SM, AL-Kennany ER, Al-Hafez HAK. Hydrogen peroxide-induced atherosclerosis in chickens: Effect of vitamin C. *Iraqi, J. Vet*. 2000;3:249-270.
- Vilasinee H, Anocha U, Noppawan PM, Nuntavan B, Hitoshi S, Angkana H, Chuthamane S. Antioxidant effects of aqueous extracts from dried calyx of *Hibiscus sabdariffa* LINN. (Roselle) in vitro using rat low-density lipoprotein (LDL). *Biol Phar*. 2005;28 (3):481-484.
- Wang CJ, Wang JM, Lin WL, protective effect of *Hibiscus anthocyanins* against tert-butyl hydroperoxid-induced hepatic toxicity in rats *Food. Chem Toxicology*. 2000;38:411-6.
- Chen CC, Hsc JD, Wang SF, Chiang HC, Yang MY, Ho YC, Wang CJ. *Hibiscus sabdariffa* extract inhibits the development of atherosclerosis in cholesterol-feed rabbits. *J Agric Food Chem*. 2003;51:5472-7.
- Hirunpanich V, Utaipat A, Morales NP, Buryapraphatsara N, Sato H, Herunsalce A, Suthisisuny C. Antioxidant effects of aqueous extract from dried calyx of *Hibiscus sabdariffa* Linn. (Rosella) in vitro using rat low density lipoprotein (LDL). *Biol Pharm-Bull*. 2005;28:481-4.
- 15-Amin A, Hamza AA, Hepatoprotective effect of *Hibiscus, Rosmarinus* and *Salvia* on a zathoio prove induced toxicity in rats. *Life Sci*. 2005;77:266-78.
- Gillbert Stump DD, Roth EF Jr. A method to correct for error caused by generation of interfering compounds during erythrocyte lipid peroxidation. *Anal Biochem*. 1989;137:282-286.
- Moron MS, Depierre JW, Mennerivk B. Levels of glutathione reductase and glutathione S-transferase activities in rats lung and liver. *Bioch Biophys Acta*. 1979;582:67-78.
- Drury R.A.B and Willington E.A. *Carlton's Histological Technique*. 5th ed., Oxford University Press. 1980; pp:129,167,178,206.
- Khudair KK. The role of aqueous extracts of Olive (*Olea europaca*) leaves and garlic (*Allium sativum*) in ameliorating the effects of experimentally induced atherosclerosis in rats. Ph.D Thesis, College of Veterinary Medicine, University of Baghdad, 2000.
- Kaung-Yuh C., Babbidge S.M., Zhao X., Dandillaya R., Retveld A.Q., Yano J., Dirrayuga P, Cercel B. and Shah P. Differential effects of green tea derived catechine on developing versus established atherosclerosis in apolipoprotein E-Null Mice., *Amer. Heart Associ.* 2004;109:2448-2453.
- Luo M, Kannar K, Wahlquist ML. Inhalation of LDL-oxidation by green tea extract. *Lancet*. 1997;349:360-361.
- Malden LT, Chait A., Raines EW and Ross R., The influence of oxidatively modified growth factor by human monocyte-derived macrophages. *J Biol Chem*. 1991;266:13901-13907.
- Partico D, Tangirata RK, Rader DJ. Vitamin E Suppresses iso prostane generation in vivo and reduces atherosclerosis in apo E-deficient mice. *Nat Med*. 1998;4:1189-192.