

Concurrent aflatoxicosis and caecal coccidiosis in broilers

A. M. Shareef

Department of Veterinary Public Health, College of Veterinary Medicine, University of Mosul, Mosul, Iraq

(Received January 27, 2008; Accepted July 13, 2009)

Abstract

A farm of two broiler flocks fed from one day old to 56 days of age a diet naturally contaminated with high level of Aflatoxin (AF), were suffered from caecal coccidiosis at 35 days of age Aflatoxin levels in feed commodities and mixed feed were determined using ELISA test. Results of ELISA showed that the average level of corn, soybean and mixed feeds contamination with aflatoxin were 1915, ppb, 229 ppb and 860 ppb respectively. Diagnosis of caecal coccidiosis was confirmed by clinical signs, post-mortem findings, fecal oocyst excretion per gram, oocyst size, morphological characteristic of eggs, lesion score and schizonts size. The significance of AF as predisposing factor to coccidiosis infection was discussed.

Keywords: Coccidiosis, Aflatoxin, Broilers.

Available online at <http://www.vetmedmosul.org/ijvs>

الحدوث المتلاقي للتسمم بالافلا وداء الاكريات في فروج اللحم

عقيل محمد شريف

فرع الصحة العامة البيطرية، كلية الطب البيطري، جامعة الموصل، الموصل، العراق

الخلاصة

مزرعة دواجن مؤلفه من قطيعين لفروج اللحم تمت تغذيتها من عمر يوم واحد ولغاية ٥٦ يوم عليه ملوثه طبيعياً بمستويات عاليه من سموم الافلا، عانت من الاصابه بداء الاكريات الاعوري بعمر ٣٥ يوم. تم قياس مستويات سموم الافلا في المكونات العلفيه والعليقه المركبة باستخدام تقنيه الممنتر المناعي المرتبط بالإنزيم والتي أوضحت ان معدل تلوث الذرة وفول الصويا والعلف المركب بسموم الافلا كانت ١٩١٥ و ٢٢٩ و ٨٦٠ جزء باللبليون على التوالي. تم تشخيص داء الاكريات الاعوري بالعلامات السريرية، والتشريح المرضي، طرح البيض البرازي لكل غرام، حجم البيوض، شكل البيوض تدرج الافات و حجم المفلوقات. نوقشت أهميه سموم الافلا كأحد الأسباب المهيئه للاصابه بداء الاكريات.

Introduction

Poultry aflatoxicosis was first reported when 100000 turkey poults in the United Kingdom in 1960 died following the ingestion of poultry feed containing Brazilian groundnut cake which led to the discovery of a group of compounds now called the aflatoxins (1). Soon afterwards, however, aflatoxicosis became a worldwide problem (2-4). Mycotoxins are secondary metabolites produced by fungi of various genera when they grow on agricultural products before or after harvest or during transportation or storage. Mycotoxins are regularly found in feed ingredients such as

maize, sorghum grain, barley, wheat, rice meal, cottonseed meal, groundnuts and other legumes. Most are relatively stable compounds and are not destroyed by processing of feed and may even be concentrated in screenings. Naturally occurring toxins present a different problems (5,6). Mycotoxins cannot be avoided entirely or eliminated from animal feeds because the molds that create them occur naturally in grains and other food commodities Aflatoxins B1, B2, G1, and G2 are mycotoxins that may be produced by three moulds of the *Aspergillus* species: *A. flavus*, *parasiticus* and *A. nomius* (7) Aflatoxin B1 is an immunosuppressive mycotoxin for cell-mediated immunity

(CMI), humoral immunity, suppression of peritoneal macrophage phagocytosis and the primary splenic antibody response (8-11). Aflatoxin has been reported to increase the severity of avian infectious diseases such as salmonellosis (12), crop mycosis (13), aspergillosis (14), and coccidiosis (15).

Avian coccidiosis is the major parasitic disease of poultry with a substantial economic burden on the cost the industry (16). In-feed medication for prevention and treatment contributes a major portion of these losses in addition to mortality, malabsorption, inefficient feed utilization and impaired growth rate in broilers, and a temporary reduction of egg production in layers. The pathogenicity of coccidia depends largely on the successful replication of developing parasites inside the host. Theoretical estimates indicate that a single oocyst of a virulent species such as *E. tenella* could yield 2,520,000 invasive parasites after the 2nd merogony stage (17). The profuse bleeding in the ceca is a characteristic feature of *E. tenella* infection due to its extensive destruction of the mucosa with histological lesions (18). In general, young animals are more susceptible to coccidiosis and more readily display signs of disease, whereas older chickens are relatively resistant to infection (19). Young animals which recover from coccidiosis may later be able to partly compensate for the loss of body growth, but their growth potential remains severely compromised. Because the life cycle of *Eimeria* parasites is complex and comprised of intracellular, extracellular, asexual, and sexual stages, host immune responses are quite diverse and complex. After invasion of the host intestine, *Eimeria* elicit both nonspecific and specific immune responses which involve many facets of cellular and humoral immunity (20,21) Caecal coccidiosis of broilers has been extensively studied (22), and as the world's poultry industry has developed the disease has continued to be of major economic importance (23). Interactions occur between chicken caecal coccidiosis and other diseases, caused by various pathogens (24). Among those other diseases, aflatoxin intercurrent with coccidiosis are an increasing health risk to poultry and poultry coccidiosis due to primary exposure to aflatoxin had been reported previously (25-30). A natural broiler aflatoxicosis or broiler caecal coccidiosis had been reported in Mosul province (4, 31).

The natural concurrence of these both cases in broilers is what we are tried to describe in a farm of two broiler flocks, in Mosul province, Iraq.

Materials and methods

Chicks and diet:

A broiler farm, in Al-Hamdanyea / Mosul province, reared on letter 8600 and 9650 broilers in two separate house, had been claimed at 35 days of age from mortality

rate of 26% with signs of reduction in feed consumption, depression, ruffled feathers, closed eyes, stunted growth, and profuse bloody diarrhea. These birds were fed a commercial diet, with 22% protein and 3060 kcal/kg metabolizable energy, without coccidiostatic or Aflatoxin binder additives.

Pathological examination:

Forty chicks from the two flocks were necropsed for pathological examination. These birds were scored for cecal lesions as devised by (32) as follows; Score 0: no gross lesions; Score 1: very few scattered petichiae on the caecal wall with normal caecal contents; Score 2: lesions are more numerous, blood in content, wall is somewhat thickened, normal caecal content; Score 3: large amounts of blood or caecal cores, caecal wall greatly thickened, little if any fecal content in ceca; Score 4: cecum is greatly distended, blood or caseous core, no fecal debris, dead birds; +4.

Ten of these dead chicks were subjected to caecal mucosal scraping for schizont determination. Oocyst size and shape were determined from about 50 predominant oocysts. A concentration McMaster technique has been used for calculation of average fecal oocyst excretion per gram (33).

Feed sampling:

Twenty five feed samples (each 1 kg) were taken from the broiler farm feed store, five samples of corn, barley, wheat, soybean and mixed feed according to (34).

Aflatoxin assay:

The levels of aflatoxin contamination of feed samples were determined by the method of direct competitive enzyme-linked immunoassay using Neogen extraction kit (Neogen Corporation). Results of the yield optical densities of the controls and samples were obtained by using computerized Neogen Verotex Software program version 2.0.16 (Neogen Corporation).

Results

The most prominent lesions seen in 80 necropsid birds in both flocks were summarized in (Table 1), in which pathological changes were mainly seen in the liver and two caecai. Those in the liver were characterized by creasy, yellow, ocher discoloration, with scattered areas of sub capsular hemorrhage. The caecal lesions were characterized by accumulation with varying quantities of blood and caseous necrotic materials (Figure 1). From table 1, it is evident that 5% of necropsed broilers in both flocks show (+) intensity of liver discoloration. More liver discoloration intensity (++) were recognized in both flocks with 22.5% in flock No.1, and 24% in flock No.2. Similar percentage of liver discoloration changes intensity (+++) were noticed in

both flocks. Higher percentage (37.5%) of liver intensity (++++) was recorded in flock No. 1, than that of 35% in flock No. 2. The intensity of sub capsular hemorrhage in livers of necropsed broiler chicks in both flocks, showed that only 2.5% of the necropsed birds in flock No. 1 with sub capsular hemorrhage of (+) was recorded, in comparison of 10% in flock No. 2. More sub capsular hemorrhage intensity (++) was noticed in flock No. 1 (27.5%), compared with 25% in flock No. 2. Still more intensity of (+++) in flock No. 1 of 35% was recorded, compared with 30% in the other flock. The same picture was continued with the highest sub capsular hemorrhage intensity of (++++) was also recorded in flock No. 1 with 37.5%, while it was 35% in flock No. 2.

Table 1: Number of necropsed birds, their percentages and intensity of pathological changes seen in livers of two broiler flocks.

Liver lesions	Broiler flocks					
	Flock No. 1			Flock No. 2		
	No. of necropsed birds	%	Intensity	No. of necropsed birds	%	Intensity
Discoloration (Yellow ochre)	2/40	5	+	2/40	5	+
	9/40	22.5	++	10/40	5	+
	14/40	35	+++	14/40	35	+++
	15/40	37.5	++++	14/40	35	++++
Sub capsular hemorrhage	1/40	2.5	+	4/40	10	+
	11/40	27.5	++	10/40	25	++
	13/40	35	+++	12/40	30	+++
	15/40	37.5	++++	14/40	35	++++

Individual and mean caecal lesion scores (Mean lesion score, MLS) (MLS = Sum of scores/number of birds) are presented in Table 2. From table it is clear that the total mean score lesions in the first flock was 3.5, i.e., higher than that MLS in the flock N0. 2 (3.05). The distributional percentages of MLS in both broiler flocks are illustrated in Figure 2. From this table it is clear that score 4 represents 73% in flock No.1, compared with 52% in flock N0.2. Score 3 in flock No. 2 was about double that in flock

N0.1 was about, they were 28 and 16% respectively. Two percent of score 2 was recorded in both broiler flocks. Relatively similar percentage for both broiler flocks 1 and 2, and they were 10 and 8% respectively. No score lesion of (0) was reported in flock No. 1, while the score was higher ten times in flock No.2.

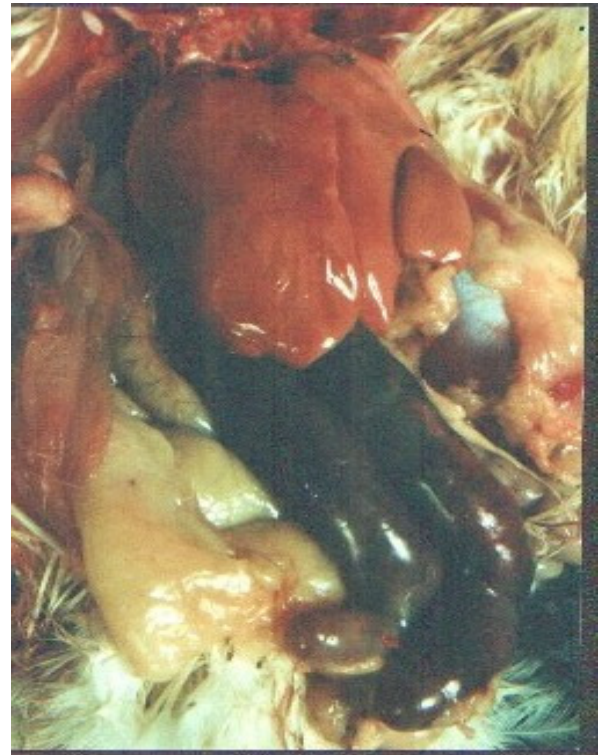

Figure 1: Necropsy liver and caecal lesions of broiler 35 days of age, showing creasy, yellow-ochre discolored liver, with ballooned two caeci, filled with free blood.

Parasitological findings of both flocks are summarized in Table 3. The MLS in both flocks was 3.26, with fecal oocyst excretion per gram X1000 = 636. The morphological features of examined caecal oocysts were identical for *Eimeria tenella*.

Aflatoxin assay of feed commodities taken from both broiler flocks are presented in Table 4. Of these commodities corn samples were heavily contaminated with AF. The range of contamination was between 831-3485 ppb, with average concentration of 1915ppb. Soybean samples were also reported to be contaminated with AF but at a lower rate than that of corn. Similar rate of contamination was noted, with range occurred between 220-238ppb, and an average of 229 ppb. No AF contamination was detected in both wheat and barley commodities. Mixed feed was consequently contaminated from the contaminated ingredients made from them, corn

and soybean. They were contaminated in a rate of 720-1006 ppb, with an average of 860 ppb.

Table 2: Individual and mean total caecal score lesion of broiler chicks in both flocks.

Broiler flocks		
Caecal score lesion	No. of birds in flock No. 1	No. of birds in flock No. 2
0		4
1	4	3
2	1	1
3	6	10
4	29	22
Mean lesion score (MLS)	140/40 = 3.5	122/40 = 3.05

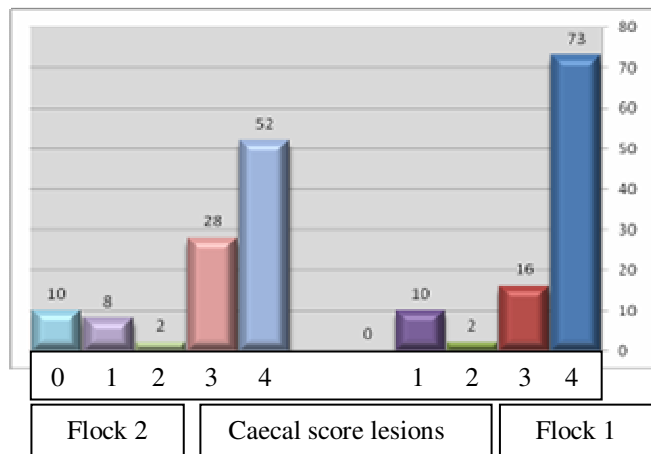


Figure 2: Percentages of caecal score lesions in both broiler flocks.

Table 3: Summary of the parasitological examination of necropsied birds (Average findings of broilers in both broiler flocks).

Parameters	Results
Mortality	26%
Fecal oocyst excretion per gram X1000	636
Oocyst size width X length (µm)	26 X 23
Morphological characteristic of eggs	Broadly ovoid
Mean lesion score for 80 dead birds	262/80 = 3.27
Schizonts maximum in µm	55.0

Table 4: Aflatoxin contamination of feed commodities (ppb) in of both broiler flocks.

Sample No.	Feed commodities				
	Corn	Soybean	Wheat	Barley	Mixed feed
	Concentrations of AF ppb				
1	3485	238	ND ✪	ND	1006
2	3485	233	ND	ND	931
3	931	228	ND	ND	831
4	831	224	ND	ND	753
5	866	220	ND	ND	720
Mean	1915	229	ND	ND	860

✪ND= not detected

Discussion

Aflatoxin was reported to increase susceptibility to coccidiosis under experimentally prior exposure poultry to Aflatoxin (25-30,35). To our knowledge, no report is reported here in Mosul province referring to a natural concurrent secondary caecal coccidiosis due to contamination of broiler feed commodities with Aflatoxin.

In this study, although anticoccidial agent was not included in the diet of broiler flocks as prophylactic measure, but the presence of high natural Aflatoxin contamination levels (860 ppb) of the mixed feed used in the feeding of these flocks, could largely impose a great stress on the birds immune system against coccidial infection.. This relation is supported by (22), who stated that 380 ppb AF or more is responsible for a significant reduction in cell mediated immunity (CMI). This effect on CMI include (a) macrophages, (b) natural killer (NK) cell lymphocytes and (c) two types of T-derived lymphocyte population (CD4+and CD8+) (35,36). Aflatoxin causes a substantial diminution in phagocytic activity by macrophages (37). Macrophages, CD4+ and NK cell lymphocytes dominate the CMI reaction upon primary contact/infection of coccidiosis, while CD8+ cells multiply particularly upon second contact (reinfection) of coccidiosis (38). CD4+ and CD8+ cells are cytotoxic and cytolytic, this means they can kill and lyses parasitic stages during coccidiosis cycle (39). However, it was reported that specific serum antibodies might also play a part in protecting chickens against coccidiosis (40) Antibodies, especially local immunoglobulin A (IgA) in the intestinal lumen can bind and damage sporozoites, causing loss in the ability of extra cellular differentiation and thereby preventing parasite invasion and intracellular development (41). So, antibodies, although play a minor role as a protective component against coccidiosis compared with the role of cell mediated immunity, but it is still negatively

affected by Aflatoxin, since their production was reported to be decreased by exposing birds to high toxin levels from 300 to 6000 ppb (42). The other possible roles of AF in predisposing broilers here to coccidial infection is the toxin reduction effect of vitamin A level in chicken liver and serum (43). Here, although vitamin A level was not measured in liver or serum, but it is highly possible that vitamin A deficiency is likely to occur due to feeding highly AF contaminated diet. Since, it is well known that disease resistance is a function of cell differentiation, and one of the primary function of vitamin A is to maintain proper epithelial tissue differentiation and prevent epithelial keratinization which occurs in vitamin A deficiency and it is important for enhancing both cellular and humoral immunity and enhance phagocytosis activity, and for maintaining cellularity of lymphoid organs (44,45). The possible reduction of vitamin A may be related to the high mortality rate reported here, since vitamin A has been reported to reduce mortality in chicks infected with coccidial oocyst from *E- tenella* and *E- acervulina* (46). The high coccidial pathogenicity noticed in our study, expressed by high lesion score of 3.27, could be related, to high AF diet contamination (15), and the high fecal oocyst excretion per gram (636000) oocyst/gram could also be attributed to this contamination. This effect was supported by (2,28), who confirmed that Aflatoxicosis was responsible for increased oocyst production and reproduction potential during coccidiosis. It is evident from the parasitic parameters examined in this study, that lesion score was found to be directly proportional to the mortality and oocyst count per gram of faeces/ dropping. Any way, it should be stressed that other mycotoxins like ochratoxin, T-2 toxin, and fumonisins may be present or contaminate feed commodities or mixed feed samples in our study, but the estimation was tried only with the most effective immunosuppressant mycotoxins, Aflatoxin. Moreover, no attempt was carried out to isolate immunosuppressive viruses like reo virus and Merk disease virus to elucidate their possible role if they were present in exacerbating caecal coccidiosis beside aflatoxin on broiler chickens.

From all above, and under field conditions, it seems that mycotoxins and here AF are highly stressful, when fed for extended period of time to birds on their immune system, which may be weakened to the point where it cannot control the organism and set the stage for the development of coccidiosis. So to prevent Aflatoxicosis and coccidiosis in poultry, sorbents like sodium bentonite and hydrated sodium calcium aluminosilicates should be added to their diet in order to decrease Aflatoxin severity (47), and by using coccidiostats/coccidiocidal drugs, or by Applying an alternative system of vaccination against coccidiosis..

Acknowledgement

The author thanks the College of Veterinary Medicine, Mosul, Iraq, for providing all supports for this study.

References

1. Cole RJ. Etiology of turkey X disease in retrospect. A case for the involvement of cyclopiazonic acid. *Mycotoxin Res.*1986;2:3-7.
2. Rao AG, Dehuri RK, Chand SK, Mishra SC, Mishra PK, Das BC. Aflatoxicosis in broiler chickens. *Indian J Poult Sci.* 1985;20:240-244.
3. Smith JW, Hamilton PB. Aflatoxicosis in the broiler chicken. *Poult Sci.* 1970;49:207-215.
4. AL-Sadi HI, Shareef AM, AL-Attar MY. Outbreaks of aflatoxicosis in broilers. *Iraqi J Vet Sci.* 2002;13:93-106.
5. Saunders WB. Pesticide Program Residue Monitoring, 1997. Washington DC: FDA;1998. 89 p.
6. Agricultural Marketing Service. Pesticide Data Program—Annual Summary, Calendar Year 1997. Washington DC: USDA, 1997.
7. Henry SH., Bosch FX, Bowers JW. Aflatoxin, hepatitis and worldwide liver cancer risks. *Adv Exp Med Biol.* 2002;504:229–233.
8. Neldon-Ortiz DL. Direct and microsome activated aflatoxin B1 exposure and its effects on turkey peritoneal macrophage functions in vitro. *Toxicol Appl Pharmacol.* 1991;109:432-42.
9. Moon EY. Inhibition of various functions in murine peritoneal macrophages by aflatoxin B1 exposure in vivo. *Int J Immunopharmacol.* 1999;21:47-58.
10. Cusumano V, Rossano F, Merendino RA. Immunobiological activities of mould products: functional impairment of human monocytes exposed to aflatoxin B sub(1). *Res Microbiol.* 1996;147:385-91.
11. Liu BH, Yu FY, Chan MH, Yang YL. The effects of mycotoxins, fumonisin B1 and aflatoxin B1, on primary swine alveolar macrophages. *Toxicol Appl Pharmacol.* 2002;180,197–204.
12. Boonchuvit B, Hamilton PB, Burmeister HR. Interaction of T-2 toxin with salmonella infection of chickens. *Poult Sci.* 1975;45:1693-1969.
13. Hamilton PB. Anatural and extremely sever Aflatoxicosis in laying hens. *Poult Sci.* 1971;50:1880-1882.
14. Richard JL, Pier AC, Cysewsk SJ, Granan CK. Effect of AF and aspergillosis on turkey poults. *Avian Dis.* 1973;17:111-121.
15. AL-Sbawi DMT. Ameliorative effect of mycofix plus.3.0 in reducing intensity of *Emeria tenella* infection during Aflatoxicosis in broiler chicks (masters thesis) Mosul University; Iraq; 2005.71p.
16. Williams RB. Epidemiological aspects of the use of live anticoccidial vaccines for chickens. *Int J Parasitol.* 1998;28:1089-1098.
17. Levine ND. Taxonomy and life cycles of coccidian, In: (edited by Long, P. L.) *The Biology of the Coccidia*, Univeristy Park Press, Baltimore;1982. p.1-33.
18. Witlock DR, Lushbaugh WB, Danforth HD, Ruff M D. Scanning electron microscopy of the cecal mucosa in *Eimeria-tenella*-infected and uninfected chickens. *Avian Dis.* 1975;19:293-304..
19. Lillehoj HS. Role of T lymphocytes and cytokines in coccidiosis. *Int J Parasitol.* 1998;28:1071-1081.
20. Lillehoj HS, Choi KD, Jenkins MC, Vakharia VN, Song KD, Han JY, Lillehoj EP. A recombinant *Eimeria* protein inducing interferon-gamma production: comparison of different gene expression systems and immunization strategies for vaccination against coccidiosis. *Avian Dis.* 2000;44:379-389.
21. Lillehoj HS, Min W, Dalloul RA. Recent progress on the cytokine regulation of intestinal immune responses to *Eimeria*. *Poult Sci.* 2004;83:611-623.
22. Williams RB. Intercurrent coccidiosis and necrotic enteritis of chickens: rational, integrated disease management by maintenance of gut integrity. *Avian Pathology.* 2007;34:159-180.

23. Williams RB. Efficacy and Epidemiological Aspects of paracox, a new coccidiosis vaccine for chickens. Harefield. UK. Pitman-Morre Europe;1992. 72 p.
24. Ruff MD. Reasons for inadequate nutrient utilization during avian coccidiosis, a review. In McDougald LR, Joyner LP, Long PL.(Eds). Research in avian coccidiosis. Athens, University of Georgia;1986:p. 169-185.
25. Wyatt RD, Ruff MD, Page RK. Interaction of aflatoxin with *Eimeria tenella* infection and monensin in young broiler chickens. Avian Dis. 1975;19 :730-740.
26. Edds GT, Simson CF. Cecal coccidiosis in poultry as affected by prior exposure to aflatoxin B1. Am J Vet Res. 1976;37:65-68.
27. Rao JR, Sharma NN, Iyer PK, Sharma AK. Interaction between *Eimeria uzura* infection and aflatoxicosis in Japanese quail (*Coturnix coturnix japonica*). Vet Parasitol. 1990;35:259-267.
28. Awadalla SF. Influence of dietary aflatoxin on the severity of coccidial infection in quails. Egypt Soc Parasitol. 1999;28:437-447.
29. Ruff MD, Fagan JM, Dick JW. Pathogenicity of coccidian in Japanese quail(*Coturnix coturnix japonica*). Poult Sci. 1984;63:55-60.
30. Ruff MD. Influence of dietary aflatoxin on the severity of *Eimeria acervulina* infection in broiler chickens. Avian Dis. 1978;22:471-480.
31. AL-Taeef AFM. Incidence of broiler cecal coccidiosis in Ninevah governorate 1999-2004. Iraqi J Vet Sci. 2007;21:45-65.
32. Johnson J, Ried WM. Anticoccidial drugs:Lesion scoring techniques in battery and floor-pen experiments with chickens. Exp Parasitol. 1970;28:30-36.
33. Foreyt WJ. Veterinary parasitology. Reference manual.5th ed. Iowa State University Press. USA.2001.307p.
34. Smith JE, Moss MO. control of mycotoxins. Ltd, London, John Wiley and Sons;1985. 142 P.
35. Witlock DR, Wyatt RD, Anderson WI. Relationship between *Eimeria adenoids* infection and Aflatoxicosis in turkey poults. Poult Sci. 1982;61:1293-1297
36. Ghosh RC, Chauhan HVS, Jha GJ. Suppression of cell-mediated immunity by purified aflatoxin B1 in broiler chicks. Vet immunol immunopathol. 1991;28:165-172.
37. Lillehoj HS, Min W, Dalloul RA. Recent progress on the cytokine regulation of intestinal immune responses to *Eimeria*. Poult Sci. 2004;83:611-623.
38. Qurshi MA, Brake J, Hamilton PB, Hagler JR WM, Nesheim S. Dietary exposure of broiler breeders to aflatoxin results in immune dysfunction in progeny chicks. Poult Sci 1998;77:812-819
39. Breed DGJ, Dorrestein, Vermeulen AN. Immunity to *Eimeria tenella* in chickens: Phenotypical and functional changes in peripheral blood T cells subsets. Avian Dis. 1996;40:37-48.
40. Davison TF, Morris TR, Payne LN. Poultry immunology. Poultry science symposium series vol.24. Journals oxford ltd;1996. 300 p.
41. Bakshi CS, Sikdar A, Johri TS, Malik M. Effect of graded dietary levels of AF on cell mediated immune response in broilers. Indian J Comp Microbiol, Immunol and Inf Dis. 1998;19:40-42
42. Yun CH, Lillehoj HS, Lillehoj EP. Intestinal immune responses to coccidiosis. Dev Com Immunol, 2000;24:303-424.
43. Pimpukdee K, Kubena LF, Bailey CA, Huebner HJ, Afriyie-Gyawu E, Phillips TD. Aflatoxin-induced toxicity and depletion of hepatic vitamin a in young broiler chicks:protection of chicks in the presence of low levels of novasil plus in the diet. Poult sci. 2004;83:737-744.
44. Davis CY, Sell JL. Effect of all-trans retinol and retinoic acid nutrition on the immune system in chicks. J Nutr. 1983;113:1914-1919.
45. Latshaw DJ. Nutrition-mechanisms of immunosuppression. Vet Immunol Immunopathol. 1991;30:111-120
46. Erasmus J, Scott ML, Levine PP. A relationship between coccidiosis and vitamin A nutrition of chickens. Poult Sci. 1960;39:565-572.
47. Shareef AM. The effect of two commercial bentonites in improving broiler performance during Aflatoxicosis. Iraqi J Vet Sci. 2004;18: 101-109.